




**21<sup>st</sup> RESEARCH  
DAYS**



Postgraduate Program  
in Ophthalmology &  
Visual Sciences

DECEMBER  
12 - 13, 2019

[oftalmounifesp.com.br/pg](http://oftalmounifesp.com.br/pg)

Organization



Sponsor





The meeting **Research Days | UNIFESP-EPM** is held annually since 1999 and aims to stimulate and improve scientific production at the **Department of Ophthalmology & Visual Sciences | Paulista School of Medicine | Federal University of Sao Paulo - UNIFESP**. **Research Days** includes presentation of papers, fast papers and posters by residents, fellows and postgraduate students enrolled in the Postgraduate Studies Program in Ophthalmology and Visual Sciences. Papers and posters are presented in English and active discussion with the faculty is prioritized. The scientific studies at each educational level (resident, fellow, and postgraduate student) are judged and the best in each category receive an award.

An active participation of the faculty as discussants and the participation of well-known investigators in the scientific program are encouraged. Registration is free and open to Postgraduate programs in Brazil and Latin America. We consider the presentations of our team of students at the **Research Days** as a first step to preparing them to participate in and interact with colleagues at international meetings.

The **21<sup>st</sup> Research Days | UNIFESP-EPM** will be held in São Paulo from December 12 to 13, 2019. Please visit our homepage <http://www.ofthalmounifesp.com.br/pg> for the complete Scientific Program and additional information.

**FINANCIAL SUPPORT:**

PAEP Capes Processo Nº 88881.359197/2019-01

PROEX CAPES Processo Nº 23038.007125/2018-76

**PROGRAM AT A GLANCE**

**December 12, 2019 - Thursday**

8:10-8:20 AM	OPENING REMARKS	Mauro Campos
8:20-8:30 AM	POSTGRADUATE PROGRAM	Augusto Paranhos Junior
8:30-8:35 AM	TRIBUTE	Norma Allemann
8:40-9:40 AM	PAPER PRESENTATION - SESSION 1	<b>GLAUCOMA</b> Moderators: Augusto Paranhos Jr., Ivan Maynard Tavares, Tiago dos Santos Prata
9:35-10:00 AM	INVITED LECTURE	Marcelo Nicolela, MD, PhD
10:00-10:10 AM	Discussion and Interview	
10:10-10:30 AM	COFFEE BREAK	
10:30-11:25 AM	PAPER PRESENTATION - SESSION 2	<b>UVEITIS AND ONCOLOGY</b> Moderators: Cristina Muccioli, Rubens Belfort Jr
11:30-11:55 AM	INVITED LECTURE	Marcelo Nicolela, MD, PhD
11:55-12:00 PM	Discussion and Interview	
12:00-1:00 PM	LUNCH BREAK	
1:00-1:25 AM	INVITED LECTURE	Marcelo Nicolela, MD, PhD
1:25-1:30 PM	Discussion and Interview	
1:30-2:35 PM	PAPER PRESENTATION - SESSION 3	<b>RETINA AND VITREOUS, PHARMACOLOGY</b> Moderators: Maurício Maia, Juliana Sallum
2:35-3:05 PM	INVITED LECTURE	Patricia Grenzi, PhD
3:05-3:15 PM	Discussion and Interview	
3:20-3:40 PM	COFFEE BREAK & POSTERS	
3:40-4:20 PM	POSTER SESSION 1	Glaucoma (5), Retina and Vitreous (18)
4:20-5:00 PM	PAPER PRESENTATION - SESSION 4	<b>RETINA AND VITREOUS, PHARMACOLOGY</b> Moderators: Michel Eid Farah, Caio Regatieri
5:00-5:30 PM	INVITED LECTURE	Christine Probst, PhD
5:30-5:40 PM	Discussion and Interview	
5:40 PM	END OF SESSION	



Program at a Glance

December 13, 2019 - Friday

8:10 – 9:00 AM	PAPER PRESENTATION - SESSION 5	<b>CORNEA AND EXTERNAL DISEASES</b> Moderators: Lauro Augusto de Oliveira, Denise de Freitas, Luciene Barbosa de Sousa
9:00 – 10:20 AM	PAPER PRESENTATION - SESSION 6	<b>CORNEA AND EXTERNAL DISEASES</b> Moderators: Ana Luisa Hofling-Lima, José Álvaro Pereira Gomes
10:20-10:50 AM	COFFEE BREAK	
10:50-11:30 AM	PAPER PRESENTATION - SESSION 7	<b>REFRACTIVE SURGERY, CATARACT, BIOENGINEERING, LACRIMAL SYSTEM, OCULOPLASTICS SURGERY</b> Moderators: Paulo Schor, Wallace Chamon, Walton Nosé, Mauro Campos, Renato Ambrósio Jr.
12:00-12:30 PM	INVITED LECTURE	<b>Helena Nader, PhD</b>
12:30-1:50 PM	LUNCH BREAK	
1:50-2:20 PM	INVITED LECTURE	<b>Christine Probst, PhD</b>
2:20- 2:30 PM	Discussion and Interview	
2:40-3:30 PM	PAPER PRESENTATION - SESSION 8	<b>EPIDEMIOLOGY, ELECTROPHYSIOLOGY, ULTRASOUND</b> Moderators: Solange Rios Salomão, Adriana Berezovsky, Norma Allemann
3:30-4:00 PM	COFFEE BREAK	
4:00-5:00 PM	POSTER SESSION 2	<b>Cornea and External Diseases (10), Cataract (3), Epidemiology(1), Lacrimal System (1), Oculoplastics Surgery (1), Orbit (2), Neuro-ophthalmology (1)</b>
5:10 – 5:30 PM	<b>FINAL REMARKS AND AWARDS ANNOUNCEMENT</b> Augusto Paranhos Jr, Mauricio Maia, Luiz Alberto Soares	
5:35 PM	<b>ADJOURN</b> Organizing Committee	

# INDEX

<b>Organization</b>	<b>01</b>
---------------------	-----------

<b>Special Guests</b>	<b>01</b>
-----------------------	-----------

<b>Scientific Program</b>	<b>02</b>
---------------------------	-----------

<b>Paper Presentation</b>	<b>Page</b>	<b>Poster</b>	<b>Page</b>
Glaucoma (Session 1)	2	Glaucoma (Session 1)	6
Uveitis (Session 2)	2	Retina and Vitreous (Session 1)	6
Oncology (Session 2)	2	Uveitis (Session 1)	6
Retina and Vitreous (Sessions 3 and 4)	3	Cornea and External Diseases (Session 2)	7
Pharmacology (Session 3 and 4)	3	Cataract (Session 2)	7
Cornea and External Diseases (Session 5 and 6)	4	Refraction-Contact Lenses (Session 2)	7
Refractive Surgery (Session 7)	4	Trauma (Session 2)	7
Cataract (Session 7)	4	Tumors and Pathology(Session 2)	7
Bioengineering (Session 7)	4	Epidemiology (Session 2)	7
Lacrimal System (Session 7)	4	Lacrimal System (Session 2)	7
Oculoplastics Sugery (Session 7)	5	Oculoplastics Sugery (Session 2)	7
Epidemiology (Session 8)	5	Orbit (Session 2)	7
Electrophysiology (Session 8)	5	Neuro-ophthalmology (Session 2)	7
Ultrasound (Session 8 )	5		7

<b>Abstracts</b>	<b>08</b>
------------------	-----------

<b>Paper Presentation</b>	<b>Page</b>	<b>Poster</b>	<b>Page</b>
Glaucoma (Session 1)	8	Glaucoma (Session 1)	61
Uveitis (Session 2)	14	Retina and Vitreous (Session 1)	65
Oncology (Session 2)	17	Uveitis (Session 1)	84
Retina and Vitreous (Sessions 3 and 4)	21	Cornea and External Diseases (Session 2)	85
Pharmacology (Session 3 and 4)	29	Cataract (Session 2)	95
Cornea and External Diseases (Session 5 and 6)	34	Refraction-Contact Lenses (Session 2)	98
Bioengineering (Session 7)	49	Trauma (Session 2)	99
Cataract (Session 7)	52	Tumors and Pathology(Session 2)	101
Refractive Surgery (Session 7)	53	Epidemiology (Session 2)	104
Lacrimal System (Session 7)	54	Lacrimal System (Session 2)	105
Oculoplastics Sugery (Session 7)	55	Oculoplastics Sugery (Session 2)	106
Epidemiology (Session 8)	56	Orbit (Session2)	107
Electrophysiology (Session 8)	57	Neuro-ophthalmology (Session 2)	109
Ultrasound (Session 8 )	59		

<b>e-mails</b>	<b>110</b>
----------------	------------

**Information**  
**Department of Ophthalmology and Visual Science**  
**Federal University of São Paulo - Paulista School of Medicine - São Paulo Hospital**  
**781 Pedro de Toledo Street, 2<sup>st</sup> floor – São Paulo, SP, Brazil**  
**Phone: (+55-11) 5576-4981**  
**e-mail: [pgsecretaria@oftalmo.epm.br](mailto:pgsecretaria@oftalmo.epm.br)**

## ORGANIZATION

### Postgraduate Program Coordination

---

Augusto Paranhos Junior  
Mauricio Maia

### Program Directors

---

Caio Vinicius Saito Regatieri

### Scientific Committee

---

Adriana Berezovsky  
Ana Luisa Hofling de Lima Farah  
Augusto Paranhos Jr.  
Caio Vinicius Saito Regatieri  
Cristina Muccioli  
Denise de Freitas  
Eduardo Büchelle Rodrigues  
Ivan Maynard Tavares  
José Álvaro Pereira Gomes  
Juliana Maria Ferraz Sallum  
Lauro Augusto de Oliveira  
Luciene Barbosa de Sousa  
Mauricio Maia  
Mauro Silveira de Queiroz Campos  
Michel Eid Farah  
Miguel Noel Nascentes Burnier  
Norma Allemann  
Paulo Schor  
Renato Ambrósio Junior  
Rubens Belfort Jr.  
Solange Rios Salomão  
Tiago dos Santos Prata  
Wallace Chamon  
Walton Nosé

### Oral Presentation Awards Committee

---

Luiz Alberto S. Melo Jr.  
Caio Vinicius Saito Regatieri  
Mauricio Maia  
Augusto Paranhos Jr.

### Poster Presentation Awards Committee

---

Carolina Pelegrini Barbosa Gracitelli  
Roberto Murad Vessani  
Sung Eun Song Watanabe

### Invited Speakers

---

Marcelo Nicoleta, MD, PhD  
Christine Probst, PhD  
Helena Nader, PhD  
Patricia Grenzi, PhD



**SCIENTIFIC PROGRAM**

**December 12, 2019 - Thursday**

<b>8:10-8:20 AM</b>	<b>OPENING REMARKS</b>	<b>Mauro Campos</b>	
<b>8:20-8:30 AM</b>	<b>POSTGRADUATE PROGRAM</b>	<b>Augusto Paranhos Junior</b>	
<b>8:30-8:35 AM</b>	<b>Tribute to Norma Allemann</b>		
<b>SESSION 1 PAPER PRESENTATION</b>			
<b>GLAUCOMA</b>			
<b>8:40-9:40 AM</b>	<b>Moderators: Augusto Paranhos Jr., Ivan Maynard Tavares, Tiago dos Santos Prata</b>		
8:40-8:47 AM	Comparing anterior segment optical coherence tomography with gonioscopy performed by glaucoma expert and general ophthalmologist in angle closure suspects	Bruno Leonardo B. Esporcatte	PG1 DO
8:50-8:57 AM	Subtenon triamcinolone acetonide as an adjunctive to mitomycin-c enhanced trabeculectomy in non-inflammatory glaucomas: a randomized clinical trial	Diego Torres Dias	PG1 DO
9:00-9:07 AM	Hazard Detection During Simulated Driving in Glaucoma Patients	Fabio Bernardi Daga	PG1 DO
9:10-9:17 AM	Naïfold capillaroscopy and laser doppler flowmetry analyses in glaucoma: comparison of vascular parameters between eyes with high and low-tension optic disc hemorrhage	Izabela Negrão Frota De Almeida	PG1 DO
9:20-9:27 AM	Chromatic vision and structural macular assessment in controlled primary congenital glaucoma children	Renata Tieme Kato Kunitake	PG1 ME
9:30-9:33 AM	Clinical experience with non-valved glaucoma drainage device implantation by surgeons-in-training: a five-year follow-up	Jenifer Shen Ay Wu	R3
<b>9:35-10:00 AM</b>	<b>INVITED LECTURE – Marcelo Nicolela, MD, PhD</b>		
<b>10:00-10:10 AM</b>	<b>Discussion and Interview</b>		
<b>10:10-10:30 AM</b>	<b>COFFEE BREAK</b>		
<b>SESSION 2 PAPER PRESENTATION</b>			
<b>UVEITIS AND ONCOLOGY</b>			
<b>10:30-11:25 AM</b>	<b>Moderators: Cristina Muccioli, Rubens Belfort Jr</b>		
10:30-10:37 AM	Quality-of-Life and Psychosocial Aspects in Patients with Ocular Toxoplasmosis: A Clinical Study	Aristófanés Mendonça Canamary Junior	PG1 DO
10:50-10:57 AM	A new strain of Toxoplasma gondii circulating in southern Brazil	Marisa Lucia Romani Paraboni	PG1 DO
11:00-11:03 AM	Physical and developmental findings in children born to ZIKV infected mothers during pregnancy: a cohort study of urban slum residents.	Bruno de Paula Freitas	PG1 DO
11:05-11:08 AM	Choroidal Melanoma: tumor profile and treatment outcome.	Jorge Henrique Cavalcante Tavares	FELLOW
11:10-11:13 AM	Frequency of eye metastases in patients with non-ocular metastatic neoplasia	Mariana Borges Barcellos Dias	FELLOW
11:15-11:18 AM	Ocular Manifestations in Patients with Phacomatosis	Aluisio Rosa Gameiro Filho	FELLOW
11:20-11:27 AM	Xeroderma pigmentosa in Brazil: single center experience recruiting patients visa social media	Alexya Affonso Antunes Marcos	PG1 DO
<b>11:30-11:55 AM</b>	<b>INVITED LECTURE – Marcelo Nicolela, MD, PhD</b>		
<b>11:55-12:00 PM</b>	<b>Discussion and Interview</b>		
<b>12:00-1:00 PM</b>	<b>LUNCH BREAK</b>		
<b>1:00-1:25 AM</b>	<b>INVITED LECTURE – Marcelo Nicolela, MD, PhD</b>		

<b>1:25-1:30 PM</b>	<b>Discussion and Interview</b>		
<b>SESSION 3</b>	<b>PAPER PRESENTATION</b>		
<b>1:30-2:35 PM</b>	<b>RETINA AND VITREOUS, PHARMACOLOGY</b> <b>Moderators: Maurício Maia, Juliana Sallum</b>		
1:30-1:37 PM	Retinal microvasculature parameters in patients with Obstructive Sleep Apnea Syndrome	Luis Filipe Nakayama	PG0 DO
1:40-1:47 PM	Objective Assessment of YAG Laser Vitreolysis in Patients with Symptomatic Vitreous Floaters	Carlos Eduardo de Souza	PG1 DO
1:50-1:57 PM	Hydrogel polymer biocompatibility in vitreoretinal surgery	Ramon Antunes de Oliveira	PG1 DO
2:00-2:03 PM	Combined Femtosecond Laser-Assisted Cataract Surgery and Small-Gauge Pars Plana Vitrectomy Using Different Devices: A New Trend for Vitreoretinal Surgery?	Bruno Queiroz Alves	FELLOW
2:05-2:08 PM	Safety and Retinal Toxicity of a Biodegradable Scaffold for Stem Cells Derived RPE Implantation: Preclinical Study in Rabbits	Mariana Kawamuro	FELLOW
2:10-2:13 PM	Visual outcome of early Vitrectomy in intravitreal anti-VEGF related endophthalmitis	Vinicius Campos Bergamo	PG1 DO
2:15-2:18 PM	Effect of syringe flickage in intravitreal injection of Aflibercept: A randomized double blind clinical trial	Natasha Ferreira Santos da Cruz	PG0 DO
2:20-2:23 PM	Inherited retinal dystrophies associated with syndromes	Mariana Matioli da Palma	PG1 DO
<b>2:35-3:05 PM</b>	<b>INVITED LECTURE – Patricia Grenzi, PhD</b>		
<b>3:05-3:15 PM</b>	<b>Discussion and Interview</b>		
<b>3:20-3:40 PM</b>	<b>COFFEE BREAK &amp; POSTERS</b>		
<b>3:40-4:20 PM</b>	<b>POSTER SESSION 1</b> Glaucoma (5), Retina and Vitreous (19), Uveites (1)		
<b>SESSION 4</b>	<b>PAPER PRESENTATION</b>		
<b>4:20-5:00 PM</b>	<b>RETINA AND VITREOUS, PHARMACOLOGY</b> <b>Moderators: Michel Eid Farah, Caio Regatieri</b>		
4:20-4:27 PM	Prospection of new anti-angiogenic drugs based on chemically modified heparins	Vinicius Ferreira Kniggendorf	PG1 DO
4:30-4:37 PM	Mishandling of syringes and the risks to the eye	Gustavo Barreto de Melo	POST DOC
4:40-4:43 PM	The isolated and combined influence of weight-adjusted coffee and propranolol intake on retinal fellows simulated surgical skills	Marina Roizenblatt	PG1 DO
4:45-4:48 PM	Imaging Analysis of Macular Holes in Optical Coherence Tomography Angiography: Conventional Peeling Versus Inverted Internal Limiting Membrane Flap Technique	Oswaldo Moura Brasil	PG1 DO
4:50-4:53 PM	Clinical Study on the Initial Experiences of French Vitreoretinal Surgeons with Heads-up Surgery	Renato Menezes Palácio	PG1 DO
<b>5:00-5:30 PM</b>	<b>INVITED LECTURE – Christine Probst, PhD</b>		
<b>5:30-5:40 PM</b>	<b>Discussion and Interview</b>		
<b>5:40 PM</b>	<b>END OF SESSION</b>		



SCIENTIFIC PROGRAM

December 13, 2019 – Friday

**SESSION 5 PAPER PRESENTATION**

**8:10 – 9:00 AM CORNEA AND EXTERNAL DISEASES**

**Moderators: Lauro Augusto de Oliveira, Denise de Freitas, Luciene Barbosa de Sousa**

8:10-8:17 AM	Ocular surface changes in the treatment of Rosacea: comparison between low-dose oral isotretinoin and doxycycline	Fabio Mendonça Xavier Andrade	PG1 DO
8:20-8:27 AM	Macromolecular changes in the extracellular matrix of human corneas with keratoconus and after crosslinking with açai (Euterpe oleracea) extract: an ex vivo and in vitro study	Murilo Bertazzo Peres	PG0 DO
8:30-8:37 AM	Pharmacoeconomic study on the variables regarding the vials of eyedrops and the formation of drops: a search for standardization	Alexandre Xavier da Costa	PG1 DO
8:40-8:47 AM	New technique: corneal micro infusion of drugs with microneedles	Michelle de Lima Farah Santinello	PG1 DO
8:50-8:53 AM	Purpuriocillium keratitis: a challenging infection	Aline Couto Carneiro	PG0 DO
8:55-8:58 AM	Corneal Transplantation In Patients With Acanthamoeba Keratitis	Luciana Lopes Rocha	PG0 DO

**SESSION 6 PAPER PRESENTATION**

**9:00 – 10:20 AM CORNEA AND EXTERNAL DISEASES**

**Moderators: Ana Luisa Hofling-Lima, José Álvaro Pereira Gomes**

9:00-9:07 AM	An investigation of alternative rho-associated kinase (rock) inhibitors and a comparison of their effects on corneal endothelial wound recovery	Francisco Bandeira e Silva	PG1 DO
9:10-9:17 AM	Evaluation of keratoconus corneas: Histochemical, ultrastructural and molecular analysis	Joyce Luciana Covre	PG1 DO
9:20-9:27 AM	Scaled pachymetric gain of standard Cross-linking using hypotonic riboflavin in patients with keratoconus	Fabio Kenji Matsumoto	PG1 DO
9:30-9:37 AM	Efficacy and safety of riboflavin-ultraviolet type A rays inducing cross-linking of corneal collagen in patients aged 8 to 16 years with progressing keratoconus.	Julia Gomes F. Polido Cabral	PG1 DO
9:40-9:47 AM	Reverse SMILE With An Excimer Laser Treated Biomaterial: A Novel Approach to Corneal Reshaping Using an Intracorneal Implant	Maria Carolina Marquazan	PG1 DO
9:50-9:57 AM	Comparison of intraocular pressure measurements after corneal ring intrastromal segment implantation with Goldmann applanation tonometry and Corvis.	Pablo Felipe Rodrigues	PG1 DO
10:00-10:03 AM	Characterization of inflammatory mediators in the tear film, conjunctival epithelium and corneal epithelium in keratoconus patients.	Albert Wilson Santos Machado Silva	PG1 DO
10:05-10:10 AM	Fungal Keratitis Management in a Referral Cornea Center in Brazil.	Fernanda Machado Bezerra	PG1 DO
10:10-10:17 AM	Evaluation of rose Bengal mediated photodynamic therapy for in vitro inhibition of rapid growing mycobacteria	Talita Trevizani Rocchetti	POST DOC

**10:20-10:50 AM COFFEE BREAK**

**SESSION 7 PAPER PRESENTATION**

**10:50-11:30 AM REFRACTIVE SURGERY, CATARACT, BIOENGINEERING, LACRIMAL SYSTEM, OCULOPLASTICS SURGERY**

**Moderators: Paulo Schor, Wallace Chamon, Walton Nosé, Mauro Campos, Renato Ambrósio Jr.**

10:50-10:57 AM	Safety and efficacy analysis of a PAMAM-dendrimer-dextran conjugated polymer as a slow-release delivery device for an antiglaucomatous drug in an animal model	Augusto Alves Pinho Viera	PG0 DO
11:00-11:07 AM	The use of artificial intelligence to determine subjective refraction	Aline Lutz de Araújo	PG1 DO
11:10-11:17 AM	A deep learning algorithm for automated detection of chorioretinal diseases	Thiago Gonçalves S. Martins	PG1 DO
11:20-11:27 AM	Artificial intraocular lens support: A new device	Victor Dias Bergamasco	PG1 DO

11:30-11:37 AM	The role of corneal biomechanics for the evaluation of ectasia	Marcela Q. Salomão Hoyer de Carvalho	PG1 DO
11:40-11:47 AM	Effect of botulinum toxin injections on the tear film of patients with essential blepharospasm: preliminary results	Cristina Yabumoto	PG1 DO
11.50-11:57 AM	Histopathological analysis of orbicularis oculi muscle in hemifacial spasm patients	Midori Hentona Osaki	PG1 DO
12:00–12:30 PM	<b>INVITED LECTURE – Helena Nader, PhD</b>		
12:30-1:50 PM	<b>LUNCH BREAK</b>		
1:50-2:20 PM	<b>INVITED LECTURE – Christine Probst, PhD</b>		
2:20- 2:30 PM	<b>Discussion and Interview</b>		
<b>SESSION 8</b>	<b>PAPER PRESENTATION</b>		
<b>2:40-3:30 PM</b>	<b>EPIDEMIOLOGY, ELECTROPHYSIOLOGY, ULTRASOUND</b>		
	<b>Moderators: Solange Rios Salomão, Adriana Berezovsky, Norma Allemann</b>		
2:40-2:47 PM	Inter-session reliability and normal values of the electroretinogram photopic negative response (phnr) in healthy adults	Gabriel Izan Santos Botelho	PG1 DO
2:50-2:57 PM	Pattern-reversal visual evoked potentials in unilateral visual impairment and malingering	Tarciana de Souza Soares	PG1 DO
3:00-3:07 PM	Teleophthalmology Support for Primary Care Diagnosis, Management and Results. (CATARACT)	Elmar Torres Neto	PG1 DO
3:10-3:17 PM	Preterm infants Ocular Growth in a Neonatal Intensive Care Unit (ICU) environment	Ricardo Salles Cauduro	PG1 DO
3:20-3:27 PM	Ultrasonographic follow up of eyes with intravitreal dexamethasone implant (Ozurdex®)	Gabriela Assumpção Brito Pereira Pelegrini	PG1 DO
<b>3:30-4:00 PM</b>	<b>COFFEE BREAK</b>		
<b>4:00-5:00 PM</b>	<b>POSTER SESSION 2</b>		
	Cornea and External Diseases (10), Cataract (3), Refraction-Contact Lenses (1), Trauma (2), Tumors and Pathology (3), Epidemiology(1), Lacrimal System (1), Oculoplastics Surgery (1), Orbit (2), Neuro-ophthalmology (1)		
<b>5:10 – 5:30 PM</b>	<b>FINAL REMARKS AND AWARDS ANNOUNCEMENT</b>		
	<b>Augusto Paranhos Jr, Mauricio Maia, Luiz Alberto Soares,</b>		
<b>5:35 PM</b>	<b>ADJOURN</b>		
	<i>Organizing Committee</i>		

POSTERS

December 12, 2019 - Thursday

**3:40- 4:20 PM POSTER SESSION 1  
Glaucoma (5), Retina and Vitreous (19), Uveites (1)**

Influence of phacoemulsification on intraocular pressure in patients with trabeculectomy	Gabriel Ferrante Abou Murad	R2
Assessment of Relationship Between Number of Glaucoma Medications, Ocular Surface Disorder and Treatment Adherence	Gustavo Albrecht Samico	R1
Outpatient follow-up profile of patients with glaucoma in the Brazilian public and private health sector	Marcos Pereira Vianello	PG1 - ME
Different Interventions to Improve Reading Performance within Glaucoma Patients	Mariana Chiba Ikeda	R1
Efficacy of new anti-angiogenic drugs derived from heparinomimetics for neovascularization of choroid in animal model	Alex Treiger Grupenmacher	PG0 - DO
Frequency of ophthalmological posterior segment findings in patients with Polycythemia Vera	Ana Carolina Yumi Itikawa	R2
The use of optical coherence tomography for detection of retinal toxicity by ethambutol	Brunella Pavan Taffner	PG0 - DO
Effects of panretinal laser photocoagulation on the tear function and ocular surface using OCULUS Keratograph® 5M	Bruno Mauricio Rodrigues de Oliveira	Fellow
Assessment of Presence of Activity of Secondary Neovascular Membrane to Age-Related Macular Degeneration with OCT-A Examinations versus Traditional Retinography, Angiography, and SD-OCT Methods?	Daniela Calucci dos Santos	PG1 - ME
Choroidal thickness comparison of non-edematous and edematous macular areas in patients with diabetic macular edema using edi-oct.	Dante Akira Kondo Kuroiwa	R3
Analysis of scleral buckling surgeries for rhegmatogenous retinal detachment performed in a quaternary hospital	Diego Lisboa Araujo	R3
Optical Coherence Tomography (OCT) Angiography Use in Retinal Diseases	Felipe Ferreira Conti	PG1 - DO
Comparison of the use of analgesic drugs in panretinal photocoagulation on patients with diabetic retinopathy	Felipe Picanço Muralha	Fellow
Subretinal Fluid Application to Macular Hole Closure	Guilherme Eiich Takitani	Fellow
A case of Acute Macular Neurotinopathy: a case report	Julia Harumi Iwakura	R1
Randomized clinical trial to compare the healing process of idiopathic macular hole with different surgical techniques	Luiz Filipe Adami Lucatto	PG1 - DO
Posterior uveitis with retinal vasculitis secondary to Behçet disease: a case report.	Mariana Antunes Davi	R1
Intravitreal Dexamethasone Implant Migration into the Anterior Chamber	Mariana Batista Gonçalves	PG1 - DO
Changes in the optic disk and choroid related to haemodialysis using optical coherence tomography angiography.	Murilo Ubukata Polizelli	Fellow
Evaluation of macular perfusion through OCT-Angiography in patients with diabetic macular edema submitted to intravitreal therapy with biodegradable dexamethasone implant (Ozurdex®)	Nelson Chamma Capelanes	PG0 - DO
Pre and intraoperative ganglion cell layer features as a prognostic factor of idiopathic epiretinal membrane surgery	Nikoly Tigani Fares	Fellow
Evaluation of panretinal light coagulation effects in patients with diabetic retinopathy through multimodal fundus imaging	Paulo Alberto Cervi Rosa	R3
Short-term outcomes of Susanna and Baerveldt glaucoma drainage implants surgery performed by surgeons in training	Zaira Fernanda Martinho Nicolau	R2
Non- infectious intermediate, posterior or pan uveitis using Biologic Agents	Vivian Cristina Costa Afonso	PG0 - DO

POSTERS

December 13, 2019 - Friday

4:00-4:00 PM

POSTER - SESSION 2

Cornea and External Diseases (10), Cataract (3), Refraction-Contact Lenses (1), Trauma (2), Tumors and Pathology (3), Epidemiology(1), Lacrimal System (1), Oculoplastics Surgery (1), Orbit (2), Neuro-ophthalmology (1)

Ocular Surface Disease Index (OSDI) questionnaire survey in proliferative diabetic retinopathy subjects	Beatriz Nugent da Cunha	R2
Effect of povidone-iodine on Candida parapsilosis biofilm in gelatinous contact lens	Camila Maria Valente	Fellow
Case report: unusual evolution of a dermoid cyst after surgical excision.	Franklin Kuraoka Oda	R1
Optical coherence tomography angiography of conjunctival vessels in proliferative diabetic retinopathy subjects	José Aparecido Job Neto	R4
Infectious keratitis following corneal transplantation	José Arthur Pinto Milhomens	R2
Systemic cyclosporine for severe allergic keratoconjunctivitis	Raysa Victoria de Oliveira Cechim	R4
Vision-related quality of life in patients undergone Intrastromal Corneal Ring Segment implantation, adaptation to contact lens and corneal transplantation	Renata Macedo Nabuco Faro	R4
Intracorneal Ring Segment: Comparison between experts and software in surgical planning at an University Hospital.	Rodolfo Peres Nunes	Fellow
Corneal Transplantation in a referral cornea center in Brazil: epidemiology, surgical techniques and outcomes.	Vanessa Favero Demeda	R4
Evaluation of Rose Bengal Mediated Photodynamic Therapy for inhibition of bacterial and fungal keratitis isolates	Wirley Alves Mendonca Junior	Fellow
Comparative analysis on intraoperative complications in the 40th first phacoemulsification surgeries among second year residents with and without dry-lab experience	Allyne Mota Kalaf	R3
Comparison of ray-tracing, Hartmann-Shack, autorefractometry and manifest refraction in echelette's achromatic intraocular lens	Jorge Selem Haddad Neto	PG1 - DO
To evaluate the application of the red reflex test in newborns treated at the Congenital Cataract Outpatient Clinic of the Federal University of São Paulo	Victoria Sakamoto	R1
A Critical Analysis Regarding Scleral Contact Lenses Adaptation	Cristina Cagliari	PG0 - DO
Epidemiology of Evisceration and Enucleation cases in an ophthalmological emergency room sector of a tertiary brazilian hospital: a 7-year analysis	Camila Kase	R2
Epidemiological characteristics and visual outcome of patients hospitalized for Open-Globe injury in a Tertiary Hospital in Brazil	Lucas Denadai	R2
Topical 5-fluorouracil 0,25% as treatment of Ocular Surface Squamous Neoplasia	Ana Marisa Pires Castello Branco	Fellow
Title: Mantle Cell Lymphoma and acute low visual acuity	Armando Coelho Brito	R1
Meibomian gland Alterations due to Topical treatment of Ocular Surface Squamous Neoplasia	Camila Palmeira Griz	Fellow
Epidemiology of Ophthalmic Emergency Visits in a Brazilian Tertiary Hospital from 2009 to 2019	Lucas Zago Ribeiro	R2
Evaluation of the lacrimal puncta morphology in patients using topical antiglaucoma medications.	Marília Cirillo Rollo	R3
Evaluation of spontaneous blinking dynamics in healthy subjects with smartphone camera.	Irineu Kenji Ogoshi Junior	R3
Orbital metastasis as the initial presentation of pancreatic carcinoma: A case report.	Felipe Ostermann Magalhães	R1
Superior ophthalmic vein thrombosis - a case report	Júlia Jiquilin Carvalho	R1
Fourth cranial nerve palsy and internuclear ophthalmoplegia as an early presentation of multiple sclerosis: A case report	Guilherme Havir Bufarah	R1

## 2019 Research Days Abstract Form

### 2. SCIENTIFIC SECTION PREFERENCE (REQUIRED):

Review the Scientific Section Descriptions. Select and enter the two-letter Code for the one (1) Section best suited to review your abstract.

**(GL) GLAUCOMA**

### 3. PRESENTATION PREFERENCE (REQUIRED)

Check one:

**(GL) GLAUCOMA**

4. The signature of the First (Presenting) Author (REQUIRED) acting as the authorized agent for all authors, hereby certifies that any research reported was conducted in compliance with the Declaration of Helsinki and the "UNIFESP Ethical Committee"

### Scientific Section Descriptions (two-letter code):

(BE) OCULAR BIOENGINEERING  
(CO) CORNEA AND EXTERNAL DISEASE  
(CA) CATARACT  
(EF) ELECTROPHYSIOLOGY  
(EP) EPIDEMIOLOGY  
(EX) EXPERIMENTAL SURGERY  
(GL) GLAUCOMA  
(LA) LABORATORY  
(LS) LACRIMAL SYSTEM  
(LV) LOW VISION  
(NO) NEURO-OPHTHALMOLOGY  
(OR) ORBIT  
(PL) OCULAR PLASTIC SURGERY  
(PH) PHARMACOLOGY  
(RE) RETINA AND VITREOUS  
(RS) REFRACTIVE SURGERY  
(RX) REFRACTION-CONTACT LENSES  
(ST) STRABISMUS  
(TR) TRAUMA  
(TU) TUMORS AND PATHOLOGY  
(UV) UVEITIS  
(US) OCULAR ULTRASOUND

Deadline: 10/2019

### FORMAT:

#### Abstract should contain:

Title  
Author  
Co-authors (maximum 6)  
Purpose  
Methods  
Results  
Conclusion  
Keywords

Poster guidelines:  
**90cm x 120cm**

### FIRST (PRESENTING) AUTHOR (REQUIRED):

**Name:** Bruno Leonardo B. Esporcatte - PG1 - DO  
**e-mail:** bruno\_esporcatte@yahoo.com.br  
**CEP Number:** 1.685.944

### 5. ABSTRACT (REQUIRED):

**Title: Comparing anterior segment optical coherence tomography with gonioscopy performed by glaucoma expert and general ophthalmologist in angle closure suspects**

**Author and Co-authors:** Esporcatte, Bruno, Bufarah, Guilherme H., S Yamagimori, Norton, Melo Jr, Luiz Alberto, Allemann, Norma, Tavares, Ivan M.

**Purpose:** Assessment of angle configuration is an essential part of the diagnosis and management of individuals with angle closure. The reference standard for diagnostic angle status is visualization of angle structures by indirect gonioscopy. An anterior segment optical coherence tomography (AS-OCT) may provide reproducible images of the anterior chamber angle. The aim of this study is to compare the ability of AS-OCT to detect angle closure with gonioscopy performed by glaucoma experts (GE) and general ophthalmologist (GO)

**Methods:** Gonioscopy in dark conditions was performed by GE and GO in 44 patients with Van Herick anterior chamber depth grade (VH) I or II. Indentation gonioscopy was also performed. An angle quadrant was classified as closed on gonioscopy if posterior trabecular meshwork was not visible. Images of the same evaluated eye were obtained using both Visante (Carl Zeiss Meditec Inc., Dublin, CA, USA) and Triton AS- OCT (Topcon Inc, Tokyo, Japan). Angle scans obtained by both AS-OCT devices were evaluated for the presence of iridocorneal contact anterior to the scleral spur. Axial length (AXL) and anterior chamber depth (ACD) were obtained by optic biometry. The kappa ( $\kappa$ ) statistic was used to assess the agreement between categorical variables.

**Results:** Of the 44 patients included 84% were female. The mean age was  $65.84 \pm 9.25$  years. The anterior chamber was classified as VH I in 28 eyes (59%) and VH II in 18 eyes (41%). The mean AXL was  $22.40 \pm 0.89$  mm and ACD was  $2.56 \pm 0.29$  mm. The agreement between GE and GO for identification of closed angle quadrant was 77.27% ( $\kappa=0.43$ ), 70.45% ( $\kappa=0.27$ ), 59.09% ( $\kappa=0.20$ ) and 70.45% ( $\kappa=0.33$ ) in superior, nasal, inferior and temporal quadrants, respectively. Similar evaluation was performed in indentation gonioscopy, and the agreement was 65.91% ( $\kappa=0.23$ ), 54.55% ( $\kappa=0.02$ ), 72.73% ( $\kappa=0.16$ ) and 54.55% ( $\kappa=0.09$ ), respectively.

**Conclusion:** Gonioscopy is a subjective method that demands an extensive training to be correctly performed. There was a moderate agreement between angle status acquired by gonioscopy performed by GE and GO, and AS-OCT images in angle closure suspects.

**Keywords:** Glaucoma; anterior segment OCT

## 2019 Research Days Abstract Form

### 2. SCIENTIFIC SECTION PREFERENCE (REQUIRED):

Review the Scientific Section Descriptions. Select and enter the two-letter Code for the one (1) Section best suited to review your abstract.

**(GL) GLAUCOMA**

### 3. PRESENTATION PREFERENCE (REQUIRED)

Check one:

**(GL) GLAUCOMA**

4. The signature of the First (Presenting) Author (REQUIRED) acting as the authorized agent for all authors, hereby certifies that any research reported was conducted in compliance with the Declaration of Helsinki and the 'UNIFESP Ethical Committee'

### Scientific Section Descriptions (two-letter code):

(BE) OCULAR BIOENGINEERING  
(CO) CORNEA AND EXTERNAL DISEASE  
(CA) CATARACT  
(EF) ELECTROPHYSIOLOGY  
(EP) EPIDEMIOLOGY  
(EX) EXPERIMENTAL SURGERY  
(GL) GLAUCOMA  
(LA) LABORATORY  
(LS) LACRIMAL SYSTEM  
(LV) LOW VISION  
(NO) NEURO-OPHTHALMOLOGY  
(OR) ORBIT  
(PL) OCULAR PLASTIC SURGERY  
(PH) PHARMACOLOGY  
(RE) RETINA AND VITREOUS  
(RS) REFRACTIVE SURGERY  
(RX) REFRACTION-CONTACT LENSES  
(ST) STRABISMUS  
(TR) TRAUMA  
(TU) TUMORS AND PATHOLOGY  
(UV) UVEITIS  
(US) OCULAR ULTRASOUND

Deadline: 10/2019

### FORMAT:

#### Abstract should contain:

Title  
Author  
Co-authors (maximum 6)  
Purpose  
Methods  
Results  
Conclusion  
Keywords

Poster guidelines:  
**90cm x 120cm**

### FIRST (PRESENTING) AUTHOR (REQUIRED):

**Name:** Diego Torres Dias - PG1 - DO  
**e-mail:** diego.torres@outlook.com.br  
**CEP Number:** 49040670

### 5. ABSTRACT (REQUIRED):

**Title: SUBTENON TRIAMCINOLONE ACETONIDE AS AN ADJUNCTIVE TO MITOMYCIN-C ENHANCED TRABECULECTOMY IN NON-INFLAMMATORY GLAUCOMAS: A RANDOMIZED CLINICAL TRIAL**

**Author and Co-authors:** Diego T Dias, MD, Izabela Almeida, MD, Michele Ushida, MD, Flavio S Lopes, MD, Fábio N Kanadani, MD, PhD, Tiago S Prata, MD, PhD

**Purpose:** To compare the surgical outcomes of mitomycin C-enhanced trabeculectomy (MMC-TRAB) with and without subtenon triamcinolone acetonide (TAAC) injection in patients with non-inflammatory glaucomas.

**Methods:** We designed a unicentric randomized clinical trial. Consecutive patients with clinically uncontrolled non-inflammatory glaucomas were enrolled, and those meeting the inclusion criteria were randomized into two groups. All eyes were initially submitted to a standard MMC-TRAB. Eyes randomized to the adjuvant TAAC group received a subtenon TAAC injection (4mg) close to the bleb site at the end of the surgery. Post-operative visits were scheduled at 1, 3, 6, 12, 18 and 24 months. Main outcomes measures were success rates, intraocular pressure (IOP) and number of medications at all time points. Success was defined according to two different IOP criteria: criterion I=IOP $\geq$ 18mmHg, criterion II=IOP $\geq$ 15mmHg, and subdivided in complete or qualified success according to the need of medication.

**Results:** A total of 75 patients were included (study group=39 eyes, control group=36 eyes). There was no difference between groups at baseline regarding clinical and ocular characteristics ( $p>0.08$ ). Complete success rates were higher in the adjuvant TAAC group at 12 (Criterion 1: 89.7% vs 69.4%, Criterion 2: 87.2% vs 66.7%,  $p=0.03$ ) and 18 months (Criterion 1: 87.2% vs 66.7%, Criterion 2: 87.2% vs 66.7%,  $p=0.03$ ). Additionally, although success rates at 24 months were higher in the subtenon TAAC group (82.0% vs 66.7%,  $p=0.09$ ), this difference did not reach statistical significance. Qualified success rates, mean IOP, number of medications and percentage of eyes requiring medication did not significantly differ between groups at all time points.

**Conclusion:** Complete success rates until 18 months of follow-up were improved by the use of subtenon TAAC as an adjuvant to standard trabeculectomy with MMC in patients with non-inflammatory glaucomas.

**Keywords:** glaucoma; trabeculectomy; triamcinolone



## 2019 Research Days Abstract Form

### 2. SCIENTIFIC SECTION PREFERENCE (REQUIRED):

Review the Scientific Section Descriptions. Select and enter the two-letter Code for the one (1) Section best suited to review your abstract.

**(GL) GLAUCOMA**

### 3. PRESENTATION PREFERENCE (REQUIRED)

Check one:

**(GL) GLAUCOMA**

4. The signature of the First (Presenting) Author (REQUIRED) acting as the authorized agent for all authors, hereby certifies that any research reported was conducted in compliance with the Declaration of Helsinki and the "UNIFESP Ethical Committee"

### Scientific Section Descriptions (two-letter code):

(BE) OCULAR BIOENGINEERING  
(CO) CORNEA AND EXTERNAL DISEASE  
(CA) CATARACT  
(EF) ELECTROPHYSIOLOGY  
(EP) EPIDEMIOLOGY  
(EX) EXPERIMENTAL SURGERY  
(GL) GLAUCOMA  
(LA) LABORATORY  
(LS) LACRIMAL SYSTEM  
(LV) LOW VISION  
(NO) NEURO-OPHTHALMOLOGY  
(OR) ORBIT  
(PL) OCULAR PLASTIC SURGERY  
(PH) PHARMACOLOGY  
(RE) RETINA AND VITREOUS  
(RS) REFRACTIVE SURGERY  
(RX) REFRACTION-CONTACT LENSES  
(ST) STRABISMUS  
(TR) TRAUMA  
(TU) TUMORS AND PATHOLOGY  
(UV) UVEITIS  
(US) OCULAR ULTRASOUND

Deadline: 10/2019

### FORMAT:

#### Abstract should contain:

Title  
Author  
Co-authors (maximum 6)  
Purpose  
Methods  
Results  
Conclusion  
Keywords

Poster guidelines:  
**90cm x 120cm**

### FIRST (PRESENTING) AUTHOR (REQUIRED):

**Name:** Fábio Bernardi Daga - PG1 - DO  
**e-mail:** fabiobernardidaga@gmail.com  
**CEP Number:** 74223210

### 5. ABSTRACT (REQUIRED):

**Title: Hazard Detection During Simulated Driving in Glaucoma Patients**

**Author and Co-authors:** Fabio B. Daga, Erwin R. Boer, Alberto Diniz-Filho, Ivan Maynard Tavares, Felipe A. Medeiros

**Purpose:** Previous studies have shown glaucoma patients to be at higher risk for motor vehicle crashes. However, the role of standard automated perimetry (SAP) in predicting driving performance under hazardous situations has not been clarified. The purpose of this study was to evaluate the impact of different hazardous conditions on driving performance in glaucoma patients, as investigated on a driving simulator, and to investigate the ability of SAP in predicting driving performance.

**Methods:** This was a cross-sectional study including 51 glaucoma patients and 15 control subjects. All subjects underwent high-fidelity driving simulation using a full-size Ford Fusion cab equipped with realistic force feedback steering and motion platform. All subjects also had SAP with SITA Standard 24-2 strategy. A series of realistic driving scenarios were presented to simulate different types of hazardous situations occurring while subjects drove in a city environment. Examples of hazards included pedestrians crossing the street inadvertently and sudden vehicle crossings. The reaction times (RTs) to these hazard events were measured by evaluating the time it took to take the foot off the gas pedal and the time it took to press the break pedal. RTs were compared between glaucoma and controls and the relationship between visual field loss on SAP and RTs was also investigated.

**Results:** There were no differences in age, gender, and race between groups. As expected, glaucoma patients had significantly lower average binocular SAP mean sensitivity than control subjects (26.9 dB vs. 31.6dB, P=0.01). Overall mean RT to pressing the break was 3073ms (95% CI: 2726 ? 3420ms) in glaucoma patients versus 2308ms (95% CI: 1819 ? 2796ms) in controls. Glaucoma patients had longer breaking RTs to hazardous events than control subjects, even after adjusting for age and gender (P = 0.004). Similar results were found to RTs to take the foot off the gas pedal. SAP MS explained only a relatively small proportion of variability in RTs, with R2 ranging from 1% to 31%.

**Conclusion:** Subjects with glaucoma may be at increased driving risk when facing hazardous situations. However, such risk cannot be fully predicted by results from perimetry, indicating that judgements about fitness to drive in this population should not rely solely on the severity of visual field loss.

**Keywords:** glaucoma, visual field, hazard, driving

## 2019 Research Days Abstract Form

### 2. SCIENTIFIC SECTION PREFERENCE (REQUIRED):

Review the Scientific Section Descriptions. Select and enter the two-letter Code for the one (1) Section best suited to review your abstract.

**(GL) GLAUCOMA**

### 3. PRESENTATION PREFERENCE (REQUIRED)

Check one:

**(GL) GLAUCOMA**

4. The signature of the First (Presenting) Author (REQUIRED) acting as the authorized agent for all authors, hereby certifies that any research reported was conducted in compliance with the Declaration of Helsinki and the 'UNIFESP Ethical Committee'

### Scientific Section Descriptions (two-letter code):

(BE) OCULAR BIOENGINEERING  
(CO) CORNEA AND EXTERNAL DISEASE  
(CA) CATARACT  
(EF) ELECTROPHYSIOLOGY  
(EP) EPIDEMIOLOGY  
(EX) EXPERIMENTAL SURGERY  
(GL) GLAUCOMA  
(LA) LABORATORY  
(LS) LACRIMAL SYSTEM  
(LV) LOW VISION  
(NO) NEURO-OPHTHALMOLOGY  
(OR) ORBIT  
(PL) OCULAR PLASTIC SURGERY  
(PH) PHARMACOLOGY  
(RE) RETINA AND VITREOUS  
(RS) REFRACTIVE SURGERY  
(RX) REFRACTION-CONTACT LENSES  
(ST) STRABISMUS  
(TR) TRAUMA  
(TU) TUMORS AND PATHOLOGY  
(UV) UVEITIS  
(US) OCULAR ULTRASOUND

Deadline: 10/2019

### FORMAT:

#### Abstract should contain:

Title  
Author  
Co-authors (maximum 6)  
Purpose  
Methods  
Results  
Conclusion  
Keywords

Poster guidelines:  
**90cm x 120cm**

### FIRST (PRESENTING) AUTHOR (REQUIRED):

**Name:** Izabela Negrão Frota De Almeida - PG1 - DO  
**e-mail:** almeidaizabela@gmail.com  
**CEP Number:** 66063060

### 5. ABSTRACT (REQUIRED):

**Title: NAILFOLD CAPILLAROSCOPY AND LASER DOPPLER FLOWMETRY ANALYSES IN GLAUCOMA: COMPARISON OF VASCULAR PARAMETERS BETWEEN EYES WITH HIGH AND LOW-TENSION OPTIC DISC HEMORRHAGE**

**Author and Co-authors:** Izabela Almeida, MD,1,2 Elise Taniguchi, MD,1 Cecília Victoria Agapito Tito, MD,1 Claudio Zett,1 Carolina Pelegrini Barbosa Gracitelli, MD, PhD1, Sérgio H. Teixeira, MD, PhD,1 Cristiane Kayser, MD, PhD,1 Augusto Paranhos Jr, MD, PhD,1 Tiago S Prata, MD, PhD1,2

**Purpose:** To compare vascular function-related parameters, as assessed by nailfold capillaroscopy and Laser Doppler Imaging of distal phalanx, between open angle glaucoma (OAG) patients with high (HTDH) and low-tension optic disc hemorrhages (LTDH).

**Methods:** In this prospective study, we examined consecutive OAG patients for the presence of DHs. Glaucoma was defined as glaucomatous optic neuropathy and reproducible visual field defects. Disc photographs of all patients were evaluated for the presence of DH by two glaucoma specialists. Patients were classified as HTDH if presenting with an intraocular pressure (IOP)  $\geq 16$  mmHg at the time of DH detection. Those with an IOP  $\geq 16$  mmHg were classified as LTDH. Clinical and ocular data from the time of DH detection were collected. In addition, nailfold capillaroscopy and Laser Doppler Imaging of all fingers were evaluated, except for the thumbs. Laser Doppler Imaging was performed before and after cold stimulation by immersion of both hands in water at 15°C for 60 seconds, followed by monitoring of blood flow at 1, 10 and 20 minutes after cold stimulus.

**Results:** Thirty-two patients were included, with a mean of  $62 \pm 13$  years. There was no significant difference in demographic and ocular data between groups. The nailfold capillaroscopy of both groups was altered in more than 85% of the cases (qualitative analysis). Blood flow measurement values in LTDH patients were lower than those observed in patients with HTDH 10 minutes after cold stimulus ( $241 \pm 105$  vs  $380 \pm 59$ ,  $p < 0.01$ ), and persisted lower at 20 minutes ( $258 \pm 113$  vs  $398 \pm 51$ ,  $p < 0.01$ ).

**Conclusion:** Our interim results suggest that over 85% of the OAG patients with DH present nailfold capillaroscopy abnormalities. Patients developing DH with lower IOPs tend to have more peripheral vascular dysfunction (than those with higher IOPs), as estimated by Laser Doppler Imaging.

**Keywords:** Open angle glaucoma; disk hemorrhage; vascular evaluation; nailfold capillaroscopy; Laser Doppler Imaging.

## 2019 Research Days Abstract Form

### 2. SCIENTIFIC SECTION PREFERENCE (REQUIRED):

Review the Scientific Section Descriptions. Select and enter the two-letter Code for the one (1) Section best suited to review your abstract.

**(GL) GLAUCOMA**

### 3. PRESENTATION PREFERENCE (REQUIRED)

Check one:

**(GL) GLAUCOMA**

4. The signature of the First (Presenting) Author (REQUIRED) acting as the authorized agent for all authors, hereby certifies that any research reported was conducted in compliance with the Declaration of Helsinki and the "UNIFESP Ethical Committee"

### Scientific Section Descriptions (two-letter code):

(BE) OCULAR BIOENGINEERING  
(CO) CORNEA AND EXTERNAL DISEASE  
(CA) CATARACT  
(EF) ELECTROPHYSIOLOGY  
(EP) EPIDEMIOLOGY  
(EX) EXPERIMENTAL SURGERY  
(GL) GLAUCOMA  
(LA) LABORATORY  
(LS) LACRIMAL SYSTEM  
(LV) LOW VISION  
(NO) NEURO-OPHTHALMOLOGY  
(OR) ORBIT  
(PL) OCULAR PLASTIC SURGERY  
(PH) PHARMACOLOGY  
(RE) RETINA AND VITREOUS  
(RS) REFRACTIVE SURGERY  
(RX) REFRACTION-CONTACT LENSES  
(ST) STRABISMUS  
(TR) TRAUMA  
(TU) TUMORS AND PATHOLOGY  
(UV) UVEITIS  
(US) OCULAR ULTRASOUND

Deadline: 10/2019

### FORMAT:

#### Abstract should contain:

Title  
Author  
Co-authors (maximum 6)  
Purpose  
Methods  
Results  
Conclusion  
Keywords

Poster guidelines:  
**90cm x 120cm**

### FIRST (PRESENTING) AUTHOR (REQUIRED):

**Name:** Renata Tieme Kato Kunitake - PG1 - ME  
**e-mail:** tiekato@gmail.com  
**CEP Number:** 0756/2018

### 5. ABSTRACT (REQUIRED):

**Title: Chromatic vision and structural macular assessment in controlled primary congenital glaucoma children**

**Author and Co-authors:** Renata Tiemi Kato, Christiane Rolim de Moura, Norma Allemann

**Purpose:** Primary congenital glaucoma is a rare condition at birth or early infancy and usually requires surgical treatment with high success rates. However, even early treated and IOP controlled cases may have impact on vision development. This study aims to test color vision and perform structural macular and optic nerve assessment in controlled primary congenital children and describe acquired color vision defect in this sample.

**Methods:** Controlled primary congenital glaucoma children aged five to twelve years old, corrected visual acuity better than 20/200 and IOP controlled with topical eye drops or surgical interventions were included. Exclusion criteria involved non glaucomatous optic neuritis, retinal diseases, previous ocular trauma or systemic medications intake related to color vision defects. All eyes were submitted to exams in three steps: 1. Color vision test using Farnsworth D-15 (Quantitative color vision test, Precision Vision), one eye each time chosen randomly, 2. Complete ophthalmic exam: visual acuity, refraction, IOP measurement (Icare®, Tiolat Oy) and slit lamp biomicroscopy, 3. Fundoscopy under mydriasis and further structural macular and optic nerve imaging (SD-OCT Spectralis, Heidelberg Eng.).

**Results:** Eleven eyes of seven congenital glaucoma children were analyzed. Mean age was 7.71 (5-10) years old. All patients presented bilateral primary congenital glaucoma and a cup-to-disc ratio larger than 0.6. Myopia was more prevalent in the group (0.25 Sph to -17.0 Sph) and best corrected visual acuity ranged from 20/20 to 20/200. Younger children (5 years old) and children with worse visual acuity (20/200) performed worse in color vision testing. Color vision test was normal in 7 eyes (63.6%) and abnormal with no specific pattern in 4 eyes (36.4%). In the group with abnormal color vision, overall RNFL thickness was 67.0 microns (SD=8.04), foveal thickness was 258.33 microns (SD=38.72). In the group with normal color vision, RNFL thickness was 75.17 (SD=20.41) and foveal thickness was 261.0 microns (SD=4.0).

**Conclusion:** Structural measurements of macular thickness and peripapillary retinal nerve fiber layer were possible using SD-OCT in children with controlled primary congenital glaucoma. In the sample evaluated, four eyes showed abnormal color vision, and could be related to younger age and worst visual acuity.

**Keywords:** Primary congenital glaucoma; children; color vision defects; ocular coherence tomography.

## 2019 Research Days Abstract Form

### 2. SCIENTIFIC SECTION PREFERENCE (REQUIRED):

Review the Scientific Section Descriptions. Select and enter the two-letter Code for the one (1) Section best suited to review your abstract.

**(GL) GLAUCOMA**

### 3. PRESENTATION PREFERENCE (REQUIRED)

Check one:

**(GL) GLAUCOMA**

4. The signature of the First (Presenting) Author (REQUIRED) acting as the authorized agent for all authors, hereby certifies that any research reported was conducted in compliance with the Declaration of Helsinki and the "UNIFESP Ethical Committee"

### Scientific Section Descriptions (two-letter code):

(BE) OCULAR BIOENGINEERING  
(CO) CORNEA AND EXTERNAL DISEASE  
(CA) CATARACT  
(EF) ELECTROPHYSIOLOGY  
(EP) EPIDEMIOLOGY  
(EX) EXPERIMENTAL SURGERY  
(GL) GLAUCOMA  
(LA) LABORATORY  
(LS) LACRIMAL SYSTEM  
(LV) LOW VISION  
(NO) NEURO-OPHTHALMOLOGY  
(OR) ORBIT  
(PL) OCULAR PLASTIC SURGERY  
(PH) PHARMACOLOGY  
(RE) RETINA AND VITREOUS  
(RS) REFRACTIVE SURGERY  
(RX) REFRACTION-CONTACT LENSES  
(ST) STRABISMUS  
(TR) TRAUMA  
(TU) TUMORS AND PATHOLOGY  
(UV) UVEITIS  
(US) OCULAR ULTRASOUND

Deadline: 10/2019

### FORMAT:

#### Abstract should contain:

Title  
Author  
Co-authors (maximum 6)  
Purpose  
Methods  
Results  
Conclusion  
Keywords

Poster guidelines:  
**90cm x 120cm**

### FIRST (PRESENTING) AUTHOR (REQUIRED):

**Name:** Jenifer Shen Ay Wu - R3  
**e-mail:** jenifersawu@gmail.com  
**CEP Number:** 0762/2016

### 5. ABSTRACT (REQUIRED):

**Title: Clinical experience with non-valved glaucoma drainage device implantation by surgeons-in-training: a five-year follow-up**

**Author and Co-authors:** Wu JSA, Azevedo AGB, Nagatsuyu DT, Vessani RM, Tavares IM

**Purpose:** Even though young surgeons have been learning the glaucoma drainage devices (GDD) procedures over the last years, there are few studies about glaucoma surgery performed by surgeons-in-training, and the majority of them analyze only trabeculectomy or a comparative between trabeculectomy and GDD. The purpose of this study is to report results of a five-year follow-up of GDD implanted by third-year residents and first-year glaucoma fellows.

**Methods:** We reviewed the records of patients who underwent Baerveldt implant surgery (Abbott Medical Optics, Inc., Santa Ana, CA) from April 2011 to August 2013 for advanced medically uncontrolled glaucoma. In patients with bilateral Baerveldt implantation, only the first eye to undergo surgery was included in the study. All patients had Baerveldt implantation performed by third-year resident or first-year glaucoma fellow surgeons. Criteria for surgical failure were (if any of the following criteria are met): (1) IOP: < 6 mmHg, > 21 mmHg, or reduction < 20% from baseline in two consecutive visits after three months, (2) complication related to the implant surgery, (3) additional glaucoma procedure required. Data were analyzed using STATA 14.0 software (StataCorp LP, College Station, TX, USA). Tube survival was assessed using the Kaplan-Meier method, and Cox Proportional Hazard Models were employed to assess factors associated with tube survival, and Hazard Ratios calculation with 95% confidence intervals. Loss of follow-up was considered in all calculations. P value was considered significant when < 0.05.

**Results:** Forty-nine patients (mean age 55.98) were submitted to Baerveldt 350-mm2 glaucoma implant performed by surgeons-in-training. Most of them (36.73%) due to refractory primary open-angle glaucoma, followed by neovascular glaucoma (32.65%), other secondary glaucomas (24.49%), and primary angle-closure glaucoma (6.12%). Surgical failure occurred in 24 of the cases reviewed during the 5-year follow-up period, and a total of nine patients lost follow-up. Eleven of these failures were during the initial 3-month follow-up, and late failures occurred in thirteen cases. Most late failures were due to poor IOP control, leading to loss of vision or new glaucoma procedures (61.53%). On the other hand, early failure happened mostly due to early post-operative complications, like shallow anterior chamber (45.4%), and implant exposure (18.1%) and obstruction (27.2%). Surgical success was achieved in 27/46 cases after one year, 24/46 cases after two years, and 16/40 cases after five years of follow-up. Survival rates were, respectively, 52.08%, 45.83% and 33.33%. Four patients managed to achieve target IOP without any medication, while 12 patients needed one or more topical medication. The average number of topical drugs in this second group was 1.83. The only factor associated with tube survival was the presence of early postoperative complication. Individuals with early postoperative complications were eight times more likely to fail (HR=8.12, 95% CI: 3.3-19.4)

**Conclusion:** In a sample of more advanced and refractory glaucoma patients, the Baerveldt 350 implantation by surgeons-in-training was shown to be safe and efficient in most cases, although with poorer outcomes when compared to glaucoma-trained surgeons. Almost half of failures were related to early postoperative complications.

**Keywords:** glaucoma surgery, aqueous shunt implantation, survival, glaucoma drainage device

## 2019 Research Days Abstract Form

### 2. SCIENTIFIC SECTION PREFERENCE (REQUIRED):

Review the Scientific Section Descriptions. Select and enter the two-letter Code for the one (1) Section best suited to review your abstract.

**(UV) UVEITIS**

### 3. PRESENTATION PREFERENCE (REQUIRED)

Check one:

**(UV) UVEITIS**

4. The signature of the First (Presenting) Author (REQUIRED) acting as the authorized agent for all authors, hereby certifies that any research reported was conducted in compliance with the Declaration of Helsinki and the "UNIFESP Ethical Committee"

### Scientific Section Descriptions (two-letter code):

(BE) OCULAR BIOENGINEERING  
(CO) CORNEA AND EXTERNAL DISEASE  
(CA) CATARACT  
(EF) ELECTROPHYSIOLOGY  
(EP) EPIDEMIOLOGY  
(EX) EXPERIMENTAL SURGERY  
(GL) GLAUCOMA  
(LA) LABORATORY  
(LS) LACRIMAL SYSTEM  
(LV) LOW VISION  
(NO) NEURO-OPHTHALMOLOGY  
(OR) ORBIT  
(PL) OCULAR PLASTIC SURGERY  
(PH) PHARMACOLOGY  
(RE) RETINA AND VITREOUS  
(RS) REFRACTIVE SURGERY  
(RX) REFRACTION-CONTACT LENSES  
(ST) STRABISMUS  
(TR) TRAUMA  
(TU) TUMORS AND PATHOLOGY  
(UV) UVEITIS  
(US) OCULAR ULTRASOUND

Deadline: 10/2019

### FORMAT:

#### Abstract should contain:

Title  
Author  
Co-authors (maximum 6)  
Purpose  
Methods  
Results  
Conclusion  
Keywords

Poster guidelines:  
**90cm x 120cm**

### FIRST (PRESENTING) AUTHOR (REQUIRED):

**Name:** Aristófanés Mendonça Canamary Júnior - PG1 - DO  
**e-mail:** aristofanesjunior@gmail.com  
**CEP Number:** 60810195

### 5. ABSTRACT (REQUIRED):

#### **Title: Quality-of-Life and Psychosocial Aspects in Patients with Ocular Toxoplasmosis: A Clinical Study**

**Author and Co-authors:** Aristofanes Jr, Isabela Ribeiro, Monique Mangeon, Caio Regatieri, Luci Silva, Ricardo Casaroli, Cristina Muccioli

**Purpose:** To evaluate quality of life in patients with uveitis-related to toxoplasmosis and its correlation with demographic, ocular involvement and psychosocial aspects

**Methods:** Data were collected through standardized interviews using a form to collect clinical and demographic data. Specific forms such as HADS, SF-12, NEI-VFQ-25 for health-related quality of life and anxiety and depression symptoms were also used.

**Results:** 81 patients were included with a mean age of  $41.5 \pm 14.5$  years, females (50.6%) They were divided into three categories of best corrected visual acuity in the better seeing eye: normal (0-0.4 logMAR, 60 participants), low vision (0.48-0.9 logMAR, 9 participants) and blindness ( $>1$  logMAR, 12 participants). The mean of VFQ-25 score was  $75.5 \pm 19.5$  and the mean of SF-12 physical and mental components scores were  $48.5 \pm 7.4$  and  $52.4 \pm 10.6$  for health-related quality of life (HRQoL). Anxiety symptoms were most prevalent than depression and were found in 38% of the subjects.

**Conclusion:** Slightly more than a quarter of the sample presented impaired vision. It may impact the quality of life since mostly some mental and related to the vision domains scores are affected. This involves familiar and social relations as they can impact on daily activities.

**Keywords:** Toxoplasmosis, posterior uveitis, quality of life, anxiety, depression

## 2019 Research Days Abstract Form

### 2. SCIENTIFIC SECTION PREFERENCE (REQUIRED):

Review the Scientific Section Descriptions. Select and enter the two-letter Code for the one (1) Section best suited to review your abstract.

**(UV) UVEITIS**

### 3. PRESENTATION PREFERENCE (REQUIRED)

Check one:

**(UV) UVEITIS**

4. The signature of the First (Presenting) Author (REQUIRED) acting as the authorized agent for all authors, hereby certifies that any research reported was conducted in compliance with the Declaration of Helsinki and the "UNIFESP Ethical Committee"

### Scientific Section Descriptions (two-letter code):

(BE) OCULAR BIOENGINEERING  
(CO) CORNEA AND EXTERNAL DISEASE  
(CA) CATARACT  
(EF) ELECTROPHYSIOLOGY  
(EP) EPIDEMIOLOGY  
(EX) EXPERIMENTAL SURGERY  
(GL) GLAUCOMA  
(LA) LABORATORY  
(LS) LACRIMAL SYSTEM  
(LV) LOW VISION  
(NO) NEURO-OPHTHALMOLOGY  
(OR) ORBIT  
(PL) OCULAR PLASTIC SURGERY  
(PH) PHARMACOLOGY  
(RE) RETINA AND VITREOUS  
(RS) REFRACTIVE SURGERY  
(RX) REFRACTION-CONTACT LENSES  
(ST) STRABISMUS  
(TR) TRAUMA  
(TU) TUMORS AND PATHOLOGY  
(UV) UVEITIS  
(US) OCULAR ULTRASOUND

Deadline: 10/2019

### FORMAT:

**Abstract should contain:**

Title  
Author  
Co-authors (maximum 6)  
Purpose  
Methods  
Results  
Conclusion  
Keywords

Poster guidelines:  
**90cm x 120cm**

### FIRST (PRESENTING) AUTHOR (REQUIRED):

**Name:** Marisa Lúcia Romani Paraboni - PG1 - DO  
**e-mail:** marisar@uri.com.br  
**CEP Number:** 99709-294

### 5. ABSTRACT (REQUIRED):

**Title: A new strain of Toxoplasma gondii circulating in southern Brazil**

**Author and Co-authors:** Marisa Lucia Romani Paraboni (1,2), Deise Fialho Costa (1), Claudio Silveira (3), Ricardo Gava (4), Vera Lucia Pereira-Chiocola (4), Alessandra G. Commodaro (1), Rubens Belfort Jr.(1). (1) Department of Ophthalmology EPM, UNIFESP, IPEPO, SP (2) Department of Health Sciences URI, Erechim, RS (3)

**Purpose:** This study was conducted to analyze whether pork meat samples collected in supermarkets from Santa Maria city, RS, could be infected with *T. gondii*.

**Methods:** We analyzed the presence of *T. gondii* DNA in 20 pork hearts, 20 pork tongues and 20 sausages. DNA was extracted from each sample and real-time PCR was performed using 529-bp and B1 markers. *T. gondii* genotypes in heart and tongue samples were performed using multilocus PCR-RFLP (restriction fragment length polymorphism). The genetic markers were SAG1, SAG2 (50-and 30-SAG2), nSAG2, SAG3, BTUB, GRA6, C22-8, c29-2, L358, PK1 and Apico. The set of reactions included: (1) multiplex PCR, (2) nested PCR, and (3) amplified product treatment with restriction enzymes.

**Results:** *T. gondii* DNA was detected in 2 of 20 (10%) heart samples and in 1 of 20 (5%) tongue samples using 529-bp marker. Besides, those 2 (10%) heart samples also were positive for *T. gondii* using B1 marker. All sausage samples were negative for both markers. PCR-RFLP was performed in the 3 qPCR positive samples, after checking the quality and purity of extractions using the primer pair ?1/?2. All of them were genotyped as: a type I allele at SAG1, BTUB, GRA6, c29- 2, PK1 and Apico, type II allele at c22-8, and type III allele at 5?+ 3? SAG2, nSAG2, SAG3 and L358. These results revealed a new non-archetypal *T. gondii* genotype (TgPkSMBra) in Santa Maria/RS, according to the ToxoDB and the literature between 2010 and 2018.

**Conclusion:** We can conclude that food samples containing *T. gondii* can be displayed in Santa Maria supermarkets. In addition, a new *T. gondii* genotype was identified circulating in Southern Brazil.

**Keywords:** Toxoplasma gondii, real-Time PCR, sausage, outbreak, pork meat



## 2019 Research Days Abstract Form

### 2. SCIENTIFIC SECTION PREFERENCE (REQUIRED):

Review the Scientific Section Descriptions. Select and enter the two-letter Code for the one (1) Section best suited to review your abstract.

**(UV) UVEITIS**

### 3. PRESENTATION PREFERENCE (REQUIRED)

Check one:

**(UV) UVEITIS**

4. The signature of the First (Presenting) Author (REQUIRED) acting as the authorized agent for all authors, hereby certifies that any research reported was conducted in compliance with the Declaration of Helsinki and the "UNIFESP Ethical Committee"

### Scientific Section Descriptions (two-letter code):

(BE) OCULAR BIOENGINEERING  
(CO) CORNEA AND EXTERNAL DISEASE  
(CA) CATARACT  
(EF) ELECTROPHYSIOLOGY  
(EP) EPIDEMIOLOGY  
(EX) EXPERIMENTAL SURGERY  
(GL) GLAUCOMA  
(LA) LABORATORY  
(LS) LACRIMAL SYSTEM  
(LV) LOW VISION  
(NO) NEURO-OPHTHALMOLOGY  
(OR) ORBIT  
(PL) OCULAR PLASTIC SURGERY  
(PH) PHARMACOLOGY  
(RE) RETINA AND VITREOUS  
(RS) REFRACTIVE SURGERY  
(RX) REFRACTION-CONTACT LENSES  
(ST) STRABISMUS  
(TR) TRAUMA  
(TU) TUMORS AND PATHOLOGY  
(UV) UVEITIS  
(US) OCULAR ULTRASOUND

Deadline: 10/2019

### FORMAT:

**Abstract should contain:**

Title  
Author  
Co-authors (maximum 6)  
Purpose  
Methods  
Results  
Conclusion  
Keywords

Poster guidelines:  
**90cm x 120cm**

### 1. FIRST (PRESENTING) AUTHOR (REQUIRED):

**Name:** Bruno De Paula Freitas - PG1 - DO  
**e-mail:** brunodepaulafreitas@hotmail.co  
**CEP Number:** 1370484

### 5. ABSTRACT (REQUIRED):

**Title: Physical and developmental findings in children born to ZIKV infected mothers during pregnancy: a cohort study of urban slum residents.**

**Author and Co-authors:** Juan P. Aguilar, Bruno de Paula Freitas, Nivison Junior, Joseane Bouzon, Jamary Oliveira-Filho, Rubens Belfort Jr. , Mitermayer G. Reis, Ana Borja, Haritha Adhikarla, Magelda Montoya, Athena Chin, Verena Ballalai, Eva Harris, Albert I. Ko, Federico Costa

**Purpose:** To evaluate the risk of developmental, neurological, audiometric, ophthalmological and anthropometric growth abnormalities in children born to ZIKV infected mothers during pregnancy.

**Methods:** Fiocruz researchers have been conducting a community-based prospective study of leptospirosis among 2,016 urban slum residents since January 2013 in Salvador, Brazil. From this population, we identified women who were pregnant from January 2015 to June 2016 and identified incident ZIKV seroconversion events among participants, independently of clinical symptoms, by analyzing sera samples collected biannually for presence of ZIKV35 monoclonal antibody reactivity using the blockade-of-binding (BOB) assay. We evaluated adverse outcomes during pregnancy, birth and infancy by interviewing mothers and performing anthropometric measurements, neurologic, audiometric and ophthalmological evaluations as well as and Bayley Scales of Infant Development of their children.

**Results:** Among the 655 women between 10 and 49 years old participating in this cohort, 66 (10%) had at least one pregnancy during the study period. We completed follow-up for 46 (70%) of these women, of whom ZIKV seroconversion occurred prior to, during, and after pregnancy in 25 (54%), 13 (28%), and 1 (2%), respectively. None of the 46 children evaluated had evidence of microcephaly or congenital defects at birth. However, the 13 children of mothers who seroconverted during pregnancy had increased risk of decreased or borderline cognitive development scores (RR 5,07, 95% CI 1,05 ? 24,44) compared with the 33 children of mothers who did not seroconvert during pregnancy (4 of 13 [31%] vs. 2 of 33 [6%], respectively).

**Conclusion:** This population-based study did not identify severe CZS manifestations such as microcephaly or typical fundus lesions. However, our findings suggest that symptomatic and asymptomatic ZIKV infection during pregnancy is associated with frequent and mild neurodevelopmental abnormalities in children approximately one to two years of age. Children of mothers exposed to ZIKV during pregnancy had five times greater risk of cognitive delay than children of non-exposed mothers.

**Keywords:** Zika, Congenital Zika Syndrome, Ocular Findings, Neurodevelopmentment, Developmental abnormalities

## 2019 Research Days Abstract Form

### 2. SCIENTIFIC SECTION PREFERENCE (REQUIRED):

Review the Scientific Section Descriptions. Select and enter the two-letter Code for the one (1) Section best suited to review your abstract.

**(TU) TUMORS AND PATHOLOGY**

### 3. PRESENTATION PREFERENCE (REQUIRED)

Check one:

**(TU) TUMORS AND PATHOLOGY**

4. The signature of the First (Presenting) Author (REQUIRED) acting as the authorized agent for all authors, hereby certifies that any research reported was conducted in compliance with the Declaration of Helsinki and the "UNIFESP Ethical Committee"

### Scientific Section Descriptions (two-letter code):

(BE) OCULAR BIOENGINEERING  
(CO) CORNEA AND EXTERNAL DISEASE  
(CA) CATARACT  
(EF) ELECTROPHYSIOLOGY  
(EP) EPIDEMIOLOGY  
(EX) EXPERIMENTAL SURGERY  
(GL) GLAUCOMA  
(LA) LABORATORY  
(LS) LACRIMAL SYSTEM  
(LV) LOW VISION  
(NO) NEURO-OPHTHALMOLOGY  
(OR) ORBIT  
(PL) OCULAR PLASTIC SURGERY  
(PH) PHARMACOLOGY  
(RE) RETINA AND VITREOUS  
(RS) REFRACTIVE SURGERY  
(RX) REFRACTION-CONTACT LENSES  
(ST) STRABISMUS  
(TR) TRAUMA  
(TU) TUMORS AND PATHOLOGY  
(UV) UVEITIS  
(US) OCULAR ULTRASOUND

Deadline: 10/2019

### FORMAT:

**Abstract should contain:**

Title  
Author  
Co-authors (maximum 6)  
Purpose  
Methods  
Results  
Conclusion  
Keywords

Poster guidelines:  
**90cm x 120cm**

### FIRST (PRESENTING) AUTHOR (REQUIRED):

**Name:** Jorge Henrique Cavalcante Tavares - Fellow  
**e-mail:** jorgehenriquet@hotmail.com  
**CEP Number:** 0

### 5. ABSTRACT (REQUIRED):

**Title: Choroidal Melanoma: tumor profile and treatment outcome.**

**Author and Co-authors:** Tavares, JHC, Dias, MBB, Gameiro Filho, AR, Fernandes, AG, Morales, MC, Belfort, RN.

**Purpose:** To analyze the profile of patients diagnosed with choroidal melanoma at the Ocular Oncology Division from the Department of Ophthalmology - UNIFESP and to investigate the frequency of eyes treated by enucleation that could have been treated with brachytherapy, if available.

**Methods:** A retrospective study was conducted by medical records review of patients with initial diagnostic hypothesis of choroidal melanoma who attended our service from January 2014 to June 2019. Data regarding age, sex, clinical diagnosis of melanoma, measurement of the tumor by ultrasonography and established treatment were collected. Among the patients submitted to enucleation, we analyzed how many could have been selected to receive brachytherapy.

**Results:** Out of 94 patients referred to our service with initial diagnostic hypothesis of choroidal melanoma, 58 (61.7%) had the diagnosis confirmation. A similar rate in males (55.2%) and females (44.8%) was observed and most patients were originally from Sao Paulo State (81.0%). Mean age at diagnosis was  $63.02 \pm 12.91$  years old. Mean ultrasound measurements of the tumors in millimeters were:  $12.19 \pm 2.83$  by  $14.04 \pm 3.11$  in basal diameter and  $9.61 \pm 3.74$  in height. A total of 37 patients (63.8%) were enucleated, 5 patients (8.6%) were treated with brachytherapy at other Hospitals, and 16 patients (27.6%) were referred to the original Hospital for enucleation surgery or lost the follow-up. Out of the 37 patients enucleated, 15 (40.5%) could have been selected to brachytherapy treatment if it was available in our service.

**Conclusion:** The epidemiological findings of this study are in accordance with international literature on choroidal melanomas. It's known that the risk of metastasis is similar for patients with tumors smaller than 10mm in height treated with enucleation or brachytherapy. This study shows that a high percentage of patients were submitted to a technique that leads immediately to blindness due to an unavailability of brachytherapy.

**Keywords:** Uveal Melanoma; Choroid neoplasms; Brachytherapy

## 2019 Research Days Abstract Form

### 2. SCIENTIFIC SECTION PREFERENCE (REQUIRED):

Review the Scientific Section Descriptions. Select and enter the two-letter Code for the one (1) Section best suited to review your abstract.

**(TU) TUMORS AND PATHOLOGY**

### 3. PRESENTATION PREFERENCE (REQUIRED)

Check one:

**(TU) TUMORS AND PATHOLOGY**

4. The signature of the First (Presenting) Author (REQUIRED) acting as the authorized agent for all authors, hereby certifies that any research reported was conducted in compliance with the Declaration of Helsinki and the "UNIFESP Ethical Committee"

### Scientific Section Descriptions (two-letter code):

(BE) OCULAR BIOENGINEERING  
(CO) CORNEA AND EXTERNAL DISEASE  
(CA) CATARACT  
(EF) ELECTROPHYSIOLOGY  
(EP) EPIDEMIOLOGY  
(EX) EXPERIMENTAL SURGERY  
(GL) GLAUCOMA  
(LA) LABORATORY  
(LS) LACRIMAL SYSTEM  
(LV) LOW VISION  
(NO) NEURO-OPHTHALMOLOGY  
(OR) ORBIT  
(PL) OCULAR PLASTIC SURGERY  
(PH) PHARMACOLOGY  
(RE) RETINA AND VITREOUS  
(RS) REFRACTIVE SURGERY  
(RX) REFRACTION-CONTACT LENSES  
(ST) STRABISMUS  
(TR) TRAUMA  
(TU) TUMORS AND PATHOLOGY  
(UV) UVEITIS  
(US) OCULAR ULTRASOUND

Deadline: 10/2019

### FORMAT:

#### Abstract should contain:

Title  
Author  
Co-authors (maximum 6)  
Purpose  
Methods  
Results  
Conclusion  
Keywords

Poster guidelines:  
**90cm x 120cm**

### FIRST (PRESENTING) AUTHOR (REQUIRED):

**Name:** Mariana Borges Barcellos Dias - Fellow  
**e-mail:** marianabbd@gmail.com  
**CEP Number:** 8.710.010

### 5. ABSTRACT (REQUIRED):

**Title: Frequency of eye metastases in patients with non-ocular metastatic neoplasia**

**Author and Co-authors:** DIAS, MBB , TAVARES, JHC , GAMEIRO FILHO, AR , MORALES, MC , BELFORT NETO, RM , FERNANDES, AG

**Purpose:** To evaluate the frequency of ocular metastases in patients with metastatic systemic neoplasia at the oncology department of Hospital São Paulo.

**Methods:** Sixty patients with metastatic systemic neoplasia followed by the oncology service of Hospital São Paulo (HSP) will be evaluated. They will undergo a series of ophthalmologic exams as biomicroscopy, tonometry and funduscopy. If needed they will perform other sophisticated exams as retinography and optic coherence tomography.

**Results:** So far, only 4 patients were evaluated, two with primary mammary site and two with rectal neoplastic origin. All patients did not present alterations suggestive of ocular metastatic involvement.

**Conclusion:** More patients are required for a more complete conclusion.

**Keywords:** Ocular metastasis ; choroidal metastasis ; oncology

## 2019 Research Days Abstract Form

### 2. SCIENTIFIC SECTION PREFERENCE (REQUIRED):

Review the Scientific Section Descriptions. Select and enter the two-letter Code for the one (1) Section best suited to review your abstract.

**(TU) TUMORS AND PATHOLOGY**

### 3. PRESENTATION PREFERENCE (REQUIRED)

Check one:

**(TU) TUMORS AND PATHOLOGY**

4. The signature of the First (Presenting) Author (REQUIRED) acting as the authorized agent for all authors, hereby certifies that any research reported was conducted in compliance with the Declaration of Helsinki and the "UNIFESP Ethical Committee"

### Scientific Section Descriptions (two-letter code):

(BE) OCULAR BIOENGINEERING  
(CO) CORNEA AND EXTERNAL DISEASE  
(CA) CATARACT  
(EF) ELECTROPHYSIOLOGY  
(EP) EPIDEMIOLOGY  
(EX) EXPERIMENTAL SURGERY  
(GL) GLAUCOMA  
(LA) LABORATORY  
(LS) LACRIMAL SYSTEM  
(LV) LOW VISION  
(NO) NEURO-OPHTHALMOLOGY  
(OR) ORBIT  
(PL) OCULAR PLASTIC SURGERY  
(PH) PHARMACOLOGY  
(RE) RETINA AND VITREOUS  
(RS) REFRACTIVE SURGERY  
(RX) REFRACTION-CONTACT LENSES  
(ST) STRABISMUS  
(TR) TRAUMA  
(TU) TUMORS AND PATHOLOGY  
(UV) UVEITIS  
(US) OCULAR ULTRASOUND

Deadline: 10/2019

### FORMAT:

#### Abstract should contain:

Title  
Author  
Co-authors (maximum 6)  
Purpose  
Methods  
Results  
Conclusion  
Keywords

Poster guidelines:  
**90cm x 120cm**

### FIRST (PRESENTING) AUTHOR (REQUIRED):

**Name:** Aluisio Rosa Gameiro Filho - Fellow  
**e-mail:** agameirofilho@yahoo.com.br  
**CEP Number:** 87100100

### 5. ABSTRACT (REQUIRED):

**Title: Ocular Manifestations in Patients with Phacomatosis**

**Author and Co-authors:** Gameiro Filho, AR Dias, MBB Tavares, JHC Fernandes AG Morales, MC Belfort RN

**Purpose:** To evaluate the frequency of ophthalmological manifestations in patients with phacomatosis, in special Von Hippel Lindau syndrome, tuberous sclerosis, neurofibromatosis, and Sturge-Weber syndrome.

**Methods:** Patients with phacomatosis were recruited from medical records reviews and referral from Ophthalmology, Genetics, Neurology, Nephrology, Pediatrics, Gastrology and Urology divisions from UNIFESP. Patients were evaluated by an ophthalmologist who collected information on demographics, age at diagnosis, previous ocular and systemic manifestations, family history and performed a complete eye exam including best-corrected visual acuity, tonometry, biomicroscopy, funduscopy, optical coherence tomography and fundus photography. Other exams as fluorescein angiography were performed when necessary. All patients with ocular findings were treated for the condition.

**Results:** Out of 17 participants evaluated, 5 (29.4%) had Von-Hippel-Lindau syndrome, 5 (29.4%) had tuberous sclerosis, 6 (35.3%) had Neurofibromatosis and 1 (5.9%) had Sturge-Weber syndrome. Von-Hippel-Lindau participants were mostly male (60%), with mean age at exam  $26.4 \pm 12.5$  years old, mean age at diagnosis  $15.6 \pm 6.80$  years old, and had low visual acuity as their first disease manifestation (100%) ? all patients had multiple and bilateral retinal capillary hemangiomas, 1 (20%) patient had unilateral retinal detachment (RD) and 2 (40%) patients had bilateral RD. Tuberous Sclerosis participants were mostly male (60%), with mean age at exam  $26.2 \pm 16.4$  years old, mean age at diagnosis  $8.5 \pm 9.32$  years old, and had either convulsions (60%) or dermatological findings (40%) as their first disease manifestation ? 3 patients (60%) showed ocular manifestations: 2 with the classic finding of astrocistic hamartoma and 1 with areas of retinal depigmentation. Neurofibromatosis type 1 participants were mostly female (66%), with mean age at exam 24.8 years old, mean age at diagnosis  $11.0 \pm 9.02$  years old, and had café-au-lait spots as their first disease manifestation (100%) ? 5 patients (83.3%) showed ocular manifestations: all of them had Lisch nodules in iris, 1 patient had cataract and stenosis of lacrimal punctum, and 1 had a previous story of plexiform neurofibroma in one eyelid.

**Conclusion:** The advances in the study of genetic and molecular bases of phacomatosis are providing a better understand of its pathology, which brings to ophthalmologists a development in diagnosing and treating these conditions. With improved clinical characterizations of the disease, we can better put into context the impact of phacomatosis disease on eye health and understand the functional implication of tumor phenotypes.

**Keywords:** phacomatosis, von hippel lindau, tuberous sclerosis, neurofibromatosis, sturge weber

## 2019 Research Days Abstract Form

### 2. SCIENTIFIC SECTION PREFERENCE (REQUIRED):

Review the Scientific Section Descriptions. Select and enter the two-letter Code for the one (1) Section best suited to review your abstract.

**(TU) TUMORS AND PATHOLOGY**

### 3. PRESENTATION PREFERENCE (REQUIRED)

Check one:

**(TU) TUMORS AND PATHOLOGY**

4. The signature of the First (Presenting) Author (REQUIRED) acting as the authorized agent for all authors, hereby certifies that any research reported was conducted in compliance with the Declaration of Helsinki and the "UNIFESP Ethical Committee"

### Scientific Section Descriptions (two-letter code):

(BE) OCULAR BIOENGINEERING  
(CO) CORNEA AND EXTERNAL DISEASE  
(CA) CATARACT  
(EF) ELECTROPHYSIOLOGY  
(EP) EPIDEMIOLOGY  
(EX) EXPERIMENTAL SURGERY  
(GL) GLAUCOMA  
(LA) LABORATORY  
(LS) LACRIMAL SYSTEM  
(LV) LOW VISION  
(NO) NEURO-OPHTHALMOLOGY  
(OR) ORBIT  
(PL) OCULAR PLASTIC SURGERY  
(PH) PHARMACOLOGY  
(RE) RETINA AND VITREOUS  
(RS) REFRACTIVE SURGERY  
(RX) REFRACTION-CONTACT LENSES  
(ST) STRABISMUS  
(TR) TRAUMA  
(TU) TUMORS AND PATHOLOGY  
(UV) UVEITIS  
(US) OCULAR ULTRASOUND

Deadline: 10/2019

### FORMAT:

#### Abstract should contain:

Title  
Author  
Co-authors (maximum 6)  
Purpose  
Methods  
Results  
Conclusion  
Keywords

Poster guidelines:  
**90cm x 120cm**

### FIRST (PRESENTING) AUTHOR (REQUIRED):

**Name:** Allexya Affonso Antunes Marcos - PG1 - DO  
**e-mail:** allexya.affonso@gmail.com  
**CEP Number:** 4041002

### 5. ABSTRACT (REQUIRED):

**Title: Xeroderma pigmentosa in Brazil: single center experience recruiting patients visa social media**

**Author and Co-authors:** Alléxya Affonso Antunes Marcos, Arthur Gustavo Fernandes, Melina Correa Morales, Denise de Freitas, Rubens N Belfort

**Purpose:** The objective of this study is to evaluate the previous dermatologic and ophthalmic to patients with Xeroderma Pigmentosum (XP) before they were referred to the Department of Ophthalmology and Visual Sciences, Paulista Medical School, Federal University of São Paulo.

**Methods:** We performed a cross-sectional study to evaluate XP patients for complete ophthalmological exam at the Ocular Oncology Service, Federal University of São Paulo. All patients underwent to a complete and standardized anamnesis from which data was obtained for our analysis. Gathered information included personal and past medical history, including sex, age, state of residence, the age at diagnosis, medical specialty who made the diagnosis, the onset age of first cancer, previous medical history of skin and/or ocular cancer confirmed by biopsy, parents consanguinity, family history of XP, frequency of follow-up with dermatologist and ophthalmologist, and if genetic test was performed. We have also gathered information of forms of sun protection.

**Results:** We evaluated 41 patients with xeroderma pigmentosum, of whom 13 (31.71%) were males and 28 (68.29%) females. The mean age was 26.51 years (2-62 years). Thirty-three patients (80.49%) were from the Brazil's southeast region. The mean age of XP diagnosis was 8.46 years old (0.33-30 years). The majority of patients (35 (85.37%) were diagnosed by a dermatologist. The mean age at diagnosis of the first cancer was 10.24 years old (1-30 years). In our cohort, 25 (60.97%) of the patients referred a previous eye cancer and 38 (92.68%) a previous history of skin cancer. The presence of consanguineous marriage was positive in 27 cases (65.85%). Twenty-six (63.41%) patients with XP had another family member affected with the disease. Twenty-three patients (56.10%) were regularly followed with a dermatologist and 29 (70.73%) of the patients were regularly followed by an ophthalmologist. Fifteen (36.59%) patients had genetic testing performed previously. Twenty-two (53.66%) patients do not use adequate sun protection. Six (14.63%) were evaluated by ocular oncologist and 17 (41.46%) by dermatologic oncologist.

**Conclusion:** Finally, the high incidence of ocular surface cancer at an early age reinforces the importance of monitoring these patients with ophthalmologists with experience in ocular oncology. Therefore, with further delineation of genoty-peephenotype associations, we hope to glean further insights into the pathogenesis of the disease and its manifestations and offer patients more individualized care.

**Keywords:** Xeroderma Pigmentosum; Skin Neoplasms; Eye Neoplasms; Abnormalities, Radiation-Induced; Genetics

## 2019 Research Days Abstract Form

### 2. SCIENTIFIC SECTION PREFERENCE (REQUIRED):

Review the Scientific Section Descriptions. Select and enter the two-letter Code for the one (1) Section best suited to review your abstract.

**(RE) RETINA AND VITREOUS**

### 3. PRESENTATION PREFERENCE (REQUIRED)

Check one:

**(RE) RETINA AND VITREOUS**

4. The signature of the First (Presenting) Author (REQUIRED) acting as the authorized agent for all authors, hereby certifies that any research reported was conducted in compliance with the Declaration of Helsinki and the "UNIFESP Ethical Committee"

### Scientific Section Descriptions (two-letter code):

(BE) OCULAR BIOENGINEERING  
(CO) CORNEA AND EXTERNAL DISEASE  
(CA) CATARACT  
(EF) ELECTROPHYSIOLOGY  
(EP) EPIDEMIOLOGY  
(EX) EXPERIMENTAL SURGERY  
(GL) GLAUCOMA  
(LA) LABORATORY  
(LS) LACRIMAL SYSTEM  
(LV) LOW VISION  
(NO) NEURO-OPHTHALMOLOGY  
(OR) ORBIT  
(PL) OCULAR PLASTIC SURGERY  
(PH) PHARMACOLOGY  
(RE) RETINA AND VITREOUS  
(RS) REFRACTIVE SURGERY  
(RX) REFRACTION-CONTACT LENSES  
(ST) STRABISMUS  
(TR) TRAUMA  
(TU) TUMORS AND PATHOLOGY  
(UV) UVEITIS  
(US) OCULAR ULTRASOUND

Deadline: 10/2019

### FORMAT:

**Abstract should contain:**

Title  
Author  
Co-authors (maximum 6)  
Purpose  
Methods  
Results  
Conclusion  
Keywords

Poster guidelines:  
**90cm x 120cm**

### FIRST (PRESENTING) AUTHOR (REQUIRED):

**Name:** Luis Filipe Nakayama - PG0 - DO  
**e-mail:** nakayama.luis@gmail.com  
**CEP Number:** 0189/2018

### 5. ABSTRACT (REQUIRED):

**Title: Retinal microvasculature parameters in patients with Obstructive Sleep Apnea Syndrome**

**Author and Co-authors:** Luis Filipe Nakayama, Vinicius C. Bergamo, Murilo Polizelli, Natasha Cruz, Priscila Tempaku, Sergio Tufik, Nilva S. B. Moraes, Caio Regatieri

**Purpose:** Obstructive Sleep Apnea Syndrome (OSAS) is characterized by episodes of upper airway collapse, and consequent intermittent hypoxemia, sleep fragmentation (AASM, 1999, Young et al., 2002, Marshall et al., 2006) and not repairing sleep. (Slowik, 2017) It is a frequent syndrome, underdiagnosed in 80 to 90 percent of the cases and of increasing clinical importance, with prevalence reaching 32 percent of the adult population of São Paulo, when considering all severity ranges, ages and different ethnicities. (Tufik et al., 2010, AASM 2008). Respiratory changes during the sleep cycle lead to well-established systemic vascular consequences, but there are few studies evaluating retinal findings in non-invasively diagnosed OSAS patients using Swept Source Optical Coherence Tomography (OCT) and OCT Angiography. Objective-Compare findings and parameters of macular retinal microvasculature by optical coherence tomography at different OSAS severity levels.

**Methods:** This study will be conducted by a randomized, double-blind, sham-controlled, 6-month clinical trial. The sample will consist of volunteers of both sexes, age between 18 and 65 years and body mass index  $<35\text{kg} / \text{m}^2$ , with diagnosed OSAS, subdivided according to the severity of the syndrome. The evaluation will consist of physical exam, laboratory exams, all - night polysomnography, complete ophthalmological exam, color retinography, Optica Swept Source Coherence Tomography and OCT - Angiography, Ocular Surface Disease Index score and keratograph evaluation. For statistical analysis we will use descriptive analysis (means  $\pm$  standard deviation) and for analyzes between univariate GLM test groups.

**Results:** 16 patients, all male, mean age of 49,7 years. 7 of 16 (43.75%) presented antecedent of Systemic Arterial Hypertension and 2 of 16 (12.5%) of Mellitus Diabetes. 1 of 16 (6.25%) history of Keratoconus and 1 of 16 (6.25%) history of Toxoplasmosis infection. All data from initial evaluation, pre treatment. 10 patients of 16 (62.5%) presented eyelids increased elasticity. Mean visual acuity of 52.25 letters in right eyes and 53.93 in left eyes. Mean intraocular pressure of 15 mmHg in right eyes and 14.56 mmHg in left eyes. Mean Subfoveal Choroidal thickness of 269.66 in right eyes and 282.66 in left eyes. Mean avascular foveal zone of 275,15 in right eyes and 229,10 in left eyes Mean Ocular Surface Disease Index of 6 in initial evaluation. All patients will be reevaluated 6 months after treatment. Stratified retinal parameters according to Polissomnography score analysis are in progress.

**Conclusion:** Obstructive Sleep Apnea Syndrome is a prevalent disease with distinct systemic microvascular changes. Multimodal retina exams could help to better understand ophthalmological repercussion of the syndrome and if after CPAP treatment it parameters will shows improvement. We found high rates of eyelid increased elasticity (62.5%) and OSDI score of 6. This patients will be re-evaluated after 6 months of CPAP or sham-CPAP treatment to conclude if this changes shows improvement after treatment.

**Keywords:** Retina, Obstructive Sleep Apnea Syndrome, Multimodal Retina exams



## 2019 Research Days Abstract Form

### 2. SCIENTIFIC SECTION PREFERENCE (REQUIRED):

Review the Scientific Section Descriptions. Select and enter the two-letter Code for the one (1) Section best suited to review your abstract.

**(RE) RETINA AND VITREOUS**

### 3. PRESENTATION PREFERENCE (REQUIRED)

Check one:

**(RE) RETINA AND VITREOUS**

4. The signature of the First (Presenting) Author (REQUIRED) acting as the authorized agent for all authors, hereby certifies that any research reported was conducted in compliance with the Declaration of Helsinki and the "UNIFESP Ethical Committee"

### Scientific Section Descriptions (two-letter code):

(BE) OCULAR BIOENGINEERING  
(CO) CORNEA AND EXTERNAL DISEASE  
(CA) CATARACT  
(EF) ELECTROPHYSIOLOGY  
(EP) EPIDEMIOLOGY  
(EX) EXPERIMENTAL SURGERY  
(GL) GLAUCOMA  
(LA) LABORATORY  
(LS) LACRIMAL SYSTEM  
(LV) LOW VISION  
(NO) NEURO-OPHTHALMOLOGY  
(OR) ORBIT  
(PL) OCULAR PLASTIC SURGERY  
(PH) PHARMACOLOGY  
(RE) RETINA AND VITREOUS  
(RS) REFRACTIVE SURGERY  
(RX) REFRACTION-CONTACT LENSES  
(ST) STRABISMUS  
(TR) TRAUMA  
(TU) TUMORS AND PATHOLOGY  
(UV) UVEITIS  
(US) OCULAR ULTRASOUND

Deadline: 10/2019

### FORMAT:

#### Abstract should contain:

Title  
Author  
Co-authors (maximum 6)  
Purpose  
Methods  
Results  
Conclusion  
Keywords

Poster guidelines:  
**90cm x 120cm**

### FIRST (PRESENTING) AUTHOR (REQUIRED):

**Name:** Carlos Eduardo de Souza - PG1 - DO  
**e-mail:** edusouzaa@gmail.com  
**CEP Number:** 4149110

### 5. ABSTRACT (REQUIRED):

#### **Title: Objective Assessment of YAG Laser Vitreolysis in Patients with Symptomatic Vitreous Floaters**

**Author and Co-authors:** Author: Carlos E Souza Co-authors: Luiz H. Lima, Heloísa Nascimento, Claudio Zett, Rubens Belfort Jr,

**Purpose:** To objectively evaluate YAG laser vitreolysis for symptomatic vitreous floaters using color photography imaging

**Methods:** In this interventional and prospective study, 32 eyes of 32 patients with symptomatic vitreous floaters secondary to posterior vitreous detachment (PVD) were treated with a single session of yttrium aluminium garnet (YAG) laser. The primary outcomes were objective and subjective change of vitreous floaters measured by masked grading of color fundus photographs and the National Eye Institute Visual Functioning Questionnaire 25 (NEI VFQ-25) responses. Secondary outcomes included Early Treatment Diabetic Retinopathy Study (ETDRS) best-corrected visual acuity (BCVA), visual disturbance rate (self-reported percentage of vitreous floaters improvement) and ocular adverse events. Wilcoxon signed-rank test was used to analyze the results of the objective and subjective assessments at each time point.  $P < 0.05$  was considered statistically significant.

**Results:** Thirty-two patients (32 eyes, 13 men, mean age: 59.4 years) with symptomatic vitreous floaters were enrolled in this study. All patients were followed up for 6 months. Color fundus photographs did reveal vitreous opacities improvement in 93.7% of study eyes (partial improvement in 37.5% and total improvement in 56.2% of the eyes). There was a statistically significant improvement in both the near visual function ( $z = -2.97$ ,  $p = 0.003$ ,  $r = 0.633$ ) and visual disturbance rate ( $z = -3.97$ ,  $p = 0.001$ ,  $r = 0.84$ ). Distance visual acuity did not show statistically significant difference after the laser procedure ( $p = 1.00$ ). Recurrence of vitreous floaters, BCVA deterioration and ocular adverse events were not observed.

**Conclusion:** YAG laser vitreolysis decreased the amount of vitreous floaters opacities seen on color fundus imaging and improved symptoms according to the NEI VFQ-25 questionnaire.

**Keywords:** Color fundus photograph; NEI VFQ-25 questionnaire; vitreous floaters; vitreolysis; YAG laser.

## 2019 Research Days Abstract Form

### 2. SCIENTIFIC SECTION PREFERENCE (REQUIRED):

Review the Scientific Section Descriptions. Select and enter the two-letter Code for the one (1) Section best suited to review your abstract.

**(RE) RETINA AND VITREOUS**

### 3. PRESENTATION PREFERENCE (REQUIRED)

Check one:

**(RE) RETINA AND VITREOUS**

4. The signature of the First (Presenting) Author (REQUIRED) acting as the authorized agent for all authors, hereby certifies that any research reported was conducted in compliance with the Declaration of Helsinki and the "UNIFESP Ethical Committee"

### Scientific Section Descriptions (two-letter code):

(BE) OCULAR BIOENGINEERING  
(CO) CORNEA AND EXTERNAL DISEASE  
(CA) CATARACT  
(EF) ELECTROPHYSIOLOGY  
(EP) EPIDEMIOLOGY  
(EX) EXPERIMENTAL SURGERY  
(GL) GLAUCOMA  
(LA) LABORATORY  
(LS) LACRIMAL SYSTEM  
(LV) LOW VISION  
(NO) NEURO-OPHTHALMOLOGY  
(OR) ORBIT  
(PL) OCULAR PLASTIC SURGERY  
(PH) PHARMACOLOGY  
(RE) RETINA AND VITREOUS  
(RS) REFRACTIVE SURGERY  
(RX) REFRACTION-CONTACT LENSES  
(ST) STRABISMUS  
(TR) TRAUMA  
(TU) TUMORS AND PATHOLOGY  
(UV) UVEITIS  
(US) OCULAR ULTRASOUND

Deadline: 10/2019

### FORMAT:

#### Abstract should contain:

Title  
Author  
Co-authors (maximum 6)  
Purpose  
Methods  
Results,  
Conclusion  
Keywords

Poster guidelines:  
**90cm x 120cm**

### FIRST (PRESENTING) AUTHOR (REQUIRED):

**Name:** Ramon Antunes De Oliveira - PG1 - DO  
**e-mail:** ramonntt@gmail.com  
**CEP Number:** 522922071

### 5. ABSTRACT (REQUIRED):

**Title: Hydrogel polymer biocompatibility in vitreoretinal surgery.**

**Author and Co-authors:** Ramon Antunes de Oliveira, Andreia de Araújo Morandim-Giannetti, Patrícia Alessandra Bersanetti, Felipe Muralha, Alex Treiger, Paulo Schor, Maurício Maia, Octaviano Magalhães Junior.

**Purpose:** to determine in vitro and in vivo biocompatibility of hydrogel synthesized using polyvinyl alcohol (PVA) and sodium trimetaphosphate (STMP) as crosslinking agent, in vitreoretinal surgery.

**Methods:** Twenty-eight New Zealand albino rabbits (2 kg weight approximately) undergone 25 Ga pars plana vitrectomy using a synthesized hydrogel polymer (HG) as vitreous substitute and balanced salt solution (BSS) in control group (CG) as vitreous substitutes. All animals had fundus image at Topcon TRC camera (Topcon, Tokyo, Japan), fluorescein angiography (FA) in Heidelberg Spectralis Device (Heidelberg Engineering, Heidelberg, Germany), Optical coherence tomography (OCT) in Spectralis OCT (Heidelberg, Germany) and electroretinogram (ERG) in RETI-port/scan 21 (Roland Consult, Bradenburg, Germany) at the day of the surgery (baseline), and one, four and twelve weeks later. Retina tissue samples were sent to optical histology. In vitro toxicity were evaluated in RPE19 cells culture through mitochondrial enzymatic activity.

**Results:** Seventeen animals were euthanized due to retinal detachment or cataract formation during the surgery. Nine animals were at the HG and two at CG. One rabbit developed endophthalmitis and two developed cataract during the follow up in HG. We noted some opacification of the hydrogel polymer at fundus examination and OCT. The scotopic rods response and b-wave cons photopic response were reduced in HG during all the study. Histology from HG revealed intracellular hydrogel particules and retinal disorganisation.

**Conclusion:** Hydrogel polymer revealed unsatisfactory biocompatibility, although reduced number of animals were evaluated. Further different biocompatible materials should be analyzed as an alternative to usual vitreous substitutes. **FINANCIAL SUPPORT:** FAPESP (2016/07468-6)

**Keywords:** vitreous, biomaterials, polymer hidrogels

## 2019 Research Days Abstract Form

### 2. SCIENTIFIC SECTION PREFERENCE (REQUIRED):

Review the Scientific Section Descriptions. Select and enter the two-letter Code for the one (1) Section best suited to review your abstract.

**(RE) RETINA AND VITREOUS**

### 3. PRESENTATION PREFERENCE (REQUIRED)

Check one:

**(RE) RETINA AND VITREOUS**

4. The signature of the First (Presenting) Author (REQUIRED) acting as the authorized agent for all authors, hereby certifies that any research reported was conducted in compliance with the Declaration of Helsinki and the "UNIFESP Ethical Committee"

### Scientific Section Descriptions (two-letter code):

(BE) OCULAR BIOENGINEERING  
(CO) CORNEA AND EXTERNAL DISEASE  
(CA) CATARACT  
(EF) ELECTROPHYSIOLOGY  
(EP) EPIDEMIOLOGY  
(EX) EXPERIMENTAL SURGERY  
(GL) GLAUCOMA  
(LA) LABORATORY  
(LS) LACRIMAL SYSTEM  
(LV) LOW VISION  
(NO) NEURO-OPHTHALMOLOGY  
(OR) ORBIT  
(PL) OCULAR PLASTIC SURGERY  
(PH) PHARMACOLOGY  
(RE) RETINA AND VITREOUS  
(RS) REFRACTIVE SURGERY  
(RX) REFRACTION-CONTACT LENSES  
(ST) STRABISMUS  
(TR) TRAUMA  
(TU) TUMORS AND PATHOLOGY  
(UV) UVEITIS  
(US) OCULAR ULTRASOUND

Deadline: 10/2019

### FORMAT:

#### Abstract should contain:

Title  
Author  
Co-authors (maximum 6)  
Purpose  
Methods  
Results  
Conclusion  
Keywords

Poster guidelines:  
**90cm x 120cm**

### FIRST (PRESENTING) AUTHOR (REQUIRED):

**Name:** Bruno Queiroz Alves - Fellow  
**e-mail:** bruno.q.a@gmail.com  
**CEP Number:** 0038/2017

### 5. ABSTRACT (REQUIRED):

**Title: Combined Femtosecond Laser-Assisted Cataract Surgery and Small-Gauge Pars Plana Vitrectomy Using Different Devices: A New Trend for Vitreoretinal Surgery?**

**Author and Co-authors:** Bruno de Queiroz Alves Mariana Batista Gonçalves Maurício Maia

**Purpose:** To report the efficacy, safety, and benefits of femtosecond laser-assisted cataract surgery combined with sutureless 23-gauge pars plana vitrectomy.

**Methods:** This multicenter, retrospective study evaluated patient records and videos of 43 cases with retinal pathologies and cataract who underwent the combined procedure.

**Results:** In 44.2% and 55.8% of cases, respectively, the LenSx Laser and the Constellation, and the Victus and Stellaris PC were used. No complications developed during capsulorrhexis, even without a red fundus reflex, retrobulbar block, or scleral indentation. Foldable intraocular lenses remained stable in the capsular bag during the vitreoretinal surgeries and postoperative visits. The mean times of femtosecond phacoemulsification, vitreoretinal surgery, and total surgery were 22.9 minutes  $\pm$  4.7 minutes, 43.1 minutes  $\pm$  9.8 minutes, and 65.3 minutes  $\pm$  8.6 minutes, respectively.

**Conclusion:** This emerging technology is safe and offers several potential benefits for the success of the combined procedure.

**Keywords:** femtosecond, vitrectomy

## 2019 Research Days Abstract Form

### 2. SCIENTIFIC SECTION PREFERENCE (REQUIRED):

Review the Scientific Section Descriptions. Select and enter the two-letter Code for the one (1) Section best suited to review your abstract.

**(RE) RETINA AND VITREOUS**

### 3. PRESENTATION PREFERENCE (REQUIRED)

Check one:

**(RE) RETINA AND VITREOUS**

4. The signature of the First (Presenting) Author (REQUIRED) acting as the authorized agent for all authors, hereby certifies that any research reported was conducted in compliance with the Declaration of Helsinki and the "UNIFESP Ethical Committee"

### Scientific Section Descriptions (two-letter code):

(BE) OCULAR BIOENGINEERING  
(CO) CORNEA AND EXTERNAL DISEASE  
(CA) CATARACT  
(EF) ELECTROPHYSIOLOGY  
(EP) EPIDEMIOLOGY  
(EX) EXPERIMENTAL SURGERY  
(GL) GLAUCOMA  
(LA) LABORATORY  
(LS) LACRIMAL SYSTEM  
(LV) LOW VISION  
(NO) NEURO-OPHTHALMOLOGY  
(OR) ORBIT  
(PL) OCULAR PLASTIC SURGERY  
(PH) PHARMACOLOGY  
(RE) RETINA AND VITREOUS  
(RS) REFRACTIVE SURGERY  
(RX) REFRACTION-CONTACT LENSES  
(ST) STRABISMUS  
(TR) TRAUMA  
(TU) TUMORS AND PATHOLOGY  
(UV) UVEITIS  
(US) OCULAR ULTRASOUND

Deadline: 10/2019

### FORMAT:

#### Abstract should contain:

Title  
Author  
Co-authors (maximum 6)  
Purpose  
Methods  
Results  
Conclusion  
Keywords

Poster guidelines:  
**90cm x 120cm**

### FIRST (PRESENTING) AUTHOR (REQUIRED):

**Name:** Mariana Kawamuro - Fellow  
**e-mail:** mkawamuro@gmail.com  
**CEP Number:** 195748/13

### 5. ABSTRACT (REQUIRED):

**Title: Safety and Retinal Toxicity of a Biodegradable Scaffold for Stem Cells Derived RPE Implantation: Preclinical Study in Rabbits**

**Author and Co-authors:** Mariana Kawamuro, MD, Rodrigo A. B. Fernandes, MD, Mauricio Maia, PhD, Fernando Lojudice

**Purpose:** The objective of this study was to evaluate a new biodegradable scaffold with or without cells seeded in its surface in order to access the safety of surgical implantation and possible toxic effects of its degradation in the normal retina of rabbits.

**Methods:** 18 rabbits were submitted to the implantation of biodegradable PLGA (polylactic-co-glycolic acid) scaffolds, seeded or not with embryonic stem cells or ARPE cells (differentiated human RPE cells), and a fourth group underwent a sham surgery as a control group. The animals were divided in groups according to the type of transplant: biomaterial group, biomaterial + H9-RPE (H9 human embryonic stem cells) cells group, biomaterial + ARPE cells group and sham group

**Results:** The majority of the samples showed signs of inflammation and disorganization related to the normal immune reaction of the host body and inadvertent surgical trauma. The PLGA scaffold was present after 30 days post implantation, showing that the degradation period is longer than this time point.

**Conclusion:** The degradation of the PLGA scaffold after 30 days of implantation in rabbits was incomplete and no signs of toxicity in the retinal tissues were observed in the histological analysis.

**Keywords:** PLGA, ARPE, scaffold, rabbits

## 2019 Research Days Abstract Form

### 2. SCIENTIFIC SECTION PREFERENCE (REQUIRED):

Review the Scientific Section Descriptions. Select and enter the two-letter Code for the one (1) Section best suited to review your abstract.

**(RE) RETINA AND VITREOUS**

### 3. PRESENTATION PREFERENCE (REQUIRED)

Check one:

**(RE) RETINA AND VITREOUS**

4. The signature of the First (Presenting) Author (REQUIRED) acting as the authorized agent for all authors, hereby certifies that any research reported was conducted in compliance with the Declaration of Helsinki and the "UNIFESP Ethical Committee"

### Scientific Section Descriptions (two-letter code):

(BE) OCULAR BIOENGINEERING  
(CO) CORNEA AND EXTERNAL DISEASE  
(CA) CATARACT  
(EF) ELECTROPHYSIOLOGY  
(EP) EPIDEMIOLOGY  
(EX) EXPERIMENTAL SURGERY  
(GL) GLAUCOMA  
(LA) LABORATORY  
(LS) LACRIMAL SYSTEM  
(LV) LOW VISION  
(NO) NEURO-OPHTHALMOLOGY  
(OR) ORBIT  
(PL) OCULAR PLASTIC SURGERY  
(PH) PHARMACOLOGY  
(RE) RETINA AND VITREOUS  
(RS) REFRACTIVE SURGERY  
(RX) REFRACTION-CONTACT LENSES  
(ST) STRABISMUS  
(TR) TRAUMA  
(TU) TUMORS AND PATHOLOGY  
(UV) UVEITIS  
(US) OCULAR ULTRASOUND

Deadline: 10/2019

### FORMAT:

#### Abstract should contain:

Title  
Author  
Co-authors (maximum 6)  
Purpose  
Methods  
Results  
Conclusion  
Keywords

Poster guidelines:  
**90cm x 120cm**

### FIRST (PRESENTING) AUTHOR (REQUIRED):

**Name:** Vinicius Campos Bergamo - Fellow  
**e-mail:** viniciusbergamo.epm@gmail.com  
**CEP Number:** 0060/2018

### 5. ABSTRACT (REQUIRED):

**Title: Visual outcome of early Vitrectomy in intravitreal anti-VEGF related endophthalmitis**

**Author and Co-authors:** Vinicius Campos Bergamo, Luis Filipe Nakayama, Nilva Simeren Bueno de Moraes, Maurício Maia

**Purpose:** Our study evaluated visual acuity parameter in patients with previous retinal diseased with acute endophthalmitis after intravitreal injection, who underwent pars plana vitrectomy with 23 gauge instruments.

**Methods:** Retrospective study that analyzed visual acuity parameters in patients with acute endophthalmitis treated with pars plana vitrectomy at the Ophthalmology and Visual Sciences Department of the Paulista School of Medicine - UNIFESP. Data of infectious agents were obtained in the records of the Laboratory of Ophthalmology and Microbiology (LOFT). We considered patients with possible diagnosis of acute endophthalmitis from January of 2012 to January of 2017.

**Results:** Eleven patients with clinical status compatible with acute endophthalmitis after intravitreal injection, with positive result in culture, were analyzed in the period. The mean age of the patients was 63.72 years (35-81). Five females (45.45%) and 6 males (54.54%), with eight infections involving the right eye and three the left eye. All patients presented clinical symptoms of acute endophthalmitis between 2-7 days after surgery, with ocular hyperaemia, anterior chamber and vitreous inflammation, and pain. Visual acuity immediately prior to intravitreal injection was 21.25 during the endophthalmitis episode the mean visual acuity was 0 and after 19.09. The comparison between the visual acuity score before and after vitrectomy showed no statistical difference (p of 0.95).

**Conclusion:** We conclude that early surgery is an option in these patients, but more studies with a larger number of patients and randomized are needed to evaluate the prognostic factors with the new surgical techniques and with a distinction between different ethologies and surgeries associated with acute endophthalmitis infectious.

**Keywords:** Endophthalmitis, retina

## 2019 Research Days Abstract Form

### 2. SCIENTIFIC SECTION PREFERENCE (REQUIRED):

Review the Scientific Section Descriptions. Select and enter the two-letter Code for the one (1) Section best suited to review your abstract.

**(RE) RETINA AND VITREOUS**

### 3. PRESENTATION PREFERENCE (REQUIRED)

Check one:

**(RE) RETINA AND VITREOUS**

4. The signature of the First (Presenting) Author (REQUIRED) acting as the authorized agent for all authors, hereby certifies that any research reported was conducted in compliance with the Declaration of Helsinki and the "UNIFESP Ethical Committee"

### Scientific Section Descriptions (two-letter code):

(BE) OCULAR BIOENGINEERING  
(CO) CORNEA AND EXTERNAL DISEASE  
(CA) CATARACT  
(EF) ELECTROPHYSIOLOGY  
(EP) EPIDEMIOLOGY  
(EX) EXPERIMENTAL SURGERY  
(GL) GLAUCOMA  
(LA) LABORATORY  
(LS) LACRIMAL SYSTEM  
(LV) LOW VISION  
(NO) NEURO-OPHTHALMOLOGY  
(OR) ORBIT  
(PL) OCULAR PLASTIC SURGERY  
(PH) PHARMACOLOGY  
(RE) RETINA AND VITREOUS  
(RS) REFRACTIVE SURGERY  
(RX) REFRACTION-CONTACT LENSES  
(ST) STRABISMUS  
(TR) TRAUMA  
(TU) TUMORS AND PATHOLOGY  
(UV) UVEITIS  
(US) OCULAR ULTRASOUND

Deadline: 10/2019

### FORMAT:

#### Abstract should contain:

Title  
Author  
Co-authors (maximum 6)  
Purpose  
Methods  
Results  
Conclusion  
Keywords

Poster guidelines:  
**90cm x 120cm**

### FIRST (PRESENTING) AUTHOR (REQUIRED):

**Name:** Natasha Ferreira Santos Da Cruz - PG0 - DO  
**e-mail:** natasha\_cruz27@hotmail.com  
**CEP Number:** 66050400

### 5. ABSTRACT (REQUIRED):

#### **Title: Effect of syringe flickage in intravitreal injection of Aflibercept: A randomized double blind clinical trial**

**Author and Co-authors:** Natasha Ferreira Santos Da Cruz, Gustavo Barreto de Melo, Murilo Ubukata Polizelli, Felipe Pincanço Muralha, Caio Vinicius Saito Regatieri, Octaviano Magalhães Júnior, Rubens Belfort Júnior, Maurício Maia, Michel Eid Farah

**Purpose:** To evaluate ocular inflammation after intravitreal injection of aflibercept according to the syringe handling technique.

**Methods:** A randomized, double-blind clinical trial in 20 subjects with usual indication for intravitreal aflibercept injection 48 hours before vitrectomy to treat complications of diabetic retinopathy. They will be divided into 2 groups: Control group - 10 eyes of 10 patients, in which the syringe used for injection will not be shaken at all. Agitation group - 10 eyes of 10 patients undergoing injection, in which the used syringe will be flicked. Immediately prior to injection and also on the day of vitrectomy, the presence of anterior chamber inflammation will be assessed by slit lamp examination. Aqueous humor samples (100 µL) will be collected in the same act of intravitreal injection and vitrectomy, being frozen for further processing. By Cytometric Bead Assay (CBA) technique, the following cytokines will be evaluated: interleukin 8 (IL-8), IL-1 beta, IL-6, IL-10, TNF and IL-12p70, using the human inflammatory cytokine kit. Statistical analysis will be performed to compare the variables before and after the intervention, as well as between the 2 groups at different times.

**Results:** 13 patients have already been included, 6 from the flicking group and 7 from the non-flicking group. To date, 4 (66%) patients in the flicking group had clinically identifiable inflammation, while in the non-flicking group only 1 (16%) patient had mild anterior chamber reaction. The biochemical results will only be processed after the collection of all patients for further elucidation of the cytokines involved in the process.

**Conclusion:** In progress

**Keywords:** Intravitreal Injections, uveitis, syringes, cytokine

## 2019 Research Days Abstract Form

### 2. SCIENTIFIC SECTION PREFERENCE (REQUIRED):

Review the Scientific Section Descriptions. Select and enter the two-letter Code for the one (1) Section best suited to review your abstract.

**(RE) RETINA AND VITREOUS**

### 3. PRESENTATION PREFERENCE (REQUIRED)

Check one:

**(RE) RETINA AND VITREOUS**

4. The signature of the First (Presenting) Author (REQUIRED) acting as the authorized agent for all authors, hereby certifies that any research reported was conducted in compliance with the Declaration of Helsinki and the "UNIFESP Ethical Committee"

### Scientific Section Descriptions (two-letter code):

(BE) OCULAR BIOENGINEERING  
(CO) CORNEA AND EXTERNAL DISEASE  
(CA) CATARACT  
(EF) ELECTROPHYSIOLOGY  
(EP) EPIDEMIOLOGY  
(EX) EXPERIMENTAL SURGERY  
(GL) GLAUCOMA  
(LA) LABORATORY  
(LS) LACRIMAL SYSTEM  
(LV) LOW VISION  
(NO) NEURO-OPHTHALMOLOGY  
(OR) ORBIT  
(PL) OCULAR PLASTIC SURGERY  
(PH) PHARMACOLOGY  
(RE) RETINA AND VITREOUS  
(RS) REFRACTIVE SURGERY  
(RX) REFRACTION-CONTACT LENSES  
(ST) STRABISMUS  
(TR) TRAUMA  
(TU) TUMORS AND PATHOLOGY  
(UV) UVEITIS  
(US) OCULAR ULTRASOUND

Deadline: 10/2019

### FORMAT:

#### Abstract should contain:

Title  
Author  
Co-authors (maximum 6)  
Purpose  
Methods  
Results  
Conclusion  
Keywords

Poster guidelines:  
**90cm x 120cm**

### FIRST (PRESENTING) AUTHOR (REQUIRED):

**Name:** Mariana Matioli Da Palma - PG1 - DO  
**e-mail:** marimatioli@yahoo.com.br  
**CEP Number:** 11.910.071

### 5. ABSTRACT (REQUIRED):

**Title: Inherited retinal dystrophies associated with syndromes**

**Author and Co-authors:** Mariana Matioli da Palma, Fabiana Louise Motta, Mariana Vallim Salles, Juliana Maria Ferraz Sallum

**Purpose:** To access the ophthalmological syndromes in patients who have inherited retinal dystrophies (IRD). IRD is a group of ocular diseases marked by high clinical and genetic heterogeneity affecting about 1 in every 2,000 to 3,000 individuals. IRD is a group of rare disease. A rare disease is a health condition that affects up to 65 people per 100,000 individuals or 1.3 per 2,000 people, according to the World Health Organization. It is estimated that in Brazil, with a population of approximately 210 million people, there are at least 70,000 Brazilians with IRD. They may or may not be associated with syndromic conditions, with alterations in several organs besides the ocular and may even be classified as ultra-rare (less than or equal to 1: 50,000 inhabitants).

**Methods:** This is a retrospective study of patients who had IRD associated with syndromes between 1998 and 2018 and positive genetic test from the Federal University of São Paulo and the Institute of Ocular Genetics. From a database of 1,246 patients with IRD 559 undergone different commercial genetic tests. A number of 159 genetic tests were inconclusive or negative. From a total of 400 patients with IRD who had positive genetic tests, a retrospective evaluation of medical records found 52 patients with IRD associated with syndromic conditions. The inherited ophthalmological syndromes found were analyzed.

**Results:** Ophthalmological syndromes accounted for 13% of all patients with IRD and conclusive genetic test (52 patients out of 400). Genotyping and ophthalmic syndromes found include: PRPS1: Arts Syndrome (1 patient), CNNM4: Jalili Syndrome (1), WFS1: Wolfram Syndrome (1), TUBGCP4: Microcephaly and chorioretinopathy type 3 (1), ABHD12: Polyneuropathy, hearing loss, ataxia, retinitis pigmentosa, and cataract - PHARC (1), ALMS1: Alström Syndrome (2), NDP: Norrie's Disease (2), IQCB1 and NPHP4: Senior-Loken (2), CLN3: Ceroid neuronal lipofuscinosis (8), BBS1: Bardet-Biedl (6), AHI1, CEP290 and INPP5E: Joubert Syndrome (7) and ABDH12, CLRN1, MYO7A and USH2A: Usher Syndrome (20).

**Conclusion:** Most of these syndromes are so rare that they can be underdiagnosed. Only Bardet-Biedl and Usher Syndrome fall into the classification of rare diseases, and the rest of the syndromes found are ultra-rare. It is essential to study inherited ophthalmological syndromes, as many of them are debilitating. The correct early diagnosis, combined with the molecular test can provide the best interdisciplinary treatment.

**Keywords:** retinal dystrophies, syndrome, rare disease

## 2019 Research Days Abstract Form

### 2. SCIENTIFIC SECTION PREFERENCE (REQUIRED):

Review the Scientific Section Descriptions. Select and enter the two-letter Code for the one (1) Section best suited to review your abstract.

**(RE) RETINA AND VITREOUS**

### 3. PRESENTATION PREFERENCE (REQUIRED)

Check one:

**(RE) RETINA AND VITREOUS**

4. The signature of the First (Presenting) Author (REQUIRED) acting as the authorized agent for all authors, hereby certifies that any research reported was conducted in compliance with the Declaration of Helsinki and the "UNIFESP Ethical Committee"

### Scientific Section Descriptions (two-letter code):

(BE) OCULAR BIOENGINEERING  
(CO) CORNEA AND EXTERNAL DISEASE  
(CA) CATARACT  
(EF) ELECTROPHYSIOLOGY  
(EP) EPIDEMIOLOGY  
(EX) EXPERIMENTAL SURGERY  
(GL) GLAUCOMA  
(LA) LABORATORY  
(LS) LACRIMAL SYSTEM  
(LV) LOW VISION  
(NO) NEURO-OPHTHALMOLOGY  
(OR) ORBIT  
(PL) OCULAR PLASTIC SURGERY  
(PH) PHARMACOLOGY  
(RE) RETINA AND VITREOUS  
(RS) REFRACTIVE SURGERY  
(RX) REFRACTION-CONTACT LENSES  
(ST) STRABISMUS  
(TR) TRAUMA  
(TU) TUMORS AND PATHOLOGY  
(UV) UVEITIS  
(US) OCULAR ULTRASOUND

Deadline: 10/2019

### FORMAT:

#### Abstract should contain:

Title  
Author  
Co-authors (maximum 6)  
Purpose  
Methods  
Results  
Conclusion  
Keywords

Poster guidelines:  
**90cm x 120cm**

### FIRST (PRESENTING) AUTHOR (REQUIRED):

**Name:** Vinicius Ferreira Kniggendorf - PG1 - DO  
**e-mail:** vinicius\_kdorf@yahoo.com.br  
**CEP Number:** 572612071

### 5. ABSTRACT (REQUIRED):

#### **Title: Prospection of new anti-angiogenic drugs based on chemically modified heparins**

**Author and Co-authors:** Vinicius Kniggendorf, Thatiane Russo, Maria Eduarda P. Sousa, Juliana Dreyfuss, Caio Regatieri

**Purpose:** Angiogenesis is the formation of new blood vessels from preexisting vasculature. Pathologic angiogenesis in the eye lead to severe visual impairment and affect the quality of life. The search for emerging therapies to treat neovascularization pointed chemically modified heparins (mHep) as good target, since in vitro studies demonstrated anti-angiogenic, anti-proliferative, anti-adhesive and anti-migratory effects on endothelial cells and no effects on ARPE-19 retinal cells viability. The purpose of this study is investigate the anti-angiogenic effect of chemically modified heparins (mHep) in vivo using a model of laser induced choroidal neovascularization in rats.

**Methods:** N-desulfated Re-N-acetylated (N-DRN) with no anti-coagulant or hemorrhagic effects was the mHEP used in vivo study. Choroidal neovascularization was induced in rats (28 eyes) with laser (532nm Green Argon Laser). Four lesions, located at the 3, 6, 9 and 12 o'clock meridians centered on the optic nerve, were created using a power of 150 mW, spot size of 100 µm and duration of 100 ms. Immediately after the laser, the rats were injected with N-DRN using a microsyringe. They were assigned to experimental groups according to the dose: 100 ng/ml, 1000 ng/ml and balanced salt solution (control). Euthanasia was performed 14 days after laser, eyes were enucleated and prepared for immunofluorescence with anti-Von Willebrand factor and anti-Goat (Alexa 488). After confocal microscope analysis, the neovascular membrane was measured with ImageJ.

**Results:** The mean neovascular membrane area was 70.532.264 unit of length (µl) in control group, 56.667.680µl in group 100ng/ml and 58.776.730µl in group 1000ng/ml. The area analysis demonstrated a significant difference between groups, the mean difference in control versus 100ng/ml was 13.864.584µl (p=0.006), while control and 1000ng/ml was 11.755.534µl (p=0.031). The perimeter was also analyzed, the mean difference was 84560µl in control vs 100ng/ml (p= 0.035), while control vs 1000ng/ml difference was 77748µl (p=0.07). No statistical difference was observed in neovascular membrane density (p=0.83)

**Conclusion:** In vivo studies, using choroidal neovascularization models, demonstrated that N-desulfated Re-N-acetylated mHEP is a potential drug to treat ocular angiogenesis.

**Keywords:** Angiogenesis, new therapies, modified heparins



## 2019 Research Days Abstract Form

### 2. SCIENTIFIC SECTION PREFERENCE (REQUIRED):

Review the Scientific Section Descriptions. Select and enter the two-letter Code for the one (1) Section best suited to review your abstract.

**(RE) RETINA AND VITREOUS**

### 3. PRESENTATION PREFERENCE (REQUIRED)

Check one:

**(RE) RETINA AND VITREOUS**

4. The signature of the First (Presenting) Author (REQUIRED) acting as the authorized agent for all authors, hereby certifies that any research reported was conducted in compliance with the Declaration of Helsinki and the "UNIFESP Ethical Committee"

### Scientific Section Descriptions (two-letter code):

(BE) OCULAR BIOENGINEERING  
(CO) CORNEA AND EXTERNAL DISEASE  
(CA) CATARACT  
(EF) ELECTROPHYSIOLOGY  
(EP) EPIDEMIOLOGY  
(EX) EXPERIMENTAL SURGERY  
(GL) GLAUCOMA  
(LA) LABORATORY  
(LS) LACRIMAL SYSTEM  
(LV) LOW VISION  
(NO) NEURO-OPHTHALMOLOGY  
(OR) ORBIT  
(PL) OCULAR PLASTIC SURGERY  
(PH) PHARMACOLOGY  
(RE) RETINA AND VITREOUS  
(RS) REFRACTIVE SURGERY  
(RX) REFRACTION-CONTACT LENSES  
(ST) STRABISMUS  
(TR) TRAUMA  
(TU) TUMORS AND PATHOLOGY  
(UV) UVEITIS  
(US) OCULAR ULTRASOUND

Deadline: 10/2019

### FORMAT:

#### Abstract should contain:

Title  
Author  
Co-authors (maximum 6)  
Purpose  
Methods  
Results  
Conclusion  
Keywords

Poster guidelines:  
**90cm x 120cm**

### FIRST (PRESENTING) AUTHOR (REQUIRED):

**Name:** Gustavo Barreto de Melo - Post-doc  
**e-mail:** gustavobmelo@yahoo.com.br  
**CEP Number:** 266031031

### 5. ABSTRACT (REQUIRED):

#### Title: Mishandling of syringes and the risks to the eye

**Author and Co-authors:** Gustavo B Melo, Celso S Dias Jr, Alexandre L Cardoso, Ana G Figueiredo, Fábio B Morais, Geoffrey G Emerson, Shoko Ota, Eduardo B Rodrigues, Michel E Farah, Rubens Belfort Jr, Acacio A S Lima Filho, Mauricio Maia

**Purpose:** Syringes have an off-label use in more than 25 million intravitreal injections (IVI) performed annually worldwide. The objective of this study was to investigate whether syringe mishandling might increase the release of silicone oil droplets into the vitreous, and thereby increase the risk of noninfectious inflammation (NII) after intravitreal injection.

**Methods:** Six models of syringes (Descarpack 1mL, Solidor 1mL, Injex Stilly Line 0.5mL, BD Ultra Fine II 0.5mL, SR 1mL and BD Plastipak 1mL) were analyzed by light microscopy for the release of silicone oil under agitation (n=10 for each model) and compared with no agitation (n=10). Fourier-Transform Infrared Spectroscopy (FTIR) was performed to identify the molecular compounds inside the syringes. Additionally, a cross-sectional study was carried out in subjects undergoing routine IVI and controls to detect silicone oil in the vitreous by biomicroscopy and ultrasonography. The third arm of the study analyzed which syringe, and its handling technique, was associated with a case series of NII after aflibercept IVI.

**Results:** One hundred and twenty syringes were analyzed. Agitation by flicking caused a significant increase in the number of positive samples for silicone oil as well as in the number of oil droplets in comparison to no agitation. FTIR identified the presence of polysiloxane (silicone oil) in all models. The clinical study included 30 control eyes and 37 previously treated with at least 3 IVI. Biomicroscopy and ultrasonography, respectively, found silicone oil droplets in 68% and 76% of treated and 0% and 3% of controls. In the series of 6 cases with NII, a statistically significant association was found with the SR 1 mL syringe, which was found to release silicone oil. Additionally, flicking the syringe was a common step performed by the retina specialist in these cases.

**Conclusion:** Silicone oil droplets are common in the vitreous after intravitreal injection, and agitation of syringes prior to injection tends to release more silicone oil. The case series reported herein was associated with a single syringe model that releases silicone oil and had been flicked prior to injection. Although it is common among retina specialists to flick the syringe to reduce air bubbles prior to injection, such agitation of the syringe might increase the complications of IVI, namely silicone oil droplets and inflammation.

**Keywords:** Inflammation; intravitreal injection, silicone oil, syringe

## 2019 Research Days Abstract Form

### 2. SCIENTIFIC SECTION PREFERENCE (REQUIRED):

Review the Scientific Section Descriptions. Select and enter the two-letter Code for the one (1) Section best suited to review your abstract.

**(RE) RETINA AND VITREOUS**

### 3. PRESENTATION PREFERENCE (REQUIRED) Check one:

**(RE) RETINA AND VITREOUS**

4. The signature of the First (Presenting) Author (REQUIRED) acting as the authorized agent for all authors, hereby certifies that any research reported was conducted in compliance with the Declaration of Helsinki and the "UNIFESP Ethical Committee"

### Scientific Section Descriptions (two-letter code):

(BE) OCULAR BIOENGINEERING  
(CO) CORNEA AND EXTERNAL DISEASE  
(CA) CATARACT  
(EF) ELECTROPHYSIOLOGY  
(EP) EPIDEMIOLOGY  
(EX) EXPERIMENTAL SURGERY  
(GL) GLAUCOMA  
(LA) LABORATORY  
(LS) LACRIMAL SYSTEM  
(LV) LOW VISION  
(NO) NEURO-OPHTHALMOLOGY  
(OR) ORBIT  
(PL) OCULAR PLASTIC SURGERY  
(PH) PHARMACOLOGY  
(RE) RETINA AND VITREOUS  
(RS) REFRACTIVE SURGERY  
(RX) REFRACTION-CONTACT LENSES  
(ST) STRABISMUS  
(TR) TRAUMA  
(TU) TUMORS AND PATHOLOGY  
(UV) UVEITIS  
(US) OCULAR ULTRASOUND

Deadline: 10/2019

### FORMAT:

#### Abstract should contain:

Title  
Author  
Co-authors (maximum 6)  
Purpose  
Methods  
Results  
Conclusion  
Keywords

Poster guidelines:  
**90cm x 120cm**

### FIRST (PRESENTING) AUTHOR (REQUIRED):

**Name:** Marina Roizenblatt - PG1 - DO  
**e-mail:** maroizenb@gmail.com  
**CEP Number:** 0464/2017

### 5. ABSTRACT (REQUIRED):

**Title: THE ISOLATED AND COMBINED INFLUENCE OF WEIGHT-ADJUSTED COFFEE AND PROPRANOLOL INTAKE ON RETINAL FELLOWS SIMULATED SURGICAL SKILLS**

**Author and Co-authors:** Roizenblatt M, Gomes VD, Grupenmacher AT, Muralha F, Faber J, Jiramongkolchai K, Gehlbach PL, Farah ME, Belfort Jr. R, Maia M.

**Purpose:** While beta-blockers have been studied for their effects on decreasing anxiety and hand tremor, caffeine ingestion may impair microsurgical performance. The present study sought to objectively analyze the individual performance of novice retinal surgeons when exposed to different weight-adjusted dosing of coffee and beta-blocker in isolated or combined regimens.

**Methods:** We analyzed the performance of 15 surgeons, with less than 2 years of surgical practice, using the simulator Eyesi®. Surgical skills were assessed on 2 non-sequential days, 30-60 minutes after the blindly ingestion of placebo, caffeine, or propranolol pills. On the first day, the subjects ingested placebo, followed by 2.5mg/kg of caffeine, then an additional dose of 2.5mg/kg of coffee (totalizing 5mg/kg), and finally a neutralizing dose of propranolol 0.6mg/kg. On the second day, the initial intake of placebo was followed by 0.2mg/kg of propranolol, an additional dose of 0.4mg/kg of propranolol (totalizing 0.6mg/kg) and then the neutralizing ingestion of 5mg/kg of caffeine. The main outcomes evaluated were score, time to complete the task, and odometer. Nonparametric Wilcoxon-Mann-Whitney test was used for pairwise comparisons

**Results:** The score was higher after propranolol 0.2mg/kg intake (617±67) compared to caffeine 2.5mg/kg (557±109.25, p=0.0487) and this difference remained in the comparison between propranolol 0.6mg/kg (608±54.75) vs. coffee 5mg/kg (529±72, p=0.0014). After exposure to the neutralizing drug, the difference in scores between groups was no longer detected. Regarding the time (milliseconds x10.000), participants performed faster after ingestion of 0.6mg/kg of propranolol (7.37±1.40) compared to coffee 5mg/kg (8.84±1.90, p=0.01) and this difference was also no longer detected after the neutralizing dose. Finally, the surgical tool trajectory extent inside the eye (?m) was shorter after 0.6mg/kg (2101.9±538.75) propranolol intake as compared to 5mg/kg of coffee (2566.3±534.89, p=0.03), with no difference between groups after the neutralizing dose.

**Conclusion:** The ingestion of 0.2mg/kg of propranolol was associated with an improvement in surgical performance when compared to the 2.5mg/kg of caffeine among novice surgeons. However, exposure dose required to change task time and odometer was higher (0.6mg/kg of propranolol and 5mg/kg of coffee).

**Keywords:** Coffee, Propranolol, Retinal surgery, Eyesi.

## 2019 Research Days Abstract Form

### 2. SCIENTIFIC SECTION PREFERENCE (REQUIRED):

Review the Scientific Section Descriptions. Select and enter the two-letter Code for the one (1) Section best suited to review your abstract.

**(RE) RETINA AND VITREOUS**

### 3. PRESENTATION PREFERENCE (REQUIRED)

Check one:

**(RE) RETINA AND VITREOUS**

4. The signature of the First (Presenting) Author (REQUIRED) acting as the authorized agent for all authors, hereby certifies that any research reported was conducted in compliance with the Declaration of Helsinki and the "UNIFESP Ethical Committee"

### Scientific Section Descriptions (two-letter code):

(BE) OCULAR BIOENGINEERING  
(CO) CORNEA AND EXTERNAL DISEASE  
(CA) CATARACT  
(EF) ELECTROPHYSIOLOGY  
(EP) EPIDEMIOLOGY  
(EX) EXPERIMENTAL SURGERY  
(GL) GLAUCOMA  
(LA) LABORATORY  
(LS) LACRIMAL SYSTEM  
(LV) LOW VISION  
(NO) NEURO-OPHTHALMOLOGY  
(OR) ORBIT  
(PL) OCULAR PLASTIC SURGERY  
(PH) PHARMACOLOGY  
(RE) RETINA AND VITREOUS  
(RS) REFRACTIVE SURGERY  
(RX) REFRACTION-CONTACT LENSES  
(ST) STRABISMUS  
(TR) TRAUMA  
(TU) TUMORS AND PATHOLOGY  
(UV) UVEITIS  
(US) OCULAR ULTRASOUND

Deadline: 10/2019

### FORMAT:

#### Abstract should contain:

Title  
Author  
Co-authors (maximum 6)  
Purpose  
Methods  
Results  
Conclusion  
Keywords

Poster guidelines:  
**90cm x 120cm**

### FIRST (PRESENTING) AUTHOR (REQUIRED):

**Name:** Oswaldo F. M. Brasil Do Amaral - PG1 - DO  
**e-mail:** dicoretina@gmail.com  
**CEP Number:** 98.104

### 5. ABSTRACT (REQUIRED):

**Title: Imaging Analysis of Macular Holes in Optical Coherence Tomography Angiography: Conventional Peeling Versus Inverted Internal Limiting Membrane Flap Technique**

**Author and Co-authors:** Brasil OF, Kawamuro M, Queiroz B, Urias MG, Polizelli MU, Cruz NF, Maia M

**Purpose:** To compare functional, mechanical closure of macular holes (MH) and anatomical success of sutureless combined phacovitrectomy surgery with standard internal limiting membrane (ILM) peeling versus surgery with an ILM flap inversion technique for the management of idiopathic MH, by analyzing OCT Angiography (OCTA) images.

**Methods:** A retrospective selection of patients presenting with idiopathic full-thickness MH who underwent vitreoretinal surgery were included in this study. Complete ophthalmologic examination, age, visual acuity pre and post operatively, size of the initial MH were assessed. OCTA 3.0 x 3.0 scan was performed post operatively. The angiography of the outer layer was analyzed separately. The software ImageJ adjusted the image by an auto threshold with the method of Otsu binarization.

**Results:** Twelve eyes of 10 patients who had MH surgery, either with conventional peeling (5) or inverted internal limiting membrane flap (7), were included. In the total area (3.0 mm x 3.0 mm), the percentage of black pixels ranged from 79,09% to 81,12%, and the percentage of white pixels ranged from 18,88% to 20,91%, in the peeling group. In the inverted flap group, the black pixels percentage were 73,88% to 82,22%, and the white percentage were 17,78% to 26,12%. In the central circle of 1.5 mm of diameter, the percentage of black pixels ranged from 81,14% to 86,54% in the peeling group. As for the inverted flap group, this percentage ranged from 75,25% to 91,19%. With a central circle of 0.5 mm of diameter, the percentage of white pixels ranged from 7,22% to 15,74% in the peeling group. The inverted flap group had a range of 3,65% to 17,95%. The initial visual acuity in the peeling group ranged from 0,6 to 0,9 logMAR, and the post-surgery visual acuity from 0,1 to 0,5 logMAR. The initial BCVA in the inverted flap group ranged from 0,7 to 1,6 logMAR, and the final BCVA from 0,5 to 1,6.

**Conclusion:** Our study created a method of imaging analysis to separate white and black pixels, hypothesizing that the white pixels corresponded to signal of flow, or even viable cellularity post-surgery.

**Keywords:** OCT Angiography, Macular Hole, ImageJ

## 2019 Research Days Abstract Form

### 2. SCIENTIFIC SECTION PREFERENCE (REQUIRED):

Review the Scientific Section Descriptions. Select and enter the two-letter Code for the one (1) Section best suited to review your abstract.

**(RE) RETINA AND VITREOUS**

### 3. PRESENTATION PREFERENCE (REQUIRED)

Check one:

**(RE) RETINA AND VITREOUS**

4. The signature of the First (Presenting) Author (REQUIRED) acting as the authorized agent for all authors, hereby certifies that any research reported was conducted in compliance with the Declaration of Helsinki and the "UNIFESP Ethical Committee"

### Scientific Section Descriptions (two-letter code):

(BE) OCULAR BIOENGINEERING  
(CO) CORNEA AND EXTERNAL DISEASE  
(CA) CATARACT  
(EF) ELECTROPHYSIOLOGY  
(EP) EPIDEMIOLOGY  
(EX) EXPERIMENTAL SURGERY  
(GL) GLAUCOMA  
(LA) LABORATORY  
(LS) LACRIMAL SYSTEM  
(LV) LOW VISION  
(NO) NEURO-OPHTHALMOLOGY  
(OR) ORBIT  
(PL) OCULAR PLASTIC SURGERY  
(PH) PHARMACOLOGY  
(RE) RETINA AND VITREOUS  
(RS) REFRACTIVE SURGERY  
(RX) REFRACTION-CONTACT LENSES  
(ST) STRABISMUS  
(TR) TRAUMA  
(TU) TUMORS AND PATHOLOGY  
(UV) UVEITIS  
(US) OCULAR ULTRASOUND

Deadline: 10/2019

### FORMAT:

#### Abstract should contain:

Title  
Author  
Co-authors (maximum 6)  
Purpose  
Methods  
Results  
Conclusion  
Keywords

Poster guidelines:  
**90cm x 120cm**

### FIRST (PRESENTING) AUTHOR (REQUIRED):

**Name:** Renato Menezes Palácio - PG1 - DO  
**e-mail:** renatopalacios@hotmail.com  
**CEP Number:** 2.423.404

### 5. ABSTRACT (REQUIRED):

#### **Title: Clinical Study on the Initial Experiences of French Vitreoretinal Surgeons with Heads-up Surgery**

**Author and Co-authors:** RENATO MENEZES PALÁCIOS, MD,1,2 KIM VIEIRA KAYAT, MD,1,2 CHRISTOPHE MOREL, MD,1 JOHN CONRATH, MD, PHD,1 FRÉDÉRIC MATONTI, MD, PHD,1 BRUNO MORIN, MD,1 MICHEL EID FARAH, MD, PHD,2 FRANÇOIS DEVIN, MD.1 1. From the Department of Ophthalmology-Retina, Centre Monticelli Paradis d'Ophthalmologie, Marse

**Purpose:** To evaluate the initial experience of four experienced vitreoretinal surgeons, in France, with a three-dimensional (3-D) system, and to explore the potential advantages and disadvantages of this technology. We also report anatomical surgical outcomes of full-thickness idiopathic macular holes (MH) and primary rhegmatogenous retinal detachment (RRD), by using traditional microscopy and heads-up method.

**Methods:** Four French retinal surgeons performed several types of ophthalmic surgeries with this new technology. To compare the 3-D with ocular viewing, ergonomics, educational value, image sharpness, depth perception, field of view, technical feasibility, advantages and disadvantages, and expectations for the future, were assessed using a questionnaire. We also compared the same questionnaire with the answers of six Brazilian experienced vitreoretinal surgeons. For treating MHs, the surgeons performed 88 surgeries (44 with microscopy and 44 with 3-D). They performed 100 PPV for treating primary RRD (50 with ocular viewing and 50 with 3-D). The visualization method for each patient and the assignment of each surgeon for a specific patient were all randomly selected.

**Results:** On the questionnaire, 3-D was preferred to microscopy, except for technical feasibility, the type of surgery benefitting most from the 3-D was macula surgery and the worst was SB and secondary IOL fixation, the most used by all is the black and white filter in patients with atrophic RPE during ILM peeling. Eighty-one (92.1%) MHs were successfully closed with one surgery and out of the 100 eyes with a primary RRD, the anatomical success after 3 months of follow-up was 91%, with no statistical significance between 3-D and ocular viewing.

**Conclusion:** The surgeons in this study preferred 3-D to ocular viewing. Vitrectomy surgery to treat MHs and RRDs can be performed using the 3-D with the same efficiency as microscopy. Digital integration of 3-D and iOCT can be useful in some cases.

**Keywords:** Heads-up; 3-D; microscopy; digital integration; color filters; RRD; MH.

## 2019 Research Days Abstract Form

### 2. SCIENTIFIC SECTION PREFERENCE (REQUIRED):

Review the Scientific Section Descriptions. Select and enter the two-letter Code for the one (1) Section best suited to review your abstract.

**(CO) CORNEA AND EXTERNAL DISEASE**

### 3. PRESENTATION PREFERENCE (REQUIRED)

Check one:

**(CO) CORNEA AND EXTERNAL DISEASE**

4. The signature of the First (Presenting) Author (REQUIRED) acting as the authorized agent for all authors, hereby certifies that any research reported was conducted in compliance with the Declaration of Helsinki and the "UNIFESP Ethical Committee"

### Scientific Section Descriptions (two-letter code):

(BE) OCULAR BIOENGINEERING  
(CO) CORNEA AND EXTERNAL DISEASE  
(CA) CATARACT  
(EF) ELECTROPHYSIOLOGY  
(EP) EPIDEMIOLOGY  
(EX) EXPERIMENTAL SURGERY  
(GL) GLAUCOMA  
(LA) LABORATORY  
(LS) LACRIMAL SYSTEM  
(LV) LOW VISION  
(NO) NEURO-OPHTHALMOLOGY  
(OR) ORBIT  
(PL) OCULAR PLASTIC SURGERY  
(PH) PHARMACOLOGY  
(RE) RETINA AND VITREOUS  
(RS) REFRACTIVE SURGERY  
(RX) REFRACTION-CONTACT LENSES  
(ST) STRABISMUS  
(TR) TRAUMA  
(TU) TUMORS AND PATHOLOGY  
(UV) UVEITIS  
(US) OCULAR ULTRASOUND

Deadline: 10/2019

### FORMAT:

#### Abstract should contain:

Title  
Author  
Co-authors (maximum 6)  
Purpose  
Methods  
Results  
Conclusion  
Keywords

Poster guidelines:  
**90cm x 120cm**

### FIRST (PRESENTING) AUTHOR (REQUIRED):

**Name:** Fábio Mendonça Xavier Andrade - PG0 - DO  
**e-mail:** fabio16.xavier@gmail.com  
**CEP Number:** 1.071.387

### 5. ABSTRACT (REQUIRED):

#### **Title: Ocular surface changes in the treatment of Rosacea: comparison between low-dose oral isotretinoin and doxycycline**

**Author and Co-authors:** FABIO MENDONCA XAVIER ANDRADE FABIOLA ROSA PICOSSE LAURA PIRES DA CUNHA CAMILA MAIA VALENTE FERNANDA MACHADO BEZERRA HELIO MIOT EDILEIA BAGATIN DENISE DE FREITAS

**Purpose:** To compare the ocular impact between systemic treatment with doxycycline and low-dose oral isotretinoin on patients with moderate to severe papulopustular rosacea

**Methods:** Patients were randomized to receive either isotretinoin 0,3 to 0,4 mg/kg (group A) or doxycycline 100mg/day (group B) for 16 weeks. Ocular symptoms were searched and then an evaluation including best corrected visual acuity (BCVA), Schirmer's test, break-up-time (BUT), rose bengal staining score and meibomian gland dysfunction (MGD) grading was performed and repeated after treatment was completed.

**Results:** 39 patients (30 females and 9 males) were included. BCVA was >20/30 in more than 90% of patients in both groups and did not alter with treatment. Improvement in ocular symptoms and MGD were seen more in group B after treatment with  $p' < 0,05$ . Other parameters did not reach statistical relevance.

**Conclusion:** Doxycycline improves MGD, ocular symptoms and ocular surface in patients with rosacea. Despite worsening MGD and symptoms in some patients, low-dose isotretinoin did not produce serious complications in any of the subjects.

**Keywords:** rosacea, Doxycycline, isotretinoin, ocular surface ? Blepharitis

## 2019 Research Days Abstract Form

### 2. SCIENTIFIC SECTION PREFERENCE (REQUIRED):

Review the Scientific Section Descriptions. Select and enter the two-letter Code for the one (1) Section best suited to review your abstract.

**(CO) CORNEA AND EXTERNAL DISEASE**

### 3. PRESENTATION PREFERENCE (REQUIRED)

Check one:

**(CO) CORNEA AND EXTERNAL DISEASE**

4. The signature of the First (Presenting) Author (REQUIRED) acting as the authorized agent for all authors, hereby certifies that any research reported was conducted in compliance with the Declaration of Helsinki and the "UNIFESP Ethical Committee"

### Scientific Section Descriptions (two-letter code):

(BE) OCULAR BIOENGINEERING  
(CO) CORNEA AND EXTERNAL DISEASE  
(CA) CATARACT  
(EF) ELECTROPHYSIOLOGY  
(EP) EPIDEMIOLOGY  
(EX) EXPERIMENTAL SURGERY  
(GL) GLAUCOMA  
(LA) LABORATORY  
(LS) LACRIMAL SYSTEM  
(LV) LOW VISION  
(NO) NEURO-OPHTHALMOLOGY  
(OR) ORBIT  
(PL) OCULAR PLASTIC SURGERY  
(PH) PHARMACOLOGY  
(RE) RETINA AND VITREOUS  
(RS) REFRACTIVE SURGERY  
(RX) REFRACTION-CONTACT LENSES  
(ST) STRABISMUS  
(TR) TRAUMA  
(TU) TUMORS AND PATHOLOGY  
(UV) UVEITIS  
(US) OCULAR ULTRASOUND

Deadline: 10/2019

### FORMAT:

#### Abstract should contain:

Title  
Author  
Co-authors (maximum 6)  
Purpose  
Methods  
Results  
Conclusion  
Keywords

Poster guidelines:  
**90cm x 120cm**

### FIRST (PRESENTING) AUTHOR (REQUIRED):

**Name:** Murilo Bertazzo Peres - PG0 - DO  
**e-mail:** murilobp@gmail.com  
**CEP Number:** 3.138.888

### 5. ABSTRACT (REQUIRED):

**Title: Macromolecular changes in the extracellular matrix of human corneas with keratoconus and after crosslinking with açai (Euterpe oleracea) extract: an ex vivo and in vitro study**

**Author and Co-authors:** Murilo B Peres, Letícia L. Ettinger, Renan P Cavaleiro, Vitor G L da Silva, Yara M C S Michelacci Mauro S Q Campos.

**Purpose:** To analyze changes in the composition of the extracellular matrix of keratoconus corneal stroma, compared to normal corneas. To study the effects in vitro effects of cornea crosslinking with açai extract.

**Methods:** Nine keratoconus(KC) corneas from penetrating corneal transplantation and 5 normal corneas(NC) for control from eye bank discards were selected. Macromolecule extraction was performed and then agarose gel electrophoresis, SDS polyacrylamide gel electrophoresis, Western blotting (WB), protein dosing and ELISA quantification. The corneas were also prepared for immunofluorescence analysis under confocal microscopy. The proteoglycans of the SLRP family decorin and lumican, keratan sulfate (KS) glycosaminoglycan, metalloproteases MMP2, MMP9 and MMP13 and cathepsins B and L were analyzed. To analyze the action of açai extract, type I collagen discs (gelatin 24% in PBS) were incubated overnight with different concentrations of açai extract (2.2%, 4.4%, 8.8%, 17.5 % and 35%), and alternatively with 30% ethanol açai extract solution in BSS, BSS was used for control. After washing and incubation with collagenase, we measured the disc weight variation at different times.

**Results:** In the 5 NC WB detected lumican, decorin and KS. Comparing 2 NC with 2 KC, we observed that decorin in KC has a higher molecular weight, indicating a higher degree of glycosylation. No differences were observed in lumican and KS in both. MMP13 was seen in KC and was absent in NC. MMP2, MMP9, Cathepsin B and L were not detected in both. The average total protein dosage was  $267.5 \pm 225\mu\text{g}$  for NC and  $102.0 \pm 140\mu\text{g}$  for KC. Lumican, decorin and KS were quantified by ELISA. For Lumican and decorin concentrations were expressed as a ration between KC and NC, due to the lack of a standard proteoglycan with a known concentration. The ratio of decorin concentration was  $0.86 \pm 0.42$ , lumican was  $0.85 \pm 0.40$ . The mean KS concentration was 2212.1 ng/mg of wet weight tissue in NC, and 2291 ng/mg in KC, with a ratio of 1.04. In 3 of the cases of KC, concentrations of decorin, lumican and KS were decreased compared to normal (<'50%), in 2 other cases were increased (120 and 150%), and in 4 cases were similar to normal. Immunofluorescence under confocal microscopy shows that all these compounds are located in the stroma, with no differences between NC and KC. Collagen discs incubated with higher concentrations of açai extract became more resistant to collagenase action, indicating that crosslinking occurred. It seems that ethanol made no difference except for the control.

**Conclusion:** The presence of decorin, lumican and KS in the stroma of NC and KC was demonstrated both by quantitative (ELISA and protein dosing) and qualitative analysis (western blotting and immunofluorescence). The KC decorin is more glycosylated than that of normal (western blotting). There were no statistically significant differences in decorin, lumican and KS concentrations of keratoconus corneas compared with normal ones. The number of samples should be increased. MMP13 was detected by western blotting in the cornea with keratoconus. In vitro treatment with açai extract increased collagen resistance to collagenase enzyme digestion, showing that the açai extract may contains crosslinking inducing molecules.

**Keywords:** cornea, proteoglycans, cross-linking corneal, keratoconus, elisa, western blotting, açai, Euterpe oleracea

## 2019 Research Days Abstract Form

### 2. SCIENTIFIC SECTION PREFERENCE (REQUIRED):

Review the Scientific Section Descriptions. Select and enter the two-letter Code for the one (1) Section best suited to review your abstract.

**(CO) CORNEA AND EXTERNAL DISEASE**

### 3. PRESENTATION PREFERENCE (REQUIRED)

Check one:

**(CO) CORNEA AND EXTERNAL DISEASE**

4. The signature of the First (Presenting) Author (REQUIRED) acting as the authorized agent for all authors, hereby certifies that any research reported was conducted in compliance with the Declaration of Helsinki and the "UNIFESP Ethical Committee"

### Scientific Section Descriptions (two-letter code):

(BE) OCULAR BIOENGINEERING  
(CO) CORNEA AND EXTERNAL DISEASE  
(CA) CATARACT  
(EF) ELECTROPHYSIOLOGY  
(EP) EPIDEMIOLOGY  
(EX) EXPERIMENTAL SURGERY  
(GL) GLAUCOMA  
(LA) LABORATORY  
(LS) LACRIMAL SYSTEM  
(LV) LOW VISION  
(NO) NEURO-OPHTHALMOLOGY  
(OR) ORBIT  
(PL) OCULAR PLASTIC SURGERY  
(PH) PHARMACOLOGY  
(RE) RETINA AND VITREOUS  
(RS) REFRACTIVE SURGERY  
(RX) REFRACTION-CONTACT LENSES  
(ST) STRABISMUS  
(TR) TRAUMA  
(TU) TUMORS AND PATHOLOGY  
(UV) UVEITIS  
(US) OCULAR ULTRASOUND

Deadline: 10/2019

### FORMAT:

#### Abstract should contain:

Title  
Author  
Co-authors (maximum 6)  
Purpose  
Methods  
Results  
Conclusion  
Keywords

Poster guidelines:  
**90cm x 120cm**

### FIRST (PRESENTING) AUTHOR (REQUIRED):

**Name:** Alexandre Xavier Da Costa - PG1 - DO  
**e-mail:** dr.alexandre.x@gmail.com  
**CEP Number:** 341706081

### 5. ABSTRACT (REQUIRED):

**Title: Pharmacoeconomic study on the variables regarding the vials of eyedrops and the formation of drops: a search for standardization**

**Author and Co-authors:** Alexandre Xavier da Costa, José Álvaro Pereira Gomes, Vagner Rogério dos Santos

**Purpose:** To produce scientific data regarding the variables related to eye drops and eyedrop bottles in a search for standardization, and its pharmacoeconomic implication.

**Methods:** Four experimental studies were conducted: 1) Drop volume of artificial tear solutions: pharmacoeconomic study - to determine the mean drop volume produced by artificial tear solutions in different inclination angles and to determine the mean cost of the treatment, 2) Definition of methodology to establish a reference pattern of the measure of drop volume of eyedrops - a quality and reliability study 3) Instillation angle impacts microbial cross-contamination of multidose eyedrops - to evaluate the impact of instillation angle and nozzle tip geometry on cross-contamination risk of multidose ocular solution bottles, 4) Dry eye and the performance of ocular lubricants in aircrafts ? to analyze different types of ocular lubricants and their functionality during airplane flights. A fifth study is being developed in order to do a systematic review on the subject of eyedrop standardization.

**Results:** The studies showed that 1) drop volume ranged from 32.2 to 64.0 ?L at 45o and from 29.1 to 65.1 ?L at 90o. The difference between drops in each inclination varied from 2 to 24%. The annual cost was from R\$2,73 to R\$130,73 according to the inclination of the bottle. 2) Among the different manufacturers, significantly different values of mass for a drop with volume of 20?L were recorded. It was encountered a mass variation between the drops from the same product. 3) Bacterial contamination was carried from the outside of the bottles and detected in 53.7% of cultures when drops were administered at 90° and in 70.4% of cultures at 45°. Eyedrops collected from ocular solutions with a rounded nozzle geometry and an instillation angle of 90° transmitted bacteria in 69.4% of cases, while those administered from a sharp nozzle geometry transmitted bacteria in only 22.2% of cases. At an instillation angle of 45°, contamination was identified in 83.3% of bottles with a rounded tip geometry and in only 8 out of 18 bottles (44.4%) from those with a sharp tip geometry. 4) Hyabak® was the only brand tested that showed an erratic, involuntary and irregular efflux of the eye drops when used in an airplane even when the bottle was held upright.

**Conclusion:** Standardization of eyedrop bottles is vital to ensure that topical agents have minimal variation of drops and reliable dosis, minimal contact with the outside of the bottle before reaching patients' eyes to avoid cross-contamination, and similar bottles that will ensure a proper use in different scenarios.

**Keywords:** Eyedrop standardization, Ophthalmic solutions/administration & dosage; Ophthalmic solutions/economic; Medications instillation; Lubricant eyedrops; Pharmacoeconomics

## 2019 Research Days Abstract Form

### 2. SCIENTIFIC SECTION PREFERENCE (REQUIRED):

Review the Scientific Section Descriptions. Select and enter the two-letter Code for the one (1) Section best suited to review your abstract.

**(CO) CORNEA AND EXTERNAL DISEASE**

### 3. PRESENTATION PREFERENCE (REQUIRED)

Check one:

**(CO) CORNEA AND EXTERNAL DISEASE**

4. The signature of the First (Presenting) Author (REQUIRED) acting as the authorized agent for all authors, hereby certifies that any research reported was conducted in compliance with the Declaration of Helsinki and the "UNIFESP Ethical Committee"

### Scientific Section Descriptions (two-letter code):

(BE) OCULAR BIOENGINEERING  
(CO) CORNEA AND EXTERNAL DISEASE  
(CA) CATARACT  
(EF) ELECTROPHYSIOLOGY  
(EP) EPIDEMIOLOGY  
(EX) EXPERIMENTAL SURGERY  
(GL) GLAUCOMA  
(LA) LABORATORY  
(LS) LACRIMAL SYSTEM  
(LV) LOW VISION  
(NO) NEURO-OPHTHALMOLOGY  
(OR) ORBIT  
(PL) OCULAR PLASTIC SURGERY  
(PH) PHARMACOLOGY  
(RE) RETINA AND VITREOUS  
(RS) REFRACTIVE SURGERY  
(RX) REFRACTION-CONTACT LENSES  
(ST) STRABISMUS  
(TR) TRAUMA  
(TU) TUMORS AND PATHOLOGY  
(UV) UVEITIS  
(US) OCULAR ULTRASOUND

Deadline: 10/2019

### FORMAT:

#### Abstract should contain:

Title  
Author  
Co-authors (maximum 6)  
Purpose  
Methods  
Results  
Conclusion  
Keywords

Poster guidelines:  
**90cm x 120cm**

### FIRST (PRESENTING) AUTHOR (REQUIRED):

**Name:** Michelle De Lima Farah Santinello - PG1 - DO  
**e-mail:** milfarah@gmail.com  
**CEP Number:** 4619002

### 5. ABSTRACT (REQUIRED):

#### **Title: NEW TECHNIQUE ? CORNEAL MICRO INFUSION OF DRUGS WITH MICRONEEDLES**

**Author and Co-authors:** Michelle Farah, Samir Arbache, Alex Grupenmacher, Felipe Muralha, Acácio A S Lima Filho, Mauricio Maia and Rubens Belfort Jr

**Purpose:** The purpose of this study is to evaluate the safety profile of therapeutic products using a new system called ocular micro infusion of drugs (OMD) in rabbit's corneas.

**Methods:** In this prospective and experimental study, 4 New Zealand albino rabbits were included. The protocol was approved by the Ethics Committee on animal use (5148221018) of the UNIFESP. Prior to the procedure animals were anesthetized with intramuscular ketamine and xylazine. Topical ocular anesthesia was also applied. An ultrasonic corneal pachymetry was performed to determine the depth of the needling application at 200 microns of the corneal surface. Each rabbit received a different drug in the right eye. Following the protocol /rabbit 1 received 0.02% of biguanide, rabbit 2, triamcinolone 40mg/ml and rabbit 3 bevacizumab 1,25mg. On rabbit 4, a puncture without drugs was performed (control group). Each medication was applied by multiple puncture (touch) in 8 points each of them with 7 micro needles (0.3 mm diameter each). Each application was done in the central cornea and lasted 1 second. The OMD technique consisted in the use of a "Cheyenne" tattoo machine with cartridges - E-MC07-L30L-07x03mm (ANVISA Register: 802 81110015 and 80281110019). Both were manufactured by DERM (Berlin, Germany). The animals were clinically evaluated and photographed on days 1, 10, 20 and 30 after application and also evaluated on days 10 and 20 with optical coherence tomography (OCT) of the anterior segment Visante. After 30 days of the procedure, the animals were euthanized and the eyes submitted to histopathological analysis using Hematoxylin-Eosin (HE) tissue staining.

**Results:** On days 10, 20 and 30 after application, no corneal opacities, infiltrates or inflammatory reaction were observed. The corneas evaluated with histopathology had no vascularization, no inflammatory cells, no ocular perforation and it was possible to determine the micropuncture path. In the evaluated slides it was also possible to observe the presence of intact corneal epithelium in the 4 studied rabbits. On the 10 and 20 day no areas of fibrosis and corneal thickening were seen in the OCT of the anterior segment.

**Conclusion:** The results show that the OMD technique demonstrated in rabbit's cornea was easy to perform and safe since no complications or pathologic effects such as inflammatory reaction, fibrosis or corneal perforation were observed.

**Keywords:** corneal micropuncture, micro infusion of drugs



## 2019 Research Days Abstract Form

### 2. SCIENTIFIC SECTION PREFERENCE (REQUIRED):

Review the Scientific Section Descriptions. Select and enter the two-letter Code for the one (1) Section best suited to review your abstract.

**(CO) CORNEA AND EXTERNAL DISEASE**

### 3. PRESENTATION PREFERENCE (REQUIRED)

Check one:

**(CO) CORNEA AND EXTERNAL DISEASE**

4. The signature of the First (Presenting) Author (REQUIRED) acting as the authorized agent for all authors, hereby certifies that any research reported was conducted in compliance with the Declaration of Helsinki and the "UNIFESP Ethical Committee"

### Scientific Section Descriptions (two-letter code):

(BE) OCULAR BIOENGINEERING  
(CO) CORNEA AND EXTERNAL DISEASE  
(CA) CATARACT  
(EF) ELECTROPHYSIOLOGY  
(EP) EPIDEMIOLOGY  
(EX) EXPERIMENTAL SURGERY  
(GL) GLAUCOMA  
(LA) LABORATORY  
(LS) LACRIMAL SYSTEM  
(LV) LOW VISION  
(NO) NEURO-OPHTHALMOLOGY  
(OR) ORBIT  
(PL) OCULAR PLASTIC SURGERY  
(PH) PHARMACOLOGY  
(RE) RETINA AND VITREOUS  
(RS) REFRACTIVE SURGERY  
(RX) REFRACTION-CONTACT LENSES  
(ST) STRABISMUS  
(TR) TRAUMA  
(TU) TUMORS AND PATHOLOGY  
(UV) UVEITIS  
(US) OCULAR ULTRASOUND

Deadline: 10/2019

### FORMAT:

#### Abstract should contain:

Title  
Author  
Co-authors (maximum 6)  
Purpose  
Methods  
Results  
Conclusion  
Keywords

Poster guidelines:  
**90cm x 120cm**

### FIRST (PRESENTING) AUTHOR (REQUIRED):

**Name:** Aline Couto Carneiro - PG0 - DO  
**e-mail:** alinecouto.epm@gmail.com  
**CEP Number:** 0506/2016

### 5. ABSTRACT (REQUIRED):

**Title:** Purpuriocillium keratitis: a challenging infection

**Author and Co-authors:** Aline Couto Carneiro, Mario Roberto Sousa Trindade, Maria Cecilia Zorat- Yu, Ana Luisa Hofling- Lima, Arnaldo Lopes Colombo, Denise Freitas

**Purpose:** Purpuriocillium sp are filamentous saprophytic fungi found worldwide. Half of all reported infections affect the eye, and many are refractory to conventional anti-fungal agents.

**Methods:** We have performed a retrospective study between 1995-2018 of 24 patients developing P. keratitis in São Paulo's hospital. The 42 strains were identified and isolated in 23 different cases to do the Minimum Inhibitory Concentrations (MIC) and analyze the most common anti-fungals drugs against the Purpuriocillium lilacinus.

**Results:** Most part of all cases developed this infection after eye surgery, followed by contact lens and ocular trauma. The main topical treatment drugs were amphotericin B 0,15% and intracameral injection. However, the patients kept worsening and were submitted to keratoplasty. The direct mycological examination were required in 28 strains, and 12 were positive. The majority of antifungigram showed elevated MIC regarding anphotericin B (16µg/mL), variable to itraconazole (4-8µg/mL), and sensibility to voriconazole (0,125µg/mL) and posiconazole (0,5µg /mL). The DNA polymerase tracking are in progress.

**Conclusion:** P. lilacinus keratitis does not respond reliably to most frequently applied anti-fungal treatment, demanding therapeutic keratoplasty. Voriconazole and posaconazole were considered the best anti-fungal drugs for the treatment of Purpureocillium lilacinus keratitis.

**Keywords:** Purpuriocillium sp, Keratitis, oculomycoses

## 2019 Research Days Abstract Form

### 2. SCIENTIFIC SECTION PREFERENCE (REQUIRED):

Review the Scientific Section Descriptions. Select and enter the two-letter Code for the one (1) Section best suited to review your abstract.

**(CO) CORNEA AND EXTERNAL DISEASE**

### 3. PRESENTATION PREFERENCE (REQUIRED)

Check one:

**(CO) CORNEA AND EXTERNAL DISEASE**

4. The signature of the First (Presenting) Author (REQUIRED) acting as the authorized agent for all authors, hereby certifies that any research reported was conducted in compliance with the Declaration of Helsinki and the "UNIFESP Ethical Committee"

### Scientific Section Descriptions (two-letter code):

(BE) OCULAR BIOENGINEERING  
(CO) CORNEA AND EXTERNAL DISEASE  
(CA) CATARACT  
(EF) ELECTROPHYSIOLOGY  
(EP) EPIDEMIOLOGY  
(EX) EXPERIMENTAL SURGERY  
(GL) GLAUCOMA  
(LA) LABORATORY  
(LS) LACRIMAL SYSTEM  
(LV) LOW VISION  
(NO) NEURO-OPHTHALMOLOGY  
(OR) ORBIT  
(PL) OCULAR PLASTIC SURGERY  
(PH) PHARMACOLOGY  
(RE) RETINA AND VITREOUS  
(RS) REFRACTIVE SURGERY  
(RX) REFRACTION-CONTACT LENSES  
(ST) STRABISMUS  
(TR) TRAUMA  
(TU) TUMORS AND PATHOLOGY  
(UV) UVEITIS  
(US) OCULAR ULTRASOUND

Deadline: 10/2019

### FORMAT:

#### Abstract should contain:

Title  
Author  
Co-authors (maximum 6)  
Purpose  
Methods  
Results  
Conclusion  
Keywords

Poster guidelines:  
**90cm x 120cm**

### FIRST (PRESENTING) AUTHOR (REQUIRED):

**Name:** Luciana Lopes Rocha - PG0 - DO  
**e-mail:** luciana\_lr@yahoo.com.br  
**CEP Number:** 0843/2017

### 5. ABSTRACT (REQUIRED):

**Title: CORNEAL TRANSPLANTATION IN PATIENTS WITH ACANTHAMOEBA KERATITIS**

**Author and Co-authors:** Luciana Lopes Rocha, Denise de Freitas

**Purpose:** To evaluate the results involving corneal transplantation by Acanthamoeba  
**Methods:** Transversal, observational, retrospective study analyzing patients with Acanthamoeba keratitis who underwent therapeutic keratoplasty until december 2018. The study was conducted at the Department of Ophthalmology and Visual Sciences of Escola Paulista de Medicina, Hospital São Paulo, UNIFESP using data from the patients' records, as well as anatomopathological analysis and cultures. Additional information about gender, age, contact lens wear, clinical and etiological diagnosis, post-operative visual acuity and medications were also collected. Incompleted electronic medical records were excluded.

**Results:** We studied 38 eyes from 36 patients. Most patients (52,63%) were female and the average age was 44 years (range 29?75 years). 94,11% were contact lens wearers and of these, 86,66% were soft contact lenses. The average time to diagnosis was 10 weeks (range 2-28 weeks). The first culture was positive for Acanthamoeba in 76% of cases. The average time to culture positivity was 13 days (range 4-22 days). In 2 cases the diagnosis was performed by confocal microscopy. The mean treatment time was 7 months (range 1?17 months). All patients underwent penetrating keratoplasty and of these, 82,75% was therapeutic. Most common post-operative complication was glaucoma (15 patients, 39,47%). The mydriasis-cataract-glaucoma syndrome was present in 7 patients (18,42%), and two had the onset of the signs beginning before the transplant. Endophthalmitis occurred in two patients, the first e second case described in Brazil. The recurrence of infection in the corneal transplant happened in 4 cases (10,52%). The final visual acuity better than 20/40 was present in 52,94% of the patients.

**Conclusion:** In conclusion, the use of contact lens, mainly soft, is the main risk factor. The clinical diagnosis of AK is still delayed. The preoperative treatment time was long, which justified the need for therapeutic corneal transplantation. Corneal transplantation may be a treatment option for infections that are unresponsive to medical treatment. However, graft survival is poor and postoperative glaucoma is frequent.

**Keywords:** corneal transplantation; Acanthamoeba

## 2019 Research Days Abstract Form

### 2. SCIENTIFIC SECTION PREFERENCE (REQUIRED):

Review the Scientific Section Descriptions. Select and enter the two-letter Code for the one (1) Section best suited to review your abstract.

**(CO) CORNEA**

### 3. PRESENTATION PREFERENCE (REQUIRED)

Check one:

**(CO) CORNEA AND EXTERNAL DISEASE**

4. The signature of the First (Presenting) Author (REQUIRED) acting as the authorized agent for all authors, hereby certifies that any research reported was conducted in compliance with the Declaration of Helsinki and the "UNIFESP Ethical Committee"

### Scientific Section Descriptions (two-letter code):

(BE) OCULAR BIOENGINEERING  
(CO) CORNEA AND EXTERNAL DISEASE  
(CA) CATARACT  
(EF) ELECTROPHYSIOLOGY  
(EP) EPIDEMIOLOGY  
(EX) EXPERIMENTAL SURGERY  
(GL) GLAUCOMA  
(LA) LABORATORY  
(LS) LACRIMAL SYSTEM  
(LV) LOW VISION  
(NO) NEURO-OPHTHALMOLOGY  
(OR) ORBIT  
(PL) OCULAR PLASTIC SURGERY  
(PH) PHARMACOLOGY  
(RE) RETINA AND VITREOUS  
(RS) REFRACTIVE SURGERY  
(RX) REFRACTION-CONTACT LENSES  
(ST) STRABISMUS  
(TR) TRAUMA  
(TU) TUMORS AND PATHOLOGY  
(UV) UVEITIS  
(US) OCULAR ULTRASOUND

Deadline: 10/2019

### FORMAT:

#### Abstract should contain:

Title  
Author  
Co-authors (maximum 6)  
Purpose  
Methods  
Results  
Conclusion  
Keywords

Poster guidelines:  
**90cm x 120cm**

### FIRST (PRESENTING) AUTHOR (REQUIRED):

**Name:** Francisco Bandeira e Silva - PG1 - DO  
**e-mail:** franciscobandeira@me.com  
**CEP Number:** 2016/2839

### 5. ABSTRACT (REQUIRED):

#### **Title: AN INVESTIGATION OF ALTERNATIVE RHO-ASSOCIATED KINASE (ROCK) INHIBITORS AND A COMPARISON OF THEIR EFFECTS ON CORNEAL ENDOTHELIAL WOUND RECOVERY**

**Author and Co-authors:** Francisco Bandeira Gary SL Peh Shu-Jun Lin Sacha Naso Hon Shing Ong Jose Alvaro Pereira Gomes Jodhbir S Mehta

**Purpose:** To evaluate the efficacy of endothelial wound closure of two ROCKi from different classes in a "peel" and "scratch" wound model.

**Methods:** Research grade cornea pairs with a donor age ranging from 61 to 65 years old were procured from Lions Eye Bank. Peel and scratch wounds of 3 mm were created in corneas from the same donor pairs. The corneas were randomly assigned for treatment with either 10  $\mu$ M of Y27632 or 1  $\mu$ M of AR13324 and maintained in a stabilization culture media system for 21 days. Endothelial wound area and healing rates (WHR) were assessed with 0.2% trypan blue after wounding and weekly thereafter. Data was analyzed by ImageJ color threshold method and recovered areas were compared. All samples were also analyzed by alizarin red staining and scanning electron.

**Results:** In both groups, ROCKi treatment reduced the mean wounded area to less than 20% for scratched ( $p < 0.001$ ) and higher than 60% for peeled ( $p < 0.05$ ). The mean WHR was 1.72 times higher for AR13324 and 2.15 times higher for Y27632 for scratched wounds when compared to peeled wounds. There was no significant difference between groups regarding WHR or final healed area. Alizarin Red staining and SEM showed cells indicative of enlarged hCEC over both scratched and peeled areas.

**Conclusion:** The use of either Y27632 or AR13324 in our ex vivo model induced significant endothelial wound recovery of both peeled and scratched wounds. However, this was more evident for scratched wounds. Our results showed that both AR13324 and Y27632 promoted endothelial wound closure. These ROCKi classes hold clinical potential in endothelial regenerative treatments.

**Keywords:** corneal endothelial cells, ROCK inhibitor

## 2019 Research Days Abstract Form

### 2. SCIENTIFIC SECTION PREFERENCE (REQUIRED):

Review the Scientific Section Descriptions. Select and enter the two-letter Code for the one (1) Section best suited to review your abstract.

**(CO) CORNEA AND EXTERNAL DISEASE**

### 3. PRESENTATION PREFERENCE (REQUIRED)

Check one:

**(CO) CORNEA AND EXTERNAL DISEASE**

4. The signature of the First (Presenting) Author (REQUIRED) acting as the authorized agent for all authors, hereby certifies that any research reported was conducted in compliance with the Declaration of Helsinki and the "UNIFESP Ethical Committee"

Scientific Section Descriptions (two-letter code):

(BE) OCULAR BIOENGINEERING  
(CO) CORNEA AND EXTERNAL DISEASE  
(CA) CATARACT  
(EF) ELECTROPHYSIOLOGY  
(EP) EPIDEMIOLOGY  
(EX) EXPERIMENTAL SURGERY  
(GL) GLAUCOMA  
(LA) LABORATORY  
(LS) LACRIMAL SYSTEM  
(LV) LOW VISION  
(NO) NEURO-OPHTHALMOLOGY  
(OR) ORBIT  
(PL) OCULAR PLASTIC SURGERY  
(PH) PHARMACOLOGY  
(RE) RETINA AND VITREOUS  
(RS) REFRACTIVE SURGERY  
(RX) REFRACTION-CONTACT LENSES  
(ST) STRABISMUS  
(TR) TRAUMA  
(TU) TUMORS AND PATHOLOGY  
(UV) UVEITIS  
(US) OCULAR ULTRASOUND

Deadline: 10/2019

### FORMAT:

#### Abstract should contain:

Title  
Author  
Co-authors (maximum 6)  
Purpose  
Methods  
Results  
Conclusion  
Keywords

Poster guidelines:  
**90cm x 120cm**

### FIRST (PRESENTING) AUTHOR (REQUIRED):

**Name:** Joyce Luciana Covre - PG1 - DO  
**e-mail:** joycecovre@gmail.com  
**CEP Number:** 1274/2015

### 5. ABSTRACT (REQUIRED):

**Title: Evaluation of keratoconus corneas: Histochemical, ultrastructural and molecular analysis**

**Author and Co-authors:** Joyce Luciana Covre, Mauro Silveira de Queiroz Campos, Cristiane Damas Gil, Jose Alvaro Pereira Gomes

**Purpose:** Characterize human keratoconus corneas using histochemical, ultrastructural and molecular analysis.

**Methods:** Cornea samples from control and KC patients were collected and processed for histological, biochemical, immunohistochemical and ultrastructural analyses. Primary keratocytes from control and KC corneas were isolated by collagenase digestion from surgically removed corneas of three normal or KC human corneal buttons and cultured in DMEM/Ham's F12 medium supplemented with 2 % fetal bovine serum. After these cells reach the confluence state (~30 days), they were processed for western blot analysis to evaluate the Src (Tyr416 and Tyr527) and phosphorylated focal adhesion kinases (p-Fak925),  $\beta$ 1-integrin, vimentin, keratocan and lumican levels.

**Results:** Histological analysis showed that stromal from KC corneas presented disorganized collagen fibers compared to control samples. Picosirius-polarization analysis demonstrated enhanced birefringence of collagen networks from control corneas compared to KC. Densitometry of yellow-red/ green birefringence of collagen fibers confirmed these findings and indicates a loss of collagen alignment in the KC. Ultrastructural analysis of KC cornea demonstrated thin collagen fibers and keratocytes with intense vacuolization of cytoplasm. In addition, KC cultured cells showed reduced levels of vimentin ( $p < 0.05$  vs. control), p-FAK925,  $\beta$ 1-integrin, and keratocan. By contrast, KC keratocytes increased Src activation and lumican levels compared to control cells. Immunohistochemistry of KC corneas also demonstrated intense immunostain of lumican and low levels of keratocan.

**Conclusion:** Our findings provide that KC is associated with a marked alteration of structural and molecular patterns of corneal stroma and may be of significance for explanation of KC pathogenesis.

**Keywords:** Collagen network, Keratocytes, Picosirius-polarization Method, Proteoglycans, Ultrastructural Analysis.

## 2019 Research Days Abstract Form

### 2. SCIENTIFIC SECTION PREFERENCE (REQUIRED):

Review the Scientific Section Descriptions. Select and enter the two-letter Code for the one (1) Section best suited to review your abstract.

**(CO) CORNEA**

### 3. PRESENTATION PREFERENCE (REQUIRED)

Check one:

**(CO) CORNEA AND EXTERNAL DISEASE**

4. The signature of the First (Presenting) Author (REQUIRED) acting as the authorized agent for all authors, hereby certifies that any research reported was conducted in compliance with the Declaration of Helsinki and the "UNIFESP Ethical Committee"

### Scientific Section Descriptions (two-letter code):

(BE) OCULAR BIOENGINEERING  
(CO) CORNEA AND EXTERNAL DISEASE  
(CA) CATARACT  
(EF) ELECTROPHYSIOLOGY  
(EP) EPIDEMIOLOGY  
(EX) EXPERIMENTAL SURGERY  
(GL) GLAUCOMA  
(LA) LABORATORY  
(LS) LACRIMAL SYSTEM  
(LV) LOW VISION  
(NO) NEURO-OPHTHALMOLOGY  
(OR) ORBIT  
(PL) OCULAR PLASTIC SURGERY  
(PH) PHARMACOLOGY  
(RE) RETINA AND VITREOUS  
(RS) REFRACTIVE SURGERY  
(RX) REFRACTION-CONTACT LENSES  
(ST) STRABISMUS  
(TR) TRAUMA  
(TU) TUMORS AND PATHOLOGY  
(UV) UVEITIS  
(US) OCULAR ULTRASOUND

Deadline: 10/2019

### FORMAT:

**Abstract should contain:**

Title  
Author  
Co-authors (maximum 6)  
Purpose  
Methods  
Results  
Conclusion  
Keywords

Poster guidelines:  
**90cm x 120cm**

### FIRST (PRESENTING) AUTHOR (REQUIRED):

**Name:** Fábio Kenji Matsumoto - PG1 - DO  
**e-mail:** fabiokenji75@gmail.com  
**CEP Number:** 8.020.043

### 5. ABSTRACT (REQUIRED):

**Title: Scaled pachymetric gain of standard Cross-linking using hyposmolar riboflavin in patients with keratoconus**

**Author and Co-authors:** Fábio Kenji Matsumoto, MD, Marcelo Tojar, MD, Luciene Barbosa de Souza, MD, PhD

**Purpose:** To evaluate the gain of intraoperative pachymetry measurement in patients undergoing Cross-linking with hyposmolar riboflavin in thinned corneas. It also investigates possible endothelial damage after this procedure, maximum curvature stability and corneal thickness assessment.

**Methods:** This is a prospective case series, conducted at the Department of Ophthalmology and Visual Sciences of the Paulista School of Medicine / UNIFESP in the sector of External Eye and Corneal Diseases. Preoperatively, all patients underwent full eye examination, specular microscopy (Nidek CEM 530 Specular Microscope®), corneal tomography (Oculus Pentacam HR®), anterior segment OCT (Zeiss®). Opto CXL Laser® (370nm, 3mW / cm<sup>2</sup>, b5.4 J / cm<sup>2</sup>, distance of 05 cm) and riboflavin Hyposmolar 0.1% of EyePharma for 60 minutes (every 05 minutes for 30 minutes in soaking and then 05 minutes for 30 minutes during UVA) were used. An ANVISA-regulated Tomey SP-100® portable caliper monitored the pachymetry gain. The inclusion criteria of this study is: age greater than or equal to 14 years, progression of keratoconus based on increase of maximum curvature (K<sub>máx</sub>) 0,75D in 06 months or 1,00D in 01 year (maximum value of 70D), epithelium-free pachymetry between 330-400 µm (epi-off) and no use of gas permeable rigid lens or any other type of lens 14 days prior to analysis of measurements and procedure. In contrast, cases were excluded from the study: expectation of visual improvement, acute hydrops keratoconus, significant corneal opacity, corneal endothelial count less than 1000 cells / mm<sup>2</sup>, collagen, autoimmune or other systemic diseases and pregnancy.

**Results:** The study has 30 patients submitted to Cross-linking with hyposmolar riboflavin, respecting the inclusion and exclusion criteria. They were followed for 01 year according the frequency of consultations already mentioned. There were no complications during the study phases (pre, intra and postoperative), such as corneal infections, reepithelial failure, endothelial lesion, uveitis and increased intraocular pressure. Most patients undergoing the procedure are male, left eye, mean 22 years old (range 15 to 44 years) and most of them do not use rigid gas permeable contact lenses. During the procedure, the pachymetry measurement was evaluated with Tomey SP-100® before desepithelialization, immediately after desepithelialization, and within the following minutes after initiating the hyposmolar riboflavin instillation: 15, 30, 35, 40, 45, 50, 60 minutes. In the last 30 minutes, the UVA radiation phase had hyposmolar riboflavin instillation every 5 minutes without light interruption. The intraoperative pachymetry measurement was standardized to perform the measurement in the thinnest region of the cornea, guided by corneal tomography, and the average of 3 consecutive automatic measurements by the device. Intraoperative pachymetry behavior, endothelial count, maximal corneal curvature (K<sub>máx</sub>) and thinner pachymetry measured by the tomograph are in the statistical analysis phase.

**Conclusion:** In progress

**Keywords:** keratoconus, Cross-linking, hyposmolar riboflavin

## 2019 Research Days Abstract Form

### 2. SCIENTIFIC SECTION PREFERENCE (REQUIRED):

Review the Scientific Section Descriptions. Select and enter the two-letter Code for the one (1) Section best suited to review your abstract.

**(CO) CORNEA AND EXTERNAL DISEASE**

### 3. PRESENTATION PREFERENCE (REQUIRED)

Check one:

**(CO) CORNEA AND EXTERNAL DISEASE**

4. The signature of the First (Presenting) Author (REQUIRED) acting as the authorized agent for all authors, hereby certifies that any research reported was conducted in compliance with the Declaration of Helsinki and the "UNIFESP Ethical Committee"

### Scientific Section Descriptions (two-letter code):

(BE) OCULAR BIOENGINEERING  
(CO) CORNEA AND EXTERNAL DISEASE  
(CA) CATARACT  
(EF) ELECTROPHYSIOLOGY  
(EP) EPIDEMIOLOGY  
(EX) EXPERIMENTAL SURGERY  
(GL) GLAUCOMA  
(LA) LABORATORY  
(LS) LACRIMAL SYSTEM  
(LV) LOW VISION  
(NO) NEURO-OPHTHALMOLOGY  
(OR) ORBIT  
(PL) OCULAR PLASTIC SURGERY  
(PH) PHARMACOLOGY  
(RE) RETINA AND VITREOUS  
(RS) REFRACTIVE SURGERY  
(RX) REFRACTION-CONTACT LENSES  
(ST) STRABISMUS  
(TR) TRAUMA  
(TU) TUMORS AND PATHOLOGY  
(UV) UVEITIS  
(US) OCULAR ULTRASOUND

Deadline: 10/2019

### FORMAT:

#### Abstract should contain:

Title  
Author  
Co-authors (maximum 6)  
Purpose  
Methods  
Results  
Conclusion  
Keywords

Poster guidelines:  
**90cm x 120cm**

### FIRST (PRESENTING) AUTHOR (REQUIRED):

**Name:** Júlia Gomes F. Polido Cabral - PG1 - DO  
**e-mail:** juliapolido@yahoo.com.br  
**CEP Number:** 1887/11

### 5. ABSTRACT (REQUIRED):

**Title: Efficacy and safety of riboflavin-ultraviolet type A rays inducing cross-linking of corneal collagen in patients aged 8 to 16 years with progressing keratoconus.**

**Author and Co-authors:** Júlia Polido, Thiago Cabral, Taís Wakamatsu, Eliane Mayumi, Renato Ambrósio Júnior, Maria Emília Araújo, Denise de Freitas.

**Purpose:** To assess the effectiveness and safety of riboflavin-ultraviolet type A rays induced cross-linking (CXL) of corneal collagen in reducing progression of keratoconus and in improving visual acuity in pediatric patients with progressive keratoconus.

**Methods:** Prospective nonrandomized open study comprised 58 eyes of 58 patients, aged between 8 to 16 years affected by documented progressive keratoconus, with corneal thickness of at least 400 µm at the thinnest point, were treated by combined riboflavin-ultraviolet type A rays (UVA) collagen CXL. Radiant energy was 3 mW/cm<sup>2</sup> or 5.4 joule/cm<sup>2</sup> for a 30-minute exposure at 5 cm from the corneal apex. After treatment, eyes were medicated and dressed with a soft contact lens. A complete ophthalmologic examination (uncorrected visual acuity [UCVA], best spectacle-corrected visual acuity [BSCVA]) was performed before treatment, at 3 months, 6 months, 1, 2 and 3 to 4 years afterwards. Patients had corneal computerized topographic examination, anterior segment ocular coherence tomography, Scheimpflug imaging providing corneal topography, pachymetry and tomography imaging.

**Results:** The mean age was 12.5 ± 1.9 years (range 8-16 years), there were 46 males. The risk factors for Keratoconus development in the patient population included ocular allergy in 86.2% and family history of keratoconus in 31.0% of the patients. UCVA and BSCVA improvements were statistically significant (P < 0.001) throughout the entire postoperative period when compared with the preoperative values. Mean ± SE baseline flattest keratometry, steepest keratometry, average keratometry and maximum keratometry, were 47.95 ± 0.60 D, 53.29 ± 0.74 D, 50.42 ± 0.65 D and 60.16 ± 1.02 D respectively. At 3 to 4 years, these readings were 47.03 ± 0.63 D, 51.70 ± 0.76 D, 49.24 ± 0.66 D and 58.25 ± 1.05 D, respectively, a difference that was statistically significant (P < 0.001). Corneal astigmatism showed a statistically significant reduction at 1 year after CXL, being similar at 2 and 3 to 4 years. There was a statistically significant decrease in thinnest pachymetry in both exams, Visante OCT and Pentacam HR, between baseline and 3 months after CXL (mean change 21.45 µm). The variation in thinnest pachymetry between 3 months and 1, 2 and 3 to 4 years was not statistically significant and the mean thinnest pachymetry remained decreased from baseline. At this moment, only three patients progressed at 2-3 years after CXL and two of this patients did another CXL surgery.

**Conclusion:** Cross-linking showed to be safe and effective in pediatric patients in 3-4 years follow-up. A good functional response in visual acuity and keratoconus stability was obtained after corneal CXL, during this period, in most patients. The authors declare no conflict of interest, financial or otherwise.

**Keywords:** corneal collagen cross-linking, pediatric patients, keratoconus

## 2019 Research Days Abstract Form

### 2. SCIENTIFIC SECTION PREFERENCE (REQUIRED):

Review the Scientific Section Descriptions. Select and enter the two-letter Code for the one (1) Section best suited to review your abstract.

**(CO) CORNEA AND EXTERNAL DISEASE**

### 3. PRESENTATION PREFERENCE (REQUIRED)

Check one:

**(CO) CORNEA AND EXTERNAL DISEASE**

4. The signature of the First (Presenting) Author (REQUIRED) acting as the authorized agent for all authors, hereby certifies that any research reported was conducted in compliance with the Declaration of Helsinki and the "UNIFESP Ethical Committee"

### Scientific Section Descriptions (two-letter code):

(BE) OCULAR BIOENGINEERING  
(CO) CORNEA AND EXTERNAL DISEASE  
(CA) CATARACT  
(EF) ELECTROPHYSIOLOGY  
(EP) EPIDEMIOLOGY  
(EX) EXPERIMENTAL SURGERY  
(GL) GLAUCOMA  
(LA) LABORATORY  
(LS) LACRIMAL SYSTEM  
(LV) LOW VISION  
(NO) NEURO-OPHTHALMOLOGY  
(OR) ORBIT  
(PL) OCULAR PLASTIC SURGERY  
(PH) PHARMACOLOGY  
(RE) RETINA AND VITREOUS  
(RS) REFRACTIVE SURGERY  
(RX) REFRACTION-CONTACT LENSES  
(ST) STRABISMUS  
(TR) TRAUMA  
(TU) TUMORS AND PATHOLOGY  
(UV) UVEITIS  
(US) OCULAR ULTRASOUND

Deadline: 10/2019

### FORMAT:

#### Abstract should contain:

Title  
Author  
Co-authors (maximum 6)  
Purpose  
Methods  
Results  
Conclusion  
Keywords

Poster guidelines:  
**90cm x 120cm**

### FIRST (PRESENTING) AUTHOR (REQUIRED):

**Name:** Maria Carolina Marquezan - PG1 - DO  
**e-mail:** mcmarquezan@gmail.com  
**CEP Number:** 71215-770

### 5. ABSTRACT (REQUIRED):

#### **Title: Reverse SMILE With An Excimer Laser Treated Biomaterial: A Novel Approach to Corneal Reshaping Using an Intracorneal Implant**

**Author and Co-authors:** Maria Carolina Marquezan, Heloisa Nascimento, Shoumyo Majumdar, Xiaokun Wang, Jennifer Elisseeff, David L. Guyton, Kraig Scot Bower, Maria Regina Chalita, Albert S. Jun, Rubens Belfort Jr, Denise de Freitas.

**Purpose:** To determine anatomical and optical changes in porcine corneas following insertion of a new biocompatible polymer into the cornea.

**Methods:** The novel shaping agent is a clear, biocompatible, collagen type I based vitrigel material with a 6 mm diameter. The biomaterial was shaped with the excimer laser on the posterior surface to create three planoconcave shapes and inserted into a manually dissected stromal pocket at approximately 200 micrometer (?m) depth. Treatment groups included group A (3 eyes) 70 ?m maximal ablation depth, Group B (3 eyes) 64 ?m maximal ablation depth, and group C (3 eyes) 104 ?m maximal ablation depth, with a central hole. Group D (3 eyes) was included as a control group with creation of a pocket but without insertion of biomaterial. Evaluation of porcine eyes was performed by optical coherence tomography and corneal tomography.

**Results:** Corneal tomography showed the mean keratometry in group A decreased from 36.80 to 28.90. A similar result was seen in group B which decreased from 34.00 to 33.88, and in group C which decreased from 34.67 to 32.13. For the control group D, the mean keratometry decreased from 33.78 to 33.12. Corneal flattening was more evident in the group with biomaterial implant (ABC), with a greater reduction of Km (Delta 3.52) compared to the control group (Delta 0.67), but this reduction was not statistically significant ( $p = 0.405$ ). When K1 and K2 were evaluated separately, between the group with the intrastromal implant, there was a statistically significant reduction ( $p = 0.021$ ) of K1. OCT of the corneas from groups A, B, and C showed implants placed within the anterior stroma and gross appearance of flattening whereas the control group did not change shape.

**Conclusion:** The novel planoconcave biomaterial implant was able to reshape the cornea in an ex vivo model, resulting in flattening of the cornea. This approach could represent a novel treatment for myopia and corneal ectasia.

**Keywords:** corneal reshaping, excimer laser, intracorneal implant

## 2019 Research Days Abstract Form

### 2. SCIENTIFIC SECTION PREFERENCE (REQUIRED):

Review the Scientific Section Descriptions. Select and enter the two-letter Code for the one (1) Section best suited to review your abstract.

**(CO) CORNEA AND EXTERNAL DISEASE**

### 3. PRESENTATION PREFERENCE (REQUIRED)

Check one:

**(CO) CORNEA AND EXTERNAL DISEASE**

4. The signature of the First (Presenting) Author (REQUIRED) acting as the authorized agent for all authors, hereby certifies that any research reported was conducted in compliance with the Declaration of Helsinki and the "UNIFESP Ethical Committee"

### Scientific Section Descriptions (two-letter code):

(BE) OCULAR BIOENGINEERING  
(CO) CORNEA AND EXTERNAL DISEASE  
(CA) CATARACT  
(EF) ELECTROPHYSIOLOGY  
(EP) EPIDEMIOLOGY  
(EX) EXPERIMENTAL SURGERY  
(GL) GLAUCOMA  
(LA) LABORATORY  
(LS) LACRIMAL SYSTEM  
(LV) LOW VISION  
(NO) NEURO-OPHTHALMOLOGY  
(OR) ORBIT  
(PL) OCULAR PLASTIC SURGERY  
(PH) PHARMACOLOGY  
(RE) RETINA AND VITREOUS  
(RS) REFRACTIVE SURGERY  
(RX) REFRACTION-CONTACT LENSES  
(ST) STRABISMUS  
(TR) TRAUMA  
(TU) TUMORS AND PATHOLOGY  
(UV) UVEITIS  
(US) OCULAR ULTRASOUND

Deadline: 10/2019

### FORMAT:

#### Abstract should contain:

Title  
Author  
Co-authors (maximum 6)  
Purpose  
Methods  
Results  
Conclusion  
Keywords

Poster guidelines:  
**90cm x 120cm**

### FIRST (PRESENTING) AUTHOR (REQUIRED):

**Name:** Pablo Felipe Rodrigues - PG1 - DO  
**e-mail:** drpablo.rodrigues@gmail.com  
**CEP Number:** 01424-000

### 5. ABSTRACT (REQUIRED):

**Title: Comparison of intraocular pressure measurements after corneal ring intrastromal segment implantation with Goldmann applanation tonometry and Corvis.**

**Author and Co-authors:** Pablo Rodrigues, José Job Neto, Lisangela Morimoto, Denise de Freitas, José Alvaro, Mauro Campos, Walton Nosé.

**Purpose:** To compare Corvis IOP measurements and Goldmann Applanation Tonometry (TAG) in normal topography patients undergoing the new ICRS model for myopic treatment.

**Methods:** Patients with moderate and high myopia with contraindication for refractive surgery underwent implantation of a new ICRS model. Measurements were taken before and after 6 months of implantation. Corneal results are obtained using same the Pentacam, Corvis (Oculus, Germany) and Goldmann Applanation Tonometer (GAT) (Haag-Streit, Switzerland) and all measures were in the same period of the day. The study protocol adhered to the principles of the Declaration of Helsinki and was approved by Ethics Committee. The surgery was performed only with the informed consent. All subjects underwent a complete eye examination. Soft contact lens wearers were discontinued for at least 3 weeks and rigid contact lenses for at least 1 week prior to previous exams. All surgeries were performed by femtosecond laser Inclusion criteria: Spherical equivalent between 10.0 to 5.00D, PTA equal or plus 0,40, Residual thickness less than 280 microns, Patients with tomographic and/or biomechanical risk criteria. Exclusion criteria: Presence of corneal diseases, Previous eye surgery, best correct visual acuity less than LogMar 0.18.

**Results:** 21 eyes of 13 patients were evaluated. 07 women and 06 men. Average age of 25,88. The mean preoperative corrected visual acuity was LogMar 0.06 and maintained after the procedure. The preoperative Km ranged from 43.76 to 40.53. The previous corneal astigmatism was 1.85 and ranged to 0,88D. The mean thinnest point ranged from 520,85 to 526,93 micra. The mean preop TAG was 14,16 and changed to 14,96 mmHg. The mean preoperative PIONct ranged from 15,72 mmHg to 13,57. The mean preoperative bPIO ranged from 15,70 to 13,65 mmHg.

**Conclusion:** Precise measurement of the IOP after ocular surgery is essential to avoid elevated IOP-related ocular complications. GAT is still the most commonly used method because of its accuracy, and ease of use with low intraobserver and interobserver variability. However, it may be affected by corneal thickness that deviates significantly from an idealized normal value and in the context of corneas that have keratometry values that are steeper, flatter, or more astigmatic. ICRS are made of polymethylmethacrylate resulting in an altered shape, the biomechanical parameters may be affected. However, our study is preliminary. A long-term study would help to draw conclusions and to determine the effect of ICRS implantation on IOP measurement. Financial support: AJL, Ziemer.

**Keywords:** icrs, intra-ocular pressure, corneal biomechanics, goldmann applanation tonometry, corvis



## 2019 Research Days Abstract Form

### 2. SCIENTIFIC SECTION PREFERENCE (REQUIRED):

Review the Scientific Section Descriptions. Select and enter the two-letter Code for the one (1) Section best suited to review your abstract.

**(CO) CORNEA AND EXTERNAL DISEASE**

### 3. PRESENTATION PREFERENCE (REQUIRED)

Check one:

**(CO) CORNEA AND EXTERNAL DISEASE**

4. The signature of the First (Presenting) Author (REQUIRED) acting as the authorized agent for all authors, hereby certifies that any research reported was conducted in compliance with the Declaration of Helsinki and the "UNIFESP Ethical Committee"

Scientific Section Descriptions (two-letter code):

(BE) OCULAR BIOENGINEERING  
(CO) CORNEA AND EXTERNAL DISEASE  
(CA) CATARACT  
(EF) ELECTROPHYSIOLOGY  
(EP) EPIDEMIOLOGY  
(EX) EXPERIMENTAL SURGERY  
(GL) GLAUCOMA  
(LA) LABORATORY  
(LS) LACRIMAL SYSTEM  
(LV) LOW VISION  
(NO) NEURO-OPHTHALMOLOGY  
(OR) ORBIT  
(PL) OCULAR PLASTIC SURGERY  
(PH) PHARMACOLOGY  
(RE) RETINA AND VITREOUS  
(RS) REFRACTIVE SURGERY  
(RX) REFRACTION-CONTACT LENSES  
(ST) STRABISMUS  
(TR) TRAUMA  
(TU) TUMORS AND PATHOLOGY  
(UV) UVEITIS  
(US) OCULAR ULTRASOUND

Deadline: 10/2019

### FORMAT:

#### Abstract should contain:

Title  
Author  
Co-authors (maximum 6)  
Purpose  
Methods  
Results  
Conclusion  
Keywords

Poster guidelines:  
**90cm x 120cm**

### FIRST (PRESENTING) AUTHOR (REQUIRED):

**Name:** Albert Wilson Santos Machado Silva - PG1 - DO  
**e-mail:** albertwsms@yahoo.com.br  
**CEP Number:** 0884/2018

### 5. ABSTRACT (REQUIRED):

**Title: Characterization of inflammatory mediators in the tear film, conjunctival epithelium and corneal epithelium in keratoconus patients.**

**Author and Co-authors:** Albert Silva, Luciene Barbosa de Sousa, Niels Olsen, Lauro Augusto de Oliveira.

**Purpose:** To investigate inflammatory mediators in the tear film, conjunctival epithelium and corneal epithelium in keratoconus patients.

**Methods:** This is a prospective and longitudinal study involving 60 patients (30 keratoconus patients and 30 patients in a control group) who will be followed for 12 months. Lacrimal samples will be collected by washing and analyzed by ELISA (IL-5, IL-6 and IgA). Conjunctival epithelium will be collected using impression cytology and exfoliative cytology. We will perform immunofluorescence and confocal microscopy looking for specific markers as IL-5, IL-6 and IgA. Corneal epithelium will be obtained by manual keratectomy (from PRK and CXL patients). Gene expression of IL-5, IL-6 and eotaxin in the corneal epithelium will be analyzed by real time-PCR after mRNA extraction from corneal epithelial cells.

**Results:** Preliminary results using a broad inflammatory bioplex assay demonstrated higher tear concentration of IL-5 and IL-6 in keratoconus patients compared to control. RT-PCR did not detect eotaxin and IL-6 expression in corneal epithelium, while IL-5 expression was detected but without significant difference between control and keratoconus groups. We are steel recruiting patients and optimizing the methodology.

**Conclusion:** So far, we have preliminary and non-conclusive results.

**Keywords:** inflammatory biomarkers, tear film, keratoconus.

## 2019 Research Days Abstract Form

### 2. SCIENTIFIC SECTION PREFERENCE (REQUIRED):

Review the Scientific Section Descriptions. Select and enter the two-letter Code for the one (1) Section best suited to review your abstract.

**(CO) CORNEA AND EXTERNAL DISEASE**

### 3. PRESENTATION PREFERENCE (REQUIRED)

Check one:

**(CO) CORNEA AND EXTERNAL DISEASE**

4. The signature of the First (Presenting) Author (REQUIRED) acting as the authorized agent for all authors, hereby certifies that any research reported was conducted in compliance with the Declaration of Helsinki and the "UNIFESP Ethical Committee"

Scientific Section Descriptions (two-letter code):

(BE) OCULAR BIOENGINEERING  
(CO) CORNEA AND EXTERNAL DISEASE  
(CA) CATARACT  
(EF) ELECTROPHYSIOLOGY  
(EP) EPIDEMIOLOGY  
(EX) EXPERIMENTAL SURGERY  
(GL) GLAUCOMA  
(LA) LABORATORY  
(LS) LACRIMAL SYSTEM  
(LV) LOW VISION  
(NO) NEURO-OPHTHALMOLOGY  
(OR) ORBIT  
(PL) OCULAR PLASTIC SURGERY  
(PH) PHARMACOLOGY  
(RE) RETINA AND VITREOUS  
(RS) REFRACTIVE SURGERY  
(RX) REFRACTION-CONTACT LENSES  
(ST) STRABISMUS  
(TR) TRAUMA  
(TU) TUMORS AND PATHOLOGY  
(UV) UVEITIS  
(US) OCULAR ULTRASOUND

Deadline: 10/2019

### FORMAT:

#### Abstract should contain:

Title  
Author  
Co-authors (maximum 6)  
Purpose  
Methods  
Results  
Conclusion  
Keywords

Poster guidelines:  
**90cm x 120cm**

### FIRST (PRESENTING) AUTHOR (REQUIRED):

**Name:** Fernanda Machado Bezerra - PG1 - DO  
**e-mail:** fernandamb1901@gmail.com  
**CEP Number:** 1422004

### 5. ABSTRACT (REQUIRED):

**Title: Fungal Keratitis Management in a Referral Cornea Center in Brazil.**

**Author and Co-authors:** Fernanda Machado Bezerra, Ana Luisa Höfling-Lima, Lauro Augusto de Oliveira

**Purpose:** To report the etiological diagnosis, predisposing risk factors, therapeutic strategies and visual outcome of patients treated at the Department of Ophthalmology and Visual Sciences of Escola Paulista de Medicina - Universidade Federal de São Paulo.

**Methods:** This is a retrospective, descriptive, and observational study from medical and laboratory records of the Department of Ophthalmology of Federal University of São Paulo, including all patients with culture proven fungal keratitis in 5 years, from October 2012 through October 2017.

**Results:** There were 2260 fungi microbiologic test requests. Of these, 140 samples had positive cultures for fungi and sixty-six patients were followed at our clinic. Forty-five patients (68.2%) were men, and the mean age was 48.06 ( $\pm 17.39$ ) years. *Fusarium* spp. was the most frequently isolated fungus (32 cases, 48.5%), followed by *Candida parapsilosis* (12 cases, 18.2%). Sixty-four patients were treated with amphotericin B 0.15% eye drops and only 2 patients were treated with topical natamycin 5%. The eye drops were applied hourly initially, tapered according to patient's responses and used on average for 2 months. Thirty-four patients (51.5%) underwent intracameral injection of amphotericin B (50  $\mu$ g per 0.1 ml). In 11 patients (32.3%), infection was eradicated after intracameral amphotericin B associated to topical antifungal treatment and, in 23 patients, therapeutic keratoplasty was needed. No complication related to intracameral amphotericin B injection was observed in this series. Forty-three patients (65.1%) ended up with therapeutic keratoplasty. Three patients evolved to evisceration or enucleation. At the last follow-up visit, 53 patients (80.3%) had visual acuity worse than 20/200.

**Conclusion:** Intracameral amphotericin B associated to topical antifungal treatment is a safe and helpful alternative for non-responsive fungal keratitis. It is important to formulate other treatment strategies, hence to improve our patients' outcomes, since most patients (80.3%) ended-up with significant visual impairment (visual acuity '<' 20/200) even after current treatment.

**Keywords:** Antifungal Agents, Fungi, Eye Infections, Corneal Transplantation, Corneal Ulcer

## 2019 Research Days Abstract Form

### 2. SCIENTIFIC SECTION PREFERENCE (REQUIRED):

Review the Scientific Section Descriptions. Select and enter the two-letter Code for the one (1) Section best suited to review your abstract.

**(LA) LABORATORY**

### 3. PRESENTATION PREFERENCE (REQUIRED)

Check one:

**(LA) LABORATORY**

4. The signature of the First (Presenting) Author (REQUIRED) acting as the authorized agent for all authors, hereby certifies that any research reported was conducted in compliance with the Declaration of Helsinki and the "UNIFESP Ethical Committee"

### Scientific Section Descriptions (two-letter code):

(BE) OCULAR BIOENGINEERING  
(CO) CORNEA AND EXTERNAL DISEASE  
(CA) CATARACT  
(EF) ELECTROPHYSIOLOGY  
(EP) EPIDEMIOLOGY  
(EX) EXPERIMENTAL SURGERY  
(GL) GLAUCOMA  
(LA) LABORATORY  
(LS) LACRIMAL SYSTEM  
(LV) LOW VISION  
(NO) NEURO-OPHTHALMOLOGY  
(OR) ORBIT  
(PL) OCULAR PLASTIC SURGERY  
(PH) PHARMACOLOGY  
(RE) RETINA AND VITREOUS  
(RS) REFRACTIVE SURGERY  
(RX) REFRACTION-CONTACT LENSES  
(ST) STRABISMUS  
(TR) TRAUMA  
(TU) TUMORS AND PATHOLOGY  
(UV) UVEITIS  
(US) OCULAR ULTRASOUND

Deadline: 10/2019

### FORMAT:

#### Abstract should contain:

Title  
Author  
Co-authors (maximum 6)  
Purpose  
Methods  
Results  
Conclusion  
Keywords

Poster guidelines:  
**90cm x 120cm**

### FIRST (PRESENTING) AUTHOR (REQUIRED):

**Name:** Talita Trevizani Rocchetti - Post-doc  
**e-mail:** talita.rocchetti@gmail.com  
**CEP Number:** 1.423.852

### 5. ABSTRACT (REQUIRED):

#### **Title: Evaluation of rose bengal mediated photodynamic therapy for in vitro inhibition of rapid growing mycobacteria**

**Author and Co-authors:** Talita Trevizani Rocchetti, Gabrielle Macena Dias dos Reis, Jackeline Stefani de Oliveira Cardoso, Vitória de Souza Rocha, Maria Cecilia Zorat Yu, Ana Luisa Hofling-Lima

**Purpose:** To evaluate in vitro efficacy of rose bengal mediated photodynamic therapy for inhibition of Rapid Growing Mycobacteria

**Methods:** Mycobacterium chelonae ATCC 35752 was grown on Middlebrook 7H10 Agar at 30° C for 5 days. Strain was transferred to high-purity water and concentrations standardized to 1.5X10<sup>8</sup> colony-forming units (CFU/mL) using a spectrophotometer. Suspension was mixed with rose Bengal for a final bacterial concentration of 1.5 X 10<sup>4</sup> CFU/mL. Treatment conditions were tested in triplicate: Group I, control (no treatment), Group II, bacterial suspension treated with 0,1% rose bengal and exposed to the dark for 30min, Group III, bacterial suspension treated with 0,1% rose bengal exposed to green light LED (7,15 mW) for 30min. Plates were incubated at 30°C and photographed after 120 hours.

**Results:** Complete growth inhibition of Mycobacterium chelonae ATCC 35752 was demonstrated with 0,1% rose bengal under green LED irradiation for 30 minutes

**Conclusion:** Rose bengal mediated therapy demonstrated complete growth inhibition in vitro to Mycobacteria chelonae. Clinical treatment may offer an alternate adjunct therapy for Mycobacteria eye infection.

**Keywords:** Mycobacteria chelonae, Rose Bengal, Photodynamic Therapy

## 2019 Research Days Abstract Form

### 2. SCIENTIFIC SECTION PREFERENCE (REQUIRED):

Review the Scientific Section Descriptions. Select and enter the two-letter Code for the one (1) Section best suited to review your abstract.

**(BE) OCULAR BIOENGINEERING**

### 3. PRESENTATION PREFERENCE (REQUIRED)

Check one:

**(BE) OCULAR BIOENGINEERING**

4. The signature of the First (Presenting) Author (REQUIRED) acting as the authorized agent for all authors, hereby certifies that any research reported was conducted in compliance with the Declaration of Helsinki and the "UNIFESP Ethical Committee"

### Scientific Section Descriptions (two-letter code):

(BE) OCULAR BIOENGINEERING  
(CO) CORNEA AND EXTERNAL DISEASE  
(CA) CATARACT  
(EF) ELECTROPHYSIOLOGY  
(EP) EPIDEMIOLOGY  
(EX) EXPERIMENTAL SURGERY  
(GL) GLAUCOMA  
(LA) LABORATORY  
(LS) LACRIMAL SYSTEM  
(LV) LOW VISION  
(NO) NEURO-OPHTHALMOLOGY  
(OR) ORBIT  
(PL) OCULAR PLASTIC SURGERY  
(PH) PHARMACOLOGY  
(RE) RETINA AND VITREOUS  
(RS) REFRACTIVE SURGERY  
(RX) REFRACTION-CONTACT LENSES  
(ST) STRABISMUS  
(TR) TRAUMA  
(TU) TUMORS AND PATHOLOGY  
(UV) UVEITIS  
(US) OCULAR ULTRASOUND

Deadline: 10/2019

### FORMAT:

**Abstract should contain:**

Title  
Author  
Co-authors (maximum 6)  
Purpose  
Methods  
Results  
Conclusion  
Keywords

Poster guidelines:  
**90cm x 120cm**

### FIRST (PRESENTING) AUTHOR (REQUIRED):

**Name:** Augusto Alves Pinho Vieira - PG0 - DO  
**e-mail:** augustovieira.med@gmail.com  
**CEP Number:** 334117011

### 5. ABSTRACT (REQUIRED):

**Title: Safety and efficacy analysis of a PAMAM-dendrimer-dextran conjugated polymer as a slow-release delivery device for an antiglaucomatous drug in an animal model**

**Author and Co-authors:** Author and Co-authors: Augusto Vieira, MD, Luísa Mendonça, MD, Bruna Fetter MsC, Juliana L. Dreyfuss, PhD Advisor: Prof. Caio Regatieri, MD, PhD

**Purpose:** Prevailing drug therapies for glaucoma require from one to 5 eye-drops instillations per day. Development of secure and patient compliant new and reliable drug delivery devices are still an unmet challenge 2. This study aim is to evaluate the safety of a PAMAM-G5 dendrimer-dextran conjugated polymer (developed at Massachusetts Institute of Technology<sup>3</sup>) for subconjunctival use and to analyze its efficacy as a carrier of dorzolamide, analyzing whether the polymer prolongs the aforementioned drug bioavailability in an animal model.

**Methods:** FIRST STEP: In vitro toxicity assessment PAMAM dendrimer-dextran conjugated polymer was incorporated into ARPE-19 cell culture medium and was compared to a control group using the Alamar Blue test and MTT cell proliferation assay to determine cell viability and proliferation. SECOND STEP: In vivo toxicity assessment Pilot study: New Zealand male albino rabbits (n=3): In the rabbit's right eyes, we performed a subconjunctival injection of 0.250 ml of PAMAM dendrimer-dextran, using a delivery system of twin syringes, one containing 15% PAMAM dendrimer and the other containing 7,5% dextran, with a mixing tip and a 30G needle. In the left eyes (controls), we performed a subconjunctival injection of 0,250 ml of balanced salt solution (BSS). THIRD STEP: conjugated polymer efficacy as a drug delivery system for dorzolamide injected in the subconjunctival site New Zealand male albino rabbits (n=10) Ten rabbits will be divided into two groups, group A (N=5) and group B (N=5). After 7 days of acclimation, Group A will receive the subconjunctival injection of the dorzolamide conjugated with the polymer (0,250ml) and group B will receive only the free polymer in their subconjunctiva. After 7 and 45 days, rabbits from each group will be subjected to clinical exams followed by aqueous humor sample collection (dorzolamide dosing by ELISA) and enucleation for histopathological, immunohistochemical and immunofluorescence evaluations.

**Results:** FIRST STEP ? IN VITRO TOXICITY Spectrophotometry analyses showed no significant difference between the cellular viability of ARPE-19 cells exposed to the PAMAM dendrimer-dextran medium compared to control (18.25% vs 18.05%). SECOND STEP ? IN VIVO TOXICITY Retinography, OCT and slit lamp examinations: The results showed no evident differences between eyes which underwent subconjunctival infection of the polymer and controls. ERG According to literature, we found the ERG to vary between different rabbits and in each animal between different recording sessions, especially for low amplitude responses, in most cases affecting both eyes<sup>4</sup>. Consequently, we adopted the a-wave and b-wave ratio (experimental eye/control eye), in light and dark-adapted phases as an index for retinal function<sup>4,5</sup>. Light adapted a-wave showed reduction from baseline to D14. HISTOPATHOLOGICAL EVALUATION (Hematoxylin-eosin stain): Rabbit 4: Moderate scleral lymphocytic infiltrate and myositis in the superior rectus muscle in the polymer injected eye, mild ciliary body inflammation and corneal endothelium cell loss on both eyes Rabbit 5: both eyes presented inflammatory cells on the conjunctiva, right eye also showed mild myositis of the superior rectus muscle, no corneal endothelial loss was observed Rabbit 6: Right eye showed corneal endothelial loss and mild aggregation of inflammatory cells on

**Conclusion:** - In vitro toxicity was not observed - Aberrant Cone function was found in the ERG examinations - The histopathologic analyses showed mild damage to the conjunctiva and moderate damage to the superior rectus muscles, which, in our evaluation, is due to the application site of the subconjunctival injection. - The high incidence of endothelial loss: IOP increase after the subconjunctival injection, or, as mentioned by the Pathology Department, it can be an unreliable finding since rabbit eyes are prone to technical challenges when making the histological piece for analyzes. Literature did not show a direct relation between subconjunctival injection and IOP

## 2019 Research Days Abstract Form

### 2. SCIENTIFIC SECTION PREFERENCE (REQUIRED):

Review the Scientific Section Descriptions. Select and enter the two-letter Code for the one (1) Section best suited to review your abstract.

**(BE) OCULAR BIOENGINEERING**

### 3. PRESENTATION PREFERENCE (REQUIRED)

Check one:

**(BE) OCULAR BIOENGINEERING**

4. The signature of the First (Presenting) Author (REQUIRED) acting as the authorized agent for all authors, hereby certifies that any research reported was conducted in compliance with the Declaration of Helsinki and the "UNIFESP Ethical Committee"

### Scientific Section Descriptions (two-letter code):

(BE) OCULAR BIOENGINEERING  
(CO) CORNEA AND EXTERNAL DISEASE  
(CA) CATARACT  
(EF) ELECTROPHYSIOLOGY  
(EP) EPIDEMIOLOGY  
(EX) EXPERIMENTAL SURGERY  
(GL) GLAUCOMA  
(LA) LABORATORY  
(LS) LACRIMAL SYSTEM  
(LV) LOW VISION  
(NO) NEURO-OPHTHALMOLOGY  
(OR) ORBIT  
(PL) OCULAR PLASTIC SURGERY  
(PH) PHARMACOLOGY  
(RE) RETINA AND VITREOUS  
(RS) REFRACTIVE SURGERY  
(RX) REFRACTION-CONTACT LENSES  
(ST) STRABISMUS  
(TR) TRAUMA  
(TU) TUMORS AND PATHOLOGY  
(UV) UVEITIS  
(US) OCULAR ULTRASOUND

Deadline: 10/2019

### FORMAT:

#### Abstract should contain:

Title  
Author  
Co-authors (maximum 6)  
Purpose  
Methods  
Results  
Conclusion  
Keywords

Poster guidelines:  
**90cm x 120cm**

### FIRST (PRESENTING) AUTHOR (REQUIRED):

**Name:** Aline Lutz De Araujo - PG1 - DO  
**e-mail:** alinelutz.a@gmail.com  
**CEP Number:** 1.571.558

### 5. ABSTRACT (REQUIRED):

**Title: The use of artificial intelligence to determine subjective refraction**

**Author and Co-authors:** Aline Lutz de Araujo, Henrique Dias, Daniel Sganzerla, Roberto Nunes Umpierre, Paulo Schor

**Purpose:** To test machine learning models to predict subjective ocular refraction from patient's demographics and ophthalmological data.

**Methods:** Dataset comprised data of 17,039 eyes from the TeleOftalmo, a teleophthalmology project in the Brazilian public health system. We collected the following variables to be tested as attributes in the predictive model: age, gender, race, symptoms (main complaint), uncorrected visual acuity, best corrected visual acuity, pinhole visual acuity, intraocular pressure (Visuplan, Zeiss, Germany), keratometry measurements and automatic refraction (Visuref, Zeiss, Germany). Same-day subjective refraction performed by an ophthalmologist was defined as the target attribute. We used the Orange Data Mining toolbox in Python to run tests with the following learning algorithms: random forest, neural network and linear regression. Mean absolute error (MAE) of these algorithms in predicting spherical equivalent was assessed. Subsequently, a classification algorithm was used to identify cases in which the prediction would fall within 0.5 diopter of error, defined as inlier cases. For comparison purposes, we determined the difference between automatic refraction and subjective refraction without the prediction model. We used student t test for dependent samples for statistical comparison.

**Results:** Spherical equivalent's MAE was 0.33, 0.37, and 0.44 diopters respectively with the random forest, neural network and linear regression. Attributes that had a better prediction ranking were: automatic refraction's spherical power, automatic refraction's axis, and steeper keratometry. Classification algorithm identified 85% of cases as inliers (F-measure 82%, AUC 70%). When the random forest algorithm was applied only to inlier cases, spherical equivalent's MAE reduced to 0.18 diopters. Without any algorithm, the difference between automatic refraction and subjective refraction was 0.71 diopters in spherical equivalent. Comparing automatic refraction alone and the prediction model, the latter had a lower mean error ( $p < 0,01$ ).

**Conclusion:** Artificial intelligence can accurately predict subjective refraction from clinical data in 85% of cases, with a mean absolute error of 0.18 diopters in spherical equivalent. Predicted subjective refraction had a significantly lower error than automatic refraction alone.

**Keywords:** ocular refraction, machine learning, artificial intelligence

## 2019 Research Days Abstract Form

### 2. SCIENTIFIC SECTION PREFERENCE (REQUIRED):

Review the Scientific Section Descriptions. Select and enter the two-letter Code for the one (1) Section best suited to review your abstract.

**(BE) OCULAR BIOENGINEERING**

### 3. PRESENTATION PREFERENCE (REQUIRED)

Check one:

**(BE) OCULAR BIOENGINEERING**

4. The signature of the First (Presenting) Author (REQUIRED) acting as the authorized agent for all authors, hereby certifies that any research reported was conducted in compliance with the Declaration of Helsinki and the "UNIFESP Ethical Committee"

### Scientific Section Descriptions (two-letter code):

(BE) OCULAR BIOENGINEERING  
(CO) CORNEA AND EXTERNAL DISEASE  
(CA) CATARACT  
(EF) ELECTROPHYSIOLOGY  
(EP) EPIDEMIOLOGY  
(EX) EXPERIMENTAL SURGERY  
(GL) GLAUCOMA  
(LA) LABORATORY  
(LS) LACRIMAL SYSTEM  
(LV) LOW VISION  
(NO) NEURO-OPHTHALMOLOGY  
(OR) ORBIT  
(PL) OCULAR PLASTIC SURGERY  
(PH) PHARMACOLOGY  
(RE) RETINA AND VITREOUS  
(RS) REFRACTIVE SURGERY  
(RX) REFRACTION-CONTACT LENSES  
(ST) STRABISMUS  
(TR) TRAUMA  
(TU) TUMORS AND PATHOLOGY  
(UV) UVEITIS  
(US) OCULAR ULTRASOUND

Deadline: 10/2019

### FORMAT:

**Abstract should contain:**

Title  
Author  
Co-authors (maximum 6)  
Purpose  
Methods  
Results  
Conclusion  
Keywords

Poster guidelines:  
**90cm x 120cm**

### FIRST (PRESENTING) AUTHOR (REQUIRED):

**Name:** Thiago Gonçalves S. Martins - PG1 - DO  
**e-mail:** thiagogsmartins@yahoo.com.br  
**CEP Number:** 20541030

### 5. ABSTRACT (REQUIRED):

**Title: A deep learning algorithm for automated detection of chorioretinal diseases**

**Author and Co-authors:** Thiago Goncalves dos Santos Martins, Rufino Silva, Karstern Körtum, Andreas Anschutz, Christoph Kern , Leoni Keidel, Claudia Farinha,Luis Guilherme Arneiro Mendes ,Olle Holmberg,Michael Hafner, Paulo Schor

**Purpose:** Develop a deep learning algorithm for automated detection of chorioretinal diseases.

**Methods:** Retina specialist diagnosed OCT images. /e diagnoses involved normal eyes and those with wet age related macular degeneration (AMD) , diabetic retinopathy (DR) , epiretinal membranes , and chorioretinal diseases.The images were used for deep learning training,

**Results:** Several deep learning architectures were implemented to perform the automatic detection drusen, fluids, and membranes. Ensembles of deep learning architectures are also being explored in order to improve the robustness of the classifiers. . The generation of additional data based on actual data (data augmented) is also being used for training the models. Due to the characteristics of the OCT B-scans images, specific data augmented methods were implemented which include the generation of B-scans with different levels of noise and the generation of vertical translation with the preservation of the image characteristics in the padded regions. Related with the development of the method for segmentation of the OCT layers deep learning architectures are being implemented for the detection of major layers disorganization. Based on the degree of the disorganization of the layers and the presence of lesions, the segmentation method will be choice and the parameters optimized. Deep learning architectures specialized in segmentation are also being implemented. The validation of the methods will be based on cross-validation

**Conclusion:** Automated detection of macular diseases from OCT images might be feasible using the convolutional neural network model. Image augmentation might be effective to compensate for a small image number for training.

**Keywords:** Artificial intelligence,macular degeneration,diabetic retinopathy,optical coherence tomography

## 2019 Research Days Abstract Form

### 2. SCIENTIFIC SECTION PREFERENCE (REQUIRED):

Review the Scientific Section Descriptions. Select and enter the two-letter Code for the one (1) Section best suited to review your abstract.

**(CA) CATARACT**

### 3. PRESENTATION PREFERENCE (REQUIRED)

Check one:

**(BE) OCULAR BIOENGINEERING**

4. The signature of the First (Presenting) Author (REQUIRED) acting as the authorized agent for all authors, hereby certifies that any research reported was conducted in compliance with the Declaration of Helsinki and the "UNIFESP Ethical Committee"

### Scientific Section Descriptions (two-letter code):

(BE) OCULAR BIOENGINEERING  
(CO) CORNEA AND EXTERNAL DISEASE  
(CA) CATARACT  
(EF) ELECTROPHYSIOLOGY  
(EP) EPIDEMIOLOGY  
(EX) EXPERIMENTAL SURGERY  
(GL) GLAUCOMA  
(LA) LABORATORY  
(LS) LACRIMAL SYSTEM  
(LV) LOW VISION  
(NO) NEURO-OPHTHALMOLOGY  
(OR) ORBIT  
(PL) OCULAR PLASTIC SURGERY  
(PH) PHARMACOLOGY  
(RE) RETINA AND VITREOUS  
(RS) REFRACTIVE SURGERY  
(RX) REFRACTION-CONTACT LENSES  
(ST) STRABISMUS  
(TR) TRAUMA  
(TU) TUMORS AND PATHOLOGY  
(UV) UVEITIS  
(US) OCULAR ULTRASOUND

Deadline: 10/2019

### FORMAT:

#### Abstract should contain:

Title  
Author  
Co-authors (maximum 6)  
Purpose  
Methods  
Results  
Conclusion  
Keywords

Poster guidelines:  
**90cm x 120cm**

### FIRST (PRESENTING) AUTHOR (REQUIRED):

**Name:** Victor Dias Bergamasco - PG1 - DO  
**e-mail:** vbergama@hotmail.com  
**CEP Number:** 0760/2016

### 5. ABSTRACT (REQUIRED):

**Title: ARTIFICIAL INTRAOCULAR LENS SUPPORT: A NEW DEVICE**

**Author and Co-authors:** VICTOR DIAS BERGAMASCO MAURO CAMPOS LINCON DE FREITAS VAGNER ROGERIO DOS SANTOS WALTON NOSÉ

**Purpose:** TO DEVELOP AN ARTIFICIAL INTRAOCULAR LENS SUPPORT FOR APHAKIC PATIENTS WITHOUT CAPSULAR BAG SUPPORT AND TEST IT IN CADAVERIC PORCINE EYES AND CADAVERIC HUMAN EYES.

**Methods:** THIS IS A DESCRIPTIVE STUDY IN WHICH THE AUTHORS HAD DOCUMENTED EVERY FASE OF THE DEVELOPMENT OF A NEW OPHTHALMIC SURGICAL DEVICE. THE IDEALIZATION, CREATION AND MATERIALIAZATION OF THE FIRST PROTOTYPE AND THE FURTHER MODIFICATIONS IN DESIGN, MATERIALS AND TECHNICS WERE DOCUMENTED IN VIDEOS, PHOTOS AND FORMS. EVERY NEW VERSION WAS EVALUATED DURING EXPERIMENTAL SURGERIES IN CADAVERIC PORCINE EYES. A FORM WAS CREATED TO COLECT DATA FROM EVERY EXPERIMENTAL SURGERY SO THE AUTHORS COULD ANALYSE THE PROGRESS AND SUGGEST MODIFICATIONS ON THE PROTOTYPE. THE FORM SCORES FROM 1-5 THE MAIN ASPECTS OF EACH PROTOTYPE VERSION SUCH AS MALLEABILITY, RESISTENCE, DESIGN, PROPORTIONS, EASE TO HANDLE AND IMPLANT, INTRAOCULAR LENS HOUSING AND OTHERS. IF SCORE IS LOWER THAN 4 THAT ASPECT IS POINTED AS A FAILURE AND THE PROTOTYPE IS REDESIGN TO FULFILL IT. BASED ON THE SCORES ACHIEVED, AJUSTMENTS WERE MADE FOR THE VERSION TO COME. Patent pending BR 20 2016 021940-5

**Results:** STUDY STILL IN PROGRESS. CADAVERIC HUMAN EYE TESTING WAS PERFORMED BUT THE DEVICE STILL DID NOT REACH ITS PURPOSE DUE TO SOME DESIGN ISSUES. THE AUTHORS HAVE ACHIEVED THE DEVELOPMENT OF A PROTOTYPE IN WHICH MOST OF THE RELEVANT ASPECTS SATISFIES THE PURPOSE IN EXPERIMENTAL SURGERIES IN CADAVERIC PORCINE EYES. IOL HOUSING STILL INAPPROPRIATE IN TESTS USING CADAVERIC HUMAN EYES.

**Conclusion:** GREAT ACOMPLISHMENTS WERE MADE AT THIS POINT IN TERMS OF DESIGN, MATERIALS AND TECHNICS IN CADAVERIC PORCINE EYES EXPERIMENTAL SURGERIES. IN CADAVERIC HUMAN EYES IOL HOUSING WAS NOT POSSIBLE AND MODIFICATIONS IN DESIGN AND PROPORTIONS ARE THE NEXT STEP OF THIS RESEARCH. "This study was financed in part by the Coordenação de Aperfeiçoamento de Pessoal de Nível Superior - Brasil (CAPES) - Finance Code 001"

**Keywords:** APHAKIA, PSUDOPHAKIA, INTRAOCULAR LENS

## 2019 Research Days Abstract Form

### 2. SCIENTIFIC SECTION PREFERENCE (REQUIRED):

Review the Scientific Section Descriptions. Select and enter the two-letter Code for the one (1) Section best suited to review your abstract.

**(RS) REFRACTIVE SURGERY**

### 3. PRESENTATION PREFERENCE (REQUIRED)

Check one:

**(RS) REFRACTIVE SURGERY**

4. The signature of the First (Presenting) Author (REQUIRED) acting as the authorized agent for all authors, hereby certifies that any research reported was conducted in compliance with the Declaration of Helsinki and the "UNIFESP Ethical Committee"

### Scientific Section Descriptions (two-letter code):

(BE) OCULAR BIOENGINEERING  
(CO) CORNEA AND EXTERNAL DISEASE  
(CA) CATARACT  
(EF) ELECTROPHYSIOLOGY  
(EP) EPIDEMIOLOGY  
(EX) EXPERIMENTAL SURGERY  
(GL) GLAUCOMA  
(LA) LABORATORY  
(LS) LACRIMAL SYSTEM  
(LV) LOW VISION  
(NO) NEURO-OPHTHALMOLOGY  
(OR) ORBIT  
(PL) OCULAR PLASTIC SURGERY  
(PH) PHARMACOLOGY  
(RE) RETINA AND VITREOUS  
(RS) REFRACTIVE SURGERY  
(RX) REFRACTION-CONTACT LENSES  
(ST) STRABISMUS  
(TR) TRAUMA  
(TU) TUMORS AND PATHOLOGY  
(UV) UVEITIS  
(US) OCULAR ULTRASOUND

Deadline: 10/2019

### FORMAT:

#### Abstract should contain:

Title  
Author  
Co-authors (maximum 6)  
Purpose  
Methods  
Results  
Conclusion  
Keywords

Poster guidelines:  
**90cm x 120cm**

### FIRST (PRESENTING) AUTHOR (REQUIRED):

**Name:** Marcella Q. Salomão Hoyer De Carvalho - PG1 - DO  
**e-mail:** marcella@barravisioncenter.com  
**CEP Number:** 2.568.770

### 5. ABSTRACT (REQUIRED):

#### Title: THE ROLE OF CORNEAL BIOMECHANICS FOR THE EVALUATION OF ECTASIA

**Author and Co-authors:** Marcella Q. Salomão, MD, Ana Luisa Hoffling- Lima, MD, PhD, Louise Pellegrino Gomes, Bernardo Lopes, Riccardo Vinciguerra, Paolo Vinciguerra, Nelson Sena Jr, Renato Ambrósio Jr, MD, PhD

**Purpose:** To prospectively review the role of corneal biomechanics for the clinical evaluation of patients with ectatic corneal diseases

**Methods:** Literature review and analysis of a published cohort of cases, along with anecdotal clinical examples. A total of 1,295 eyes were included for analysis. The normal group (group N) included one eye randomly selected from 736 patients with healthy corneas, the keratoconus group (group KC) included one eye randomly selected from 321 patients with keratoconus. The 113 non-operated ectatic eyes from 125 patients with very asymmetric ectasia (group VAE- E), whose fellow eyes presented relatively normal topography (group VAE- NT) were also included. Pentacam HR and Corvis ST (Oculus Optikgeräte GmbH, Wetzlar, Germany) parameters were evaluated. The accuracies of the tested variables for distinguishing all cases (KC, VAE-E and VAE-NT), for detecting clinical ectasia (KC + VAE-E) and for identifying abnormalities among the VAE-NT were investigated. A comparison was performed considering the areas under the receiver operating characteristic curve (AUC; deLong's method).

**Results:** Considering all cases ( KC, VAE-E and VAE-NT), the AUC of the TBI was 0.992, which was statistically higher than all parameters (DeLong's;  $p < 0.05$ ): PRFI (0.982), BAD-D (0,959), CBI (0,91), and IS Abs (0,91). The AUC of the TBI for detecting clinical ectasia (KC + VAE-E) was 0.999, and this was statistically higher than all parameters (DeLong's;  $p < 0.05$ ): PRFI (0.996), BAD-D (0.995), CBI ( 0.949), and IS Abs (0.977). Considering the VAE-NT group, the AUC of the TBI was 0.966, which was also statistically higher than all parameters (DeLong's;  $p < 0.05$ ): PRFI (0.934), BAD- D (0,834), CBI (0,774), and IS Abs (0,677).

**Conclusion:** Corneal biomechanical data enhances the evaluation of patients with corneal ectasia and meaningfully adds to the multimodal diagnostic armamentarium. The integration of biomechanical data with corneal tomography with artificial intelligence data augments the sensitivity and specificity for screening and enhancing early diagnosis. Besides, corneal biomechanics may be relevant for determining the prognosis, staging the disease, and for customizing the treatment planning.

**Keywords:** keratoconus, corneal biomechanics, forme fruste keratoconus



## 2019 Research Days Abstract Form

### 2. SCIENTIFIC SECTION PREFERENCE (REQUIRED):

Review the Scientific Section Descriptions. Select and enter the two-letter Code for the one (1) Section best suited to review your abstract.

**(PL) OCULOPLASTICS SURGERY**

### 3. PRESENTATION PREFERENCE (REQUIRED)

Check one:

**(PL) OCULOPLASTICS SURGERY**

4. The signature of the First (Presenting) Author (REQUIRED) acting as the authorized agent for all authors, hereby certifies that any research reported was conducted in compliance with the Declaration of Helsinki and the "UNIFESP Ethical Committee"

### Scientific Section Descriptions (two-letter code):

(BE) OCULAR BIOENGINEERING  
(CO) CORNEA AND EXTERNAL DISEASE  
(CA) CATARACT  
(EF) ELECTROPHYSIOLOGY  
(EP) EPIDEMIOLOGY  
(EX) EXPERIMENTAL SURGERY  
(GL) GLAUCOMA  
(LA) LABORATORY  
(LS) LACRIMAL SYSTEM  
(LV) LOW VISION  
(NO) NEURO-OPHTHALMOLOGY  
(OR) ORBIT  
(PL) OCULAR PLASTIC SURGERY  
(PH) PHARMACOLOGY  
(RE) RETINA AND VITREOUS  
(RS) REFRACTIVE SURGERY  
(RX) REFRACTION-CONTACT LENSES  
(ST) STRABISMUS  
(TR) TRAUMA  
(TU) TUMORS AND PATHOLOGY  
(UV) UVEITIS  
(US) OCULAR ULTRASOUND

Deadline: 10/2019

### FORMAT:

#### Abstract should contain:

Title  
Author  
Co-authors (maximum 6)  
Purpose  
Methods  
Results  
Conclusion  
Keywords

Poster guidelines:  
**90cm x 120cm**

### FIRST (PRESENTING) AUTHOR (REQUIRED):

**Name:** Cristina Yabumoto - PG1 - DO  
**e-mail:** crisyabumoto@yahoo.com.br  
**CEP Number:** 0534/2018

### 5. ABSTRACT (REQUIRED):

**Title: Effect of botulinum toxin injections on the tear film of patients with essential blepharospasm ? preliminary results**

**Author and Co-authors:** Cristina Yabumoto, Tammy H.Osaki, Midori H. Osaki, Mauro Campos

**Purpose:** To evaluate the effect of botulinum toxin injections on the tear film of patients with essential blepharospasm using the corneal topographer Keratograph 5M and Fluorescein breakup time (FBUT).

**Methods:** A prospective study was performed on 18 eyes of 9 patients with blepharospasm who underwent treatment with botulinum toxin injections. All the eyes were imaged using the noninvasive tear breakup time tools of the Keratograph 5M. The FBUT was also evaluated. The following parameters were recorded in each patient before and 15 days after botulinum toxin injections: first noninvasive Keratograph 5M tear breakup time (the time at which the first breakup of tear occurs), average noninvasive Keratograph 5M tear breakup time (the average time of all breakup incidents) and the FBUT. Student's t-test was used to compare the values of first and average noninvasive Keratograph 5M tear breakup times and FBUT before and 15 days after the injections.

**Results:** The mean age of the patients was 68.1 years (SD 13.15), 66% were female. No statistically significant differences were observed for first noninvasive Keratograph 5M tear breakup time before and 15 days after the injections (8.52 seconds SD 5.49 and 7.65 seconds SD 4.75 respectively,  $p = 0.61$ ), for average noninvasive Keratograph 5M tear breakup time before and 15 days after the injections (12.12 seconds SD 5.36 and 14.21 seconds SD 5.71 respectively,  $p=0.26$ ) and for FBUT before and 15 days after the injections (4.5 seconds SD 1.69 and 4.94 seconds SD 1.43 respectively,  $p = 0.40$ ).

**Conclusion:** Our preliminary results apparently suggest that botulinum toxin injections do not affect the tear breakup time in essential blepharospasm patients, assessed with the objective evaluation of the Keratograph 5M, and with the traditional Fluorescein breakup time (FBUT) method. However, a higher sample is needed to permit further considerations. Financial support: CAPES

**Keywords:** botulinum toxin; essential blepharospasm; tear breakup time

## 2019 Research Days Abstract Form

### 2. SCIENTIFIC SECTION PREFERENCE (REQUIRED):

Review the Scientific Section Descriptions. Select and enter the two-letter Code for the one (1) Section best suited to review your abstract.

**(PL) OCULOPLASTICS SURGERY**

### 3. PRESENTATION PREFERENCE (REQUIRED)

Check one:

**(PL) OCULOPLASTICS SURGERY**

4. The signature of the First (Presenting) Author (REQUIRED) acting as the authorized agent for all authors, hereby certifies that any research reported was conducted in compliance with the Declaration of Helsinki and the "UNIFESP Ethical Committee"

### Scientific Section Descriptions (two-letter code):

(BE) OCULAR BIOENGINEERING  
(CO) CORNEA AND EXTERNAL DISEASE  
(CA) CATARACT  
(EF) ELECTROPHYSIOLOGY  
(EP) EPIDEMIOLOGY  
(EX) EXPERIMENTAL SURGERY  
(GL) GLAUCOMA  
(LA) LABORATORY  
(LS) LACRIMAL SYSTEM  
(LV) LOW VISION  
(NO) NEURO-OPHTHALMOLOGY  
(OR) ORBIT  
(PL) OCULAR PLASTIC SURGERY  
(PH) PHARMACOLOGY  
(RE) RETINA AND VITREOUS  
(RS) REFRACTIVE SURGERY  
(RX) REFRACTION-CONTACT LENSES  
(ST) STRABISMUS  
(TR) TRAUMA  
(TU) TUMORS AND PATHOLOGY  
(UV) UVEITIS  
(US) OCULAR ULTRASOUND

Deadline: 10/2019

### FORMAT:

#### Abstract should contain:

Title  
Author  
Co-authors (maximum 6)  
Purpose  
Methods  
Results  
Conclusion  
Keywords

Poster guidelines:  
**90cm x 120cm**

### FIRST (PRESENTING) AUTHOR (REQUIRED):

**Name:** Midori Hentona Osaki - PG1 - DO  
**e-mail:** midori\_osaki@yahoo.com.br  
**CEP Number:** 1024/09

### 5. ABSTRACT (REQUIRED):

**Title:** Histopathological analysis of orbicularis oculi muscle in hemifacial spasm patients

**Author and Co-authors:** Osaki MH, Osaki TH, Osaki T, Gameiro G, Marie SKN, Belfort Jr R.

**Purpose:** To objectively evaluate and compare orbicularis oculi samples of non-previous botulinum toxin-treated hemifacial spasm and control patients.

**Methods:** Orbicularis oculi samples from 22 eyelids were evaluated: (1) 7 samples from the affected and 7 samples from the non-affected side of hemifacial spasm patients who had not been previously treated and (2) 8 samples from normal control patients. Muscle samples were prepared using hematoxylin and eosin staining, and a digital image analysis software (Image J, of Image J, version 1.34s) was used for objective analysis.

**Results:** When compared to normal controls, endomysial and perimysial connective tissue areas were significantly increased ( $p=0.015$ ) on the affected side, suggesting that hemifacial spasm is associated with chronic alterations, leading to muscle degeneration. Cell density was observed to be significantly reduced on the affected ( $p=0.028$ ) and also on the non-affected side ( $p=0.003$ ), when compared to normal controls, although clinically, there were no signs or symptoms of increased muscular contraction on the non-affected side in any of the hemifacial spasm patients studied.

**Conclusion:** Significant morphological differences in the orbicularis oculi muscle in hemifacial spasm patients were observed, on both the affected and non-affected sides. Our findings suggest that some type of muscle homeostasis disturbance may be present in both sides, however, on the non-affected side, it would not be substantial enough to lead to muscle degeneration, as observed on the affected side.

**Keywords:** Hemifacial spasm, orbicularis oculi, histopathology

## 2019 Research Days Abstract Form

### 2. SCIENTIFIC SECTION PREFERENCE (REQUIRED):

Review the Scientific Section Descriptions. Select and enter the two-letter Code for the one (1) Section best suited to review your abstract.

**(EF)**  
**ELECTROPHYSIOLOGY**

### 3. PRESENTATION PREFERENCE (REQUIRED)

Check one:

**(EF)**  
**ELECTROPHYSIOLOG**  
**V**

4. The signature of the First (Presenting) Author (REQUIRED) acting as the authorized agent for all authors, hereby certifies that any research reported was conducted in compliance with the Declaration of Helsinki and the "UNIFESP Ethical Committee"

### Scientific Section Descriptions (two-letter code):

(BE) OCULAR BIOENGINEERING  
(CO) CORNEA AND EXTERNAL DISEASE  
(CA) CATARACT  
(EF) ELECTROPHYSIOLOGY  
(EP) EPIDEMIOLOGY  
(EX) EXPERIMENTAL SURGERY  
(GL) GLAUCOMA  
(LA) LABORATORY  
(LS) LACRIMAL SYSTEM  
(LV) LOW VISION  
(NO) NEURO-OPHTHALMOLOGY  
(OR) ORBIT  
(PL) OCULAR PLASTIC SURGERY  
(PH) PHARMACOLOGY  
(RE) RETINA AND VITREOUS  
(RS) REFRACTIVE SURGERY  
(RX) REFRACTION-CONTACT LENSES  
(ST) STRABISMUS  
(TR) TRAUMA  
(TU) TUMORS AND PATHOLOGY  
(UV) UVEITIS  
(US) OCULAR ULTRASOUND

Deadline: 10/2019

### FORMAT:

#### Abstract should contain:

Title  
Author  
Co-authors (maximum 6)  
Purpose  
Methods  
Results  
Conclusion  
Keywords

Poster guidelines:  
**90cm x 120cm**

### FIRST (PRESENTING) AUTHOR (REQUIRED):

**Name:** Gabriel Izan Santos Botelho - PG1 - DO  
**e-mail:** gabrielbotelho\_@hotmail.com  
**CEP Number:** 0551/2018

### 5. ABSTRACT (REQUIRED):

**Title:** INTER-SESSION RELIABILITY AND NORMAL VALUES OF THE ELECTRORETINOGRAM PHOTOPIC NEGATIVE RESPONSE (PHNR) IN HEALTHY ADULTS

**Author and Co-authors:** Gabriel I. S. Botelho, Solange R. Salomão, Arthur G. Fernandes, Adriana Berezovsky

**Purpose:** To determine normative values and test-retest reliability for a range of parameters derived from the photopic negative response (PhNR) in healthy normal adults.

**Methods:** Light-adapted flash full-field electroretinograms (ERGs) were recorded from a randomly-selected eye of 50 subjects (16-55 years, mean 28.8± 10.1, 30 females), and 13 of them were tested on two separate days. Stimuli were brief 1 cd/s/m<sup>2</sup> red flashes (<'5ms) on a 10 cd/m<sup>2</sup> blue background. PhNR amplitude (µV) was measured using through to baseline (BT) and from the preceding b-wave peak (PT). BT/b and PT/b amplitude ratios were also calculated. Normal limits were determined as 5% percentile for amplitudes and 95% percentile for latencies. Test-retest reliability was assessed with Wilcoxon signed-rank test, intraclass correlation coefficient (ICC) and the coefficient of reliability (COR).

**Results:** Mean PhNR amplitude (µV) and lower limit were respectively 26.26±5.30, 21.15 for BT, 114.27±34.49, 69.30 for PT, 1.33±0.12, 1.16 for PT/b and 0.33±0.12, 0.16 for BT/b. Mean PhNR latency (ms) and normal limit was 60.65±2.52, 65.33. There were no significant differences between test-retest for all PhNR measurements. For PhNR, the most reliable measurement was PT (ICC, 0.86, CoR%, 9.06%) followed by BT (ICC, 0.84, CoR%, 27.01%). The PT/b was more reproduced (ICC, 0.73, CoR%, 9.43) than all other PhNR measurement parameters.

**Conclusion:** The normative values provided by this study will be clinically useful to help in the diagnosis of innermost retinal disorders, especially those affecting retinal ganglion cells as glaucoma and other forms of optic neuropathy. PT/b amplitude ratio showed less variability and might be a more consistent measure than absolute PhNR amplitude. Further studies including a larger sample with variable age range are desirable to confirm and extend the current results.

**Keywords:** Photopic negative response, Electroretinogram

## 2019 Research Days Abstract Form

### 2. SCIENTIFIC SECTION PREFERENCE (REQUIRED):

Review the Scientific Section Descriptions. Select and enter the two-letter Code for the one (1) Section best suited to review your abstract.

**(EF)  
ELECTROPHYSIOLOGY**

### 3. PRESENTATION PREFERENCE (REQUIRED)

Check one:

**(EF)  
ELECTROPHYSIOLOG  
V**

4. The signature of the First (Presenting) Author (REQUIRED) acting as the authorized agent for all authors, hereby certifies that any research reported was conducted in compliance with the Declaration of Helsinki and the 'UNIFESP Ethical Committee'

### Scientific Section Descriptions (two-letter code):

(BE) OCULAR BIOENGINEERING  
(CO) CORNEA AND EXTERNAL DISEASE  
(CA) CATARACT  
(EF) ELECTROPHYSIOLOGY  
(EP) EPIDEMIOLOGY  
(EX) EXPERIMENTAL SURGERY  
(GL) GLAUCOMA  
(LA) LABORATORY  
(LS) LACRIMAL SYSTEM  
(LV) LOW VISION  
(NO) NEURO-OPHTHALMOLOGY  
(OR) ORBIT  
(PL) OCULAR PLASTIC SURGERY  
(PH) PHARMACOLOGY  
(RE) RETINA AND VITREOUS  
(RS) REFRACTIVE SURGERY  
(RX) REFRACTION-CONTACT LENSES  
(ST) STRABISMUS  
(TR) TRAUMA  
(TU) TUMORS AND PATHOLOGY  
(UV) UVEITIS  
(US) OCULAR ULTRASOUND

Deadline: 10/2019

### FORMAT:

#### Abstract should contain:

Title  
Author  
Co-authors (maximum 6)  
Purpose  
Methods  
Results  
Conclusion  
Keywords

Poster guidelines:  
**90cm x 120cm**

### FIRST (PRESENTING) AUTHOR (REQUIRED):

**Name:** Tarciana De Souza Soares - PG1 - DO  
**e-mail:** sstarciiana@yahoo.com.br  
**CEP Number:** 1.763.153

### 5. ABSTRACT (REQUIRED):

#### **Title: PATTERN-REVERSAL VISUAL EVOKED POTENTIALS IN UNILATERAL VISUAL IMPAIRMENT AND MALINGERING**

**Author and Co-authors:** Tarciana Soares, Adriana Berezovsky, Solange Salomão

**Purpose:** To investigate the clinical usefulness of pattern-reversal visually evoked potentials (PRVEPs) in patients with and without reliable optotype acuity (VA) reduction.

**Methods:** Two groups of patients were retrospectively analyzed. Group A: 8 patients (5 females) with reliable optotype acuity and unilateral ocular disease with VA ? 20/20 in the better-seeing eye (BSE) and VA? 20/32 in the worse-seeing eye (WSE) and Group B: 5 patients (3 females) previously diagnosed as malingerers in both eyes by objectively measured grating acuity (20/40 or better) assessed by sweep-VEP. Transient PRVEPs were obtained from each eye using two check sizes (15? and 60?) with amplitude ( $\mu$ V) and latency (ms) determined for P100. Statistical analysis was performed to investigate the correlation between VA and VEP parameters (p value '<'.05 was considered significant).

**Results:** Group A with VA in BSE ranging from -0.1 to 0.04 logMAR (mean=0.0 $\pm$ 0.04, median=0.0) and in WSE from 0.2 to 1.6 logMAR (mean=0.9 $\pm$ 0.45, median=0.9). Mean P100 amplitude for 15? and 60? checks in the BSE were respectively, 11.5 $\pm$  4.20  $\mu$ V and 11.16 $\pm$  3.96  $\mu$ V. Mean latency for 15? and 60? stimuli were, respectively, 96.6 $\pm$  5.0 ms and 97.2 $\pm$  4.5 ms. In the WSE mean P100 amplitude 15? and 60? checks were respectively, 6.02 $\pm$  2.89  $\mu$ V and 6.63  $\pm$ 4.81 $\mu$ V, whereas mean latency were 108.7 $\pm$ 12.5 ms and 107.6 $\pm$ 11.3 ms. In Group B mean P100 amplitude for 15? and 60? checks were respectively, 11.3 $\pm$ 2.52  $\mu$ V and 9.7 $\pm$ 3.17  $\mu$ V, whereas mean latency was 97.3 $\pm$ 8.2 ms and 95.4 $\pm$ 6ms. In Group A, considering the WSE, VA was positively correlated (r=0.75, p-value=0.084) with P100 latency (ms) for 15? checks and negatively correlated with P100 amplitude for 60? checks (r=-0.71, p= 0.04). In Group B objective VA was negatively correlated with P100 latency for both smaller (r= -0.68, p= 0.029) and larger checks (r =-0.81, p= 0.0048).

**Conclusion:** Clinical usefulness of VEP testing in the diagnosis of malingering was confirmed by PRVEP decreased amplitudes and prolonged latencies correlated with unilateral VA reduction in patients with reliable optotype acuity.

**Keywords:** VA, latency, amplitude, Visually evoked potentials

## 2019 Research Days Abstract Form

### 2. SCIENTIFIC SECTION PREFERENCE (REQUIRED):

Review the Scientific Section Descriptions. Select and enter the two-letter Code for the one (1) Section best suited to review your abstract.

**(EP) EPIDEMIOLOGY**

### 3. PRESENTATION PREFERENCE (REQUIRED)

Check one:

**(EP) EPIDEMIOLOGY**

4. The signature of the First (Presenting) Author (REQUIRED) acting as the authorized agent for all authors, hereby certifies that any research reported was conducted in compliance with the Declaration of Helsinki and the "UNIFESP Ethical Committee"

### Scientific Section Descriptions (two-letter code):

(BE) OCULAR BIOENGINEERING  
(CO) CORNEA AND EXTERNAL DISEASE  
(CA) CATARACT  
(EF) ELECTROPHYSIOLOGY  
(EP) EPIDEMIOLOGY  
(EX) EXPERIMENTAL SURGERY  
(GL) GLAUCOMA  
(LA) LABORATORY  
(LS) LACRIMAL SYSTEM  
(LV) LOW VISION  
(NO) NEURO-OPHTHALMOLOGY  
(OR) ORBIT  
(PL) OCULAR PLASTIC SURGERY  
(PH) PHARMACOLOGY  
(RE) RETINA AND VITREOUS  
(RS) REFRACTIVE SURGERY  
(RX) REFRACTION-CONTACT LENSES  
(ST) STRABISMUS  
(TR) TRAUMA  
(TU) TUMORS AND PATHOLOGY  
(UV) UVEITIS  
(US) OCULAR ULTRASOUND

Deadline: 10/2019

### FORMAT:

#### Abstract should contain:

Title  
Author  
Co-authors (maximum 6)  
Purpose  
Methods  
Results  
Conclusion  
Keywords

Poster guidelines:  
**90cm x 120cm**

### FIRST (PRESENTING) AUTHOR (REQUIRED):

**Name:** Elmar Torres Neto - PG0 - DO  
**e-mail:** elmaroft@hotmail.com  
**CEP Number:** 110098/20

### 5. ABSTRACT (REQUIRED):

#### **Title: Teleophthalmology Support for Primary Care Diagnosis, Management and Results. (CATARACT)**

**Author and Co-authors:** Elmar Torres, MD,1,2 Paulo H. Morales, MD, PhD,1,2 Tamires H Silveira,1 and Rubens Belfort Jr, MD, PhD1,2,3

**Purpose:** To evaluate the effectiveness of tele-diagnostic screening for cataract in primary care centers.

**Methods:** Descriptive cross-sectional study. Medical records reviewed of patients above the age of 45, seen from January, 2016 to December, 2017 at 9 primary public care units (SUS) of São Paulo metropolitan area under care of the Health Secretary of the State of Sao Paulo. Patients with diabetes and blood hypertension had their eyes imaged by a non-medical health non-medical with a (Canon CR2, Tokyo, Japan) after instillation of tropicamide 1%. The data was sent by Internet and reviewed by an ophthalmologist at the Vision Institute- IPEPO reading center. Patients with imaging suggesting lens opacities hindering the visualization of the retina were diagnosed as potential cataract and invited to be seen by an ophthalmologist.

**Results:** A total of 17,590 patients were evaluated over a 2-year period. Of these, 3,663 (20,8%) patients presented ocular disease with the following suggestions-phacoemulsification for cataract in 2,093 (57.1%), laser treatment for diabetic retinopathy in 1,309 (35.7%), and indication of vitrectomy in 258 (7.1%) patients. Analyzing patients with indication for cataract surgery, 278 (13.2%) refused to consult or had no contact. For those who were in consultation we had a positive agreement was found in the surgical indication of 1546 (85.2%) of the patients of those 37 (2.4%) did not accept or could perform surgery and those who underwent surgery 1356 (89.9%) presented better vision than 20/60. Among the patients not indicated for cataract surgery there were 122 (6.7%) in which the vision was better than 20/60 with refraction, 147 (8.1%) from other diseases.

**Conclusion:** This diagnostic modality using tele-ophthalmology and health professions non-medical allowed the screening of patients with ocular diseases and specifically with cataract in primary health units. We had a positive correlation of 85% surgical indication of cataract demonstrating that this system can be an ally in screening patients in the public health system.

**Keywords:** teleophthalmology, cataract, retina, primary care

## 2019 Research Days Abstract Form

### 2. SCIENTIFIC SECTION PREFERENCE (REQUIRED):

Review the Scientific Section Descriptions. Select and enter the two-letter Code for the one (1) Section best suited to review your abstract.

**(US) OCULAR  
ULTRASOUND**

### 3. PRESENTATION PREFERENCE (REQUIRED)

Check one:

**(US) OCULAR  
ULTRASOUND**

4. The signature of the First (Presenting) Author (REQUIRED) acting as the authorized agent for all authors, hereby certifies that any research reported was conducted in compliance with the Declaration of Helsinki and the "UNIFESP Ethical Committee"

### Scientific Section Descriptions (two-letter code):

(BE) OCULAR BIOENGINEERING  
(CO) CORNEA AND EXTERNAL DISEASE  
(CA) CATARACT  
(EF) ELECTROPHYSIOLOGY  
(EP) EPIDEMIOLOGY  
(EX) EXPERIMENTAL SURGERY  
(GL) GLAUCOMA  
(LA) LABORATORY  
(LS) LACRIMAL SYSTEM  
(LV) LOW VISION  
(NO) NEURO-OPHTHALMOLOGY  
(OR) ORBIT  
(PL) OCULAR PLASTIC SURGERY  
(PH) PHARMACOLOGY  
(RE) RETINA AND VITREOUS  
(RS) REFRACTIVE SURGERY  
(RX) REFRACTION-CONTACT LENSES  
(ST) STRABISMUS  
(TR) TRAUMA  
(TU) TUMORS AND PATHOLOGY  
(UV) UVEITIS  
(US) OCULAR ULTRASOUND

Deadline: 10/2019

### FORMAT:

#### Abstract should contain:

Title  
Author  
Co-authors (maximum 6)  
Purpose  
Methods  
Results  
Conclusion  
Keywords

Poster guidelines:  
**90cm x 120cm**

### FIRST (PRESENTING) AUTHOR (REQUIRED):

**Name:** Ricardo Salles Cauduro - PG1 - DO  
**e-mail:** cauduro.ricardo@gmail.com  
**CEP Number:** 507907

### 5. ABSTRACT (REQUIRED):

**Title: Preterm infants Ocular Growth in a Neonatal Intensive Care Unit (ICU) environment**

**Author and Co-authors:** Cauduro RS, Goulart AL, Allemann N.

**Purpose:** To evaluate ocular biometric parameters, refractive errors and growth in a serial evaluation of preterm infants (weight at birth under 1500 g or premature birth at 32 gestational weeks).

**Methods:** Prospective study of a population of preterm infants in the neonatal ICU. Follow-up considering gestational age ranges in weeks : 26-27(t1), 28-29(t2), 30-31(t3), 32-33(t4), 34-35(t5), 36-37(t6), 38-39(t7), and 40-41(t8). Ocular biometric parameters (transpalpebral B-scan ultrasound, 7.5-15 MHz linear transducer, Mylab, Esaote) included: anterior chamber depth (ACD), lens thickness (L) and axial length (AL). Ophthalmological exam included refraction (retinoscopy, spherical equivalent) and indirect ophthalmoscopy (28 D lens), screening for ROP. Growth parameters evaluated included: head circumference, weight, height and Apgar score.

**Results:** 42 right eyes of premature infants were included (20 male, 22 female). ACD, L, and AL parameters showed an increase, however refractive spherical equivalent showed decrease during the follow-up at different gestational ages. - ACD (mm): t1=1.21(+/-0.12), t2=1.36(+/-0.06), t3=1.48(+/-0.04), t4=1.70(+/-0.04), t5=1.81(+/-0.04), t6=1.94(+/-0.04), t7=2.07(+/-0.12), t8=2.08(+/-0.12), - L (mm): t1=3.67(+/-0.08), t2=3.79(+/-0.05), t3=14.36(+/-0.10), t4=15.01(+/-0.10), t5=15.58(+/-0.10), t6=4.02(+/-0.03), t7=4.08(+/-0.04), t8=4.13(+/-0.09), - AL (mm): t1=13.82(+/-0.23), t2=13.97(+/-0.14), t3=1.48(+/-0.04), t4=1.70(+/-0.04), t5=1.81(+/-0.04), t6=16.11(+/-0.10), t7=16.36(+/-0.13), t8=16.97(+/-0.24), - Refraction (D): t1= - , t2=2.63(+/-0.33), t3=2.29(+/-0.19), t4=2.24(+/-0.19), t5=1.90(+/-0.21), t6=1.67(+/-0.21), t7=1.44(+/-0.27), t8=1.51(+/-0.54).

**Conclusion:** A second time analysis is currently underway evaluating these growth parameters in different gestational age ranges and comparisons between preterm infants with and without ROP groups to verify for a statistical difference in the present study.

**Keywords:** Anterior Chamber/anatomy & histology, Biometry, Birth Weight, Eye /growth & development, Eye / physiopathology, Gestational Age, Humans Infants, Newborn Infants, Premature Infant, Very Low Birth, Crystalline/anatomy & histology, Prospective Studies, Refra

## 2019 Research Days Abstract Form

### 2. SCIENTIFIC SECTION PREFERENCE (REQUIRED):

Review the Scientific Section Descriptions. Select and enter the two-letter Code for the one (1) Section best suited to review your abstract.

**(US) OCULAR  
ULTRASOUND**

### 3. PRESENTATION PREFERENCE (REQUIRED)

Check one:

**(US) OCULAR  
ULTRASOUND**

4. The signature of the First (Presenting) Author (REQUIRED) acting as the authorized agent for all authors, hereby certifies that any research reported was conducted in compliance with the Declaration of Helsinki and the "UNIFESP Ethical Committee"

### Scientific Section Descriptions (two-letter code):

(BE) OCULAR BIOENGINEERING  
(CO) CORNEA AND EXTERNAL DISEASE  
(CA) CATARACT  
(EF) ELECTROPHYSIOLOGY  
(EP) EPIDEMIOLOGY  
(EX) EXPERIMENTAL SURGERY  
(GL) GLAUCOMA  
(LA) LABORATORY  
(LS) LACRIMAL SYSTEM  
(LV) LOW VISION  
(NO) NEURO-OPHTHALMOLOGY  
(OR) ORBIT  
(PL) OCULAR PLASTIC SURGERY  
(PH) PHARMACOLOGY  
(RE) RETINA AND VITREOUS  
(RS) REFRACTIVE SURGERY  
(RX) REFRACTION-CONTACT LENSES  
(ST) STRABISMUS  
(TR) TRAUMA  
(TU) TUMORS AND PATHOLOGY  
(UV) UVEITIS  
(US) OCULAR ULTRASOUND

Deadline: 10/2019

### FORMAT:

#### Abstract should contain:

Title  
Author  
Co-authors (maximum 6)  
Purpose  
Methods  
Results  
Conclusion  
Keywords

Poster guidelines:  
**90cm x 120cm**

### FIRST (PRESENTING) AUTHOR (REQUIRED):

**Name:** Gabriela Assumpção Brito Pereira Pelegrini - PG1 - DO  
**e-mail:** gabriela.ofalmo@hotmail.com  
**CEP Number:** 18087-003

### 5. ABSTRACT (REQUIRED):

**Title: Ultrasonographic follow up of eyes with intravitreal dexamethasone implant (Ozurdex®)**

**Author and Co-authors:** Gabriela Assumpção Brito Pereira Pellegrini, Arnaldo Furman Bordon, Norma Allemann.

**Purpose:** To compare measurements and findings of the dexamethasone Ozurdex® implants in the vitreous cavity over time.

**Methods:** Eyes submitted to intravitreal Ozurdex implants were evaluated at day 1 after implantation and every 45 days until completing 6-months period using: B-scan ultrasonography (Aviso® and Compact Touch®, Quantel Medical) and wide-field fundus photography (California®, Optos). B-scan ultrasound parameters evaluated were position and dimensions of the implant.

**Results:** Eleven eyes of ten patients were included, 70% female. Major indication for treatment with Ozurdex® was diabetic macular edema (91%). Implant measurements varied over time: Length at Day 1 = 7.05+/-0.18mm and Final visit = 1.81+/- 0.51mm, Thickness at Day 1 = 0.75+/-0.02 and at Final visit = 0.3+/-0.02 mm. Reduction in the implants length over time was more evident. B-scan follow-up demonstrated fading of the implant's limits definition and lowering of the internal reflectivity. Most common location for the implants was inferior (82%). Fundus photography was able to demonstrate the implant in 56 % of the eyes evaluated.

**Conclusion:** Ongoing study showed progressive decrease in the implant measurements over the follow-up particularly in length. Qualitative changes of fading and lowering of internal reflectivity was detected over time. Ozurdex® intravitreal implants changes observed over time can be related to drug release.

**Keywords:** Ocular ultrasonography, eye, intravitreal dexamethasone implant.

## 2019 Research Days Abstract Form

### 2. SCIENTIFIC SECTION PREFERENCE (REQUIRED):

Review the Scientific Section Descriptions. Select and enter the two-letter Code for the one (1) Section best suited to review your abstract.

**(GL) GLAUCOMA**

### 3. PRESENTATION PREFERENCE (REQUIRED)

Check one:

**(GL) GLAUCOMA**

4. The signature of the First (Presenting) Author (REQUIRED) acting as the authorized agent for all authors, hereby certifies that any research reported was conducted in compliance with the Declaration of Helsinki and the "UNIFESP Ethical Committee"

### Scientific Section Descriptions (two-letter code):

(BE) OCULAR BIOENGINEERING  
(CO) CORNEA AND EXTERNAL DISEASE  
(CA) CATARACT  
(EF) ELECTROPHYSIOLOGY  
(EP) EPIDEMIOLOGY  
(EX) EXPERIMENTAL SURGERY  
(GL) GLAUCOMA  
(LA) LABORATORY  
(LS) LACRIMAL SYSTEM  
(LV) LOW VISION  
(NO) NEURO-OPHTHALMOLOGY  
(OR) ORBIT  
(PL) OCULAR PLASTIC SURGERY  
(PH) PHARMACOLOGY  
(RE) RETINA AND VITREOUS  
(RS) REFRACTIVE SURGERY  
(RX) REFRACTION-CONTACT LENSES  
(ST) STRABISMUS  
(TR) TRAUMA  
(TU) TUMORS AND PATHOLOGY  
(UV) UVEITIS  
(US) OCULAR ULTRASOUND

Deadline: 10/2019

### FORMAT:

#### Abstract should contain:

Title  
Author  
Co-authors (maximum 6)  
Purpose  
Methods  
Results  
Conclusion  
Keywords

Poster guidelines:  
**90cm x 120cm**

### FIRST (PRESENTING) AUTHOR (REQUIRED):

**Name:** Gabriel Ferrante Abou Murad - R2  
**e-mail:** murad.gabriel@gmail.com  
**CEP Number:** 4532/2019

### 5. ABSTRACT (REQUIRED):

**Title: Influence of phacoemulsification on intraocular pressure in patients with trabeculectomy**

**Author and Co-authors:** Gabriel Ferrante Abou Murad, Luiz Alberto Soares de Melo Junior

**Purpose:** To evaluate the change in intraocular pressure (IOP) after phacoemulsification surgery in patients with trabeculectomy

**Methods:** Data were retrieved from glaucoma service of the Escola Paulista de Medicina. We analyzed the medical records from January 2017 through July 2019 and collected twenty-one patients who had already undergone trabeculectomy surgery prior to phacoemulsification. IOP prior to phacoemulsification values were obtained, as well as in the first operative day, the seventh day, the second to third week, one month, and three months after phacoemulsification. Data on change of antiglaucoma medication to control the IOP were also collected.

**Results:** Data from 9 male patients (43%) and 12 female (57%) were collected. Fourteen (67%) patients had the diagnosis of primary open-angle glaucoma, six were classified as primary angle closure glaucoma (28.5%) and one had juvenile glaucoma (4.5%). All patients had undergone trabeculectomy at least six months prior to phacoemulsification. The mean ( $\pm$  standard deviation) IOP prior to surgery was of 11.9 mmHg ( $\pm$  2.8, median of 12 mmHg). The first postoperative day IOP pressure mean was 12.4 mmHg ( $\pm$  4.6, median of 12 mmHg). The seventh post-operative day IOP mean was 12.1 mmHg ( $\pm$  4.6 mmHg, median of 10 mmHg). The mean IOP from the second to third week was of 12.4 mmHg ( $\pm$  4.3, median of 12 mmHg). The mean IOP after one month of surgery was 14.1 mmHg ( $\pm$  4.5, median of 14 mmHg), and the three month postoperative IOP mean was 14.9 mmHg ( $\pm$  4.5, median of 15 mmHg). Seven patients (33%) required topical medication to control the IOP.

**Conclusion:** The IOP increased after phacoemulsification surgery in patients with trabeculectomy

**Keywords:** glaucoma, cataract extraction, trabeculectomy, intraocular pressure.



## 2019 Research Days Abstract Form

### 2. SCIENTIFIC SECTION PREFERENCE (REQUIRED):

Review the Scientific Section Descriptions. Select and enter the two-letter Code for the one (1) Section best suited to review your abstract.

**(GL) GLAUCOMA**

### 3. PRESENTATION PREFERENCE (REQUIRED)

Check one:

**(GL) GLAUCOMA**

4. The signature of the First (Presenting) Author (REQUIRED) acting as the authorized agent for all authors, hereby certifies that any research reported was conducted in compliance with the Declaration of Helsinki and the 'UNIFESP Ethical Committee'

### Scientific Section Descriptions (two-letter code):

(BE) OCULAR BIOENGINEERING  
(CO) CORNEA AND EXTERNAL DISEASE  
(CA) CATARACT  
(EF) ELECTROPHYSIOLOGY  
(EP) EPIDEMIOLOGY  
(EX) EXPERIMENTAL SURGERY  
(GL) GLAUCOMA  
(LA) LABORATORY  
(LS) LACRIMAL SYSTEM  
(LV) LOW VISION  
(NO) NEURO-OPHTHALMOLOGY  
(OR) ORBIT  
(PL) OCULAR PLASTIC SURGERY  
(PH) PHARMACOLOGY  
(RE) RETINA AND VITREOUS  
(RS) REFRACTIVE SURGERY  
(RX) REFRACTION-CONTACT LENSES  
(ST) STRABISMUS  
(TR) TRAUMA  
(TU) TUMORS AND PATHOLOGY  
(UV) UVEITIS  
(US) OCULAR ULTRASOUND

Deadline: 10/2019

### FORMAT:

#### Abstract should contain:

Title  
Author  
Co-authors (maximum 6)  
Purpose  
Methods  
Results  
Conclusion  
Keywords

Poster guidelines:  
**90cm x 120cm**

### FIRST (PRESENTING) AUTHOR (REQUIRED):

**Name:** Gustavo Albrecht Samico - R1  
**e-mail:** samico.gustavo@gmail.com  
**CEP Number:** 1022/2019

### 5. ABSTRACT (REQUIRED):

#### **Title: Assessment of Relationship Between Number of Glaucoma Medications, Ocular Surface Disorder and Treatment Adherence**

**Author and Co-authors:** Gustavo Albrecht Samico, MD, Tiago dos Santos Prata, MD, PhD, Sérgio Henrique Teixeira, MD, PhD, Ricardo Y. Abe, MD, Augusto Paranhos Jr., MD, PhD, Carolina Pelegrini Barbosa Gracitelli, MD, PhD

**Purpose:** Hypotensive eye drops can cause or aggravate changes in the ocular surface. Studies have shown that the presence of dry eye disease in patients with glaucoma affects patient's quality of life and is likely to influence treatment adherence. The purpose of this study was to evaluate the relationship between dry eye disease and medication adherence in glaucoma patients using one, two, three or more hypotensive eye drops.

**Methods:** This was a cross-sectional study including glaucoma patients from the Glaucoma sector of the Department of Ophthalmology of the Federal University of São Paulo (UNIFESP). After completing the Informed Consent Form, they were submitted to demographic data collection, completed the Ocular Surface Disease Index (OSDI) questionnaire and the Glaucoma Treatment Compliance Assessment Tool (GTCAT). A slit lamp eye examination was performed and they were still subjected to an objective analysis of the ocular surface by the Keratograph 5M?. Then, they were stratified into groups according to the amount of prescribed ocular hypotensive eye drops, having their data analyzed. Clinical and demographic data was collected to correct as potential confounder factors.

**Results:** Ten patients with primary open angle glaucoma using at least one medication for minimum of 6 months were enrolled. Mean age was  $69.20 \pm 18.21$  years and similar for all groups ( $P=0.387$ ). There was no significant difference between genders in groups using one, two, three or more hypotensive eye drops ( $P=0.543$ ). There was no significant difference between socioeconomic and commodities index for different groups ( $P>0.05$  for all comparisons). The overall score for the GTCAT questionnaire was similar for patients using one, two, three or more hypotensive eye drops ( $P=0.404$ ). For the keratograph assessment, patients using more than three medications have a tendency of having more conjunctival hyperemia and smaller tear meniscus height, however still not statically significant.

**Conclusion:** There is no significant difference in groups using different number of medications in terms of ocular surface disease and treatment Adherence. However, in those patients using three or more there is a tendency of having more conjunctival hyperemia and smaller tear meniscus height measured by objective parameters. In addition there is a tendency of worse adherence. Further analysis with bigger sample size is been done to elucidate this relationship measured by the first time with keratograph and with adherence questionnaire validated by Portuguese.

**Keywords:** glaucoma; Treatment Adherence; Ocular Surface Disorder

## 2019 Research Days Abstract Form

### 2. SCIENTIFIC SECTION PREFERENCE (REQUIRED):

Review the Scientific Section Descriptions. Select and enter the two-letter Code for the one (1) Section best suited to review your abstract.

**(GL) GLAUCOMA**

### 3. PRESENTATION PREFERENCE (REQUIRED)

Check one:

**(GL) GLAUCOMA**

4. The signature of the First (Presenting) Author (REQUIRED) acting as the authorized agent for all authors, hereby certifies that any research reported was conducted in compliance with the Declaration of Helsinki and the "UNIFESP Ethical Committee"

### Scientific Section Descriptions (two-letter code):

(BE) OCULAR BIOENGINEERING  
(CO) CORNEA AND EXTERNAL DISEASE  
(CA) CATARACT  
(EF) ELECTROPHYSIOLOGY  
(EP) EPIDEMIOLOGY  
(EX) EXPERIMENTAL SURGERY  
(GL) GLAUCOMA  
(LA) LABORATORY  
(LS) LACRIMAL SYSTEM  
(LV) LOW VISION  
(NO) NEURO-OPHTHALMOLOGY  
(OR) ORBIT  
(PL) OCULAR PLASTIC SURGERY  
(PH) PHARMACOLOGY  
(RE) RETINA AND VITREOUS  
(RS) REFRACTIVE SURGERY  
(RX) REFRACTION-CONTACT LENSES  
(ST) STRABISMUS  
(TR) TRAUMA  
(TU) TUMORS AND PATHOLOGY  
(UV) UVEITIS  
(US) OCULAR ULTRASOUND

Deadline: 10/2019

### FORMAT:

#### Abstract should contain:

Title  
Author  
Co-authors (maximum 6)  
Purpose  
Methods  
Results  
Conclusion  
Keywords

Poster guidelines:  
**90cm x 120cm**

### FIRST (PRESENTING) AUTHOR (REQUIRED):

**Name:** Marcos Pereira Vianello - PG1 - ME  
**e-mail:** marcospvianello@yahoo.com.br  
**CEP Number:** 5505

### 5. ABSTRACT (REQUIRED):

**Title: Outpatient follow-up profile of patients with glaucoma in the Brazilian public and private health sector**

**Author and Co-authors:** Vianello MP, Kanadani FN, Prata TS.

**Purpose:** To determine and analyze the outpatient follow-up profile of glaucomatous patients, comparatively between the public and private health care network, in three Brazilian cities.

**Methods:** The present observational cross-sectional study has been approved by the "Research Ethics Committees" of the participating institutions, to mention the Federal University of São Paulo, Medical Sciences College of Minas Gerais, Eye Medicine Hospital, Eye Bank of Sorocaba and Eye Clinic Dr. Reinaldo Sieiro, fulfilling the requirements of the same ones. The data collected will be anonymised and confidential. Once the criteria for inclusion and exclusion of this study are fulfilled, 100 medical records of the private health network and 100 medical records of the public network will be randomly selected in the participating institutions. With these records, an individual retrospective analysis of pre-determined datas will be done and will constitute the study database. This collected datas will be confronted by the orientations of monitoring by the "III Brazilian Consensus of Primary Open Angle Glaucoma".

**Results:** All data collected will be presented in a descriptive way and compared between the groups using appropriate statistics for the sample profile. An analysis will be made of the frequency of glaucoma visits, gonioscopy, pachymetry, retinography, tonometry and visual field tests performed per year in the private and public network, compared to the recommendations of the Brazilian Society of Glaucoma In the comparative analysis with the work of Chauhan et al. (Chauhan et al., 2008), and according to the number of achromatic computerized perimetry examinations performed over time, this study may infer the effectiveness of the services in detecting progression of glaucoma by the visual field and retinography.

**Conclusion:** The present study will determine the outpatient follow-up profile of patients with glaucoma in the involved centers and could also demonstrate the ability of these centers to detect the progression of the disease.

**Keywords:** glaucoma; public health; ambulatorial; monitoring; progression; Brazil

## 2019 Research Days Abstract Form

### 2. SCIENTIFIC SECTION PREFERENCE (REQUIRED):

Review the Scientific Section Descriptions. Select and enter the two-letter Code for the one (1) Section best suited to review your abstract.

**(GL) GLAUCOMA**

### 3. PRESENTATION PREFERENCE (REQUIRED)

Check one:

**(GL) GLAUCOMA**

4. The signature of the First (Presenting) Author (REQUIRED) acting as the authorized agent for all authors, hereby certifies that any research reported was conducted in compliance with the Declaration of Helsinki and the "UNIFESP Ethical Committee"

### Scientific Section Descriptions (two-letter code):

(BE) OCULAR BIOENGINEERING  
(CO) CORNEA AND EXTERNAL DISEASE  
(CA) CATARACT  
(EF) ELECTROPHYSIOLOGY  
(EP) EPIDEMIOLOGY  
(EX) EXPERIMENTAL SURGERY  
(GL) GLAUCOMA  
(LA) LABORATORY  
(LS) LACRIMAL SYSTEM  
(LV) LOW VISION  
(NO) NEURO-OPHTHALMOLOGY  
(OR) ORBIT  
(PL) OCULAR PLASTIC SURGERY  
(PH) PHARMACOLOGY  
(RE) RETINA AND VITREOUS  
(RS) REFRACTIVE SURGERY  
(RX) REFRACTION-CONTACT LENSES  
(ST) STRABISMUS  
(TR) TRAUMA  
(TU) TUMORS AND PATHOLOGY  
(UV) UVEITIS  
(US) OCULAR ULTRASOUND

Deadline: 10/2019

### FORMAT:

#### Abstract should contain:

Title  
Author  
Co-authors (maximum 6)  
Purpose  
Methods  
Results  
Conclusion  
Keywords

Poster guidelines:  
**90cm x 120cm**

### FIRST (PRESENTING) AUTHOR (REQUIRED):

**Name:** Mariana Chiba Ikeda - R1  
**e-mail:** marianachibaikeda@gmail.com  
**CEP Number:** 11540089

### 5. ABSTRACT (REQUIRED):

#### **Title: Different Interventions to Improve Reading Performance within Glaucoma Patients**

**Author and Co-authors:** Ikeda, MC<sup>1</sup>, Bando AH<sup>1</sup>, Hamada KU<sup>1</sup>, Nakamura VPL<sup>1</sup>, Lago Olival do<sup>1</sup>, Prata S., T<sup>1</sup>, Paranhos Jr. A<sup>1</sup>, Gracitelli CP<sup>1</sup> <sup>1</sup>Federal University of São Paulo, São Paulo, Brazil, Department of Ophthalmology and Vision Science, Federal University of São Paulo, São Paulo, Brazil

**Purpose:** To evaluate the impact of Contrast, Font Size or Line Spacing in reading performance within Glaucoma Patients using iPad's MNREAD (Minnesota Low Vision Reading Test) application.

**Methods:** This is a prospective cross-sectional study including 30 patients diagnosed with Glaucoma. The diagnosis was defined based on the presence of repeatable standard automatic perimetry (SAP) defects at time of evaluation in at least one eye. A detailed ophthalmological examination was performed on each subject. All patients had repeatable SAP (at least 2) and all patients went through a reading performance test based on the iPad app of the MNREAD (Minnesota Low Vision Reading Test), translated and validated to Portuguese. Only glaucoma patients with at least visual acuity better than 0.5 logMAR in both eyes were included. Reading speed (letters per minute) was assessed as the main reading performance variable, after testing 5 types of contrast, font size and line spacing. Potential biases, such as social and economical status and comorbidity were adjusted by multiple regression analysis.

**Results:** Mean age of patients with glaucoma was 66.04± 13.67. There were 23 female patients and 7 male patients. Average VA of the better eye was 0.16±0.15 LogMAR. Average VA of the worse eye was 0.26±0.20 LogMAR. Average MD of best eye was -7.26±7.46 and of worst eye was -11.25±9.21. There was statistical significance in the average reading speed when contrast was increased: 55.14±48.00 letters/minute and 99.59±32.11 letters/minute, respectively (p<'0.001) in all interventions. And there was also statistical significance for the font size 90.71±39.32 and 95.01±35.47, respectively (p=0.028) for the first intervention.

**Conclusion:** Patients with glaucoma improved their reading performance when contrast and font size were increased. Nevertheless, there was no change in reading performance when line spacing was altered. These findings enlarge our knowledge about interventions that may help daily activities of patients living with glaucoma.

**Keywords:** Glaucoma; Reading Performance; Mnread; Contrast; Font Size; Line spacing

## 2019 Research Days Abstract Form

### 2. SCIENTIFIC SECTION PREFERENCE (REQUIRED):

Review the Scientific Section Descriptions. Select and enter the two-letter Code for the one (1) Section best suited to review your abstract.

**(RE) RETINA AND VITREOUS**

### 3. PRESENTATION PREFERENCE (REQUIRED)

Check one:

**(RE) RETINA AND VITREOUS**

4. The signature of the First (Presenting) Author (REQUIRED) acting as the authorized agent for all authors, hereby certifies that any research reported was conducted in compliance with the Declaration of Helsinki and the "UNIFESP Ethical Committee"

### Scientific Section Descriptions (two-letter code):

(BE) OCULAR BIOENGINEERING  
(CO) CORNEA AND EXTERNAL DISEASE  
(CA) CATARACT  
(EF) ELECTROPHYSIOLOGY  
(EP) EPIDEMIOLOGY  
(EX) EXPERIMENTAL SURGERY  
(GL) GLAUCOMA  
(LA) LABORATORY  
(LS) LACRIMAL SYSTEM  
(LV) LOW VISION  
(NO) NEURO-OPHTHALMOLOGY  
(OR) ORBIT  
(PL) OCULAR PLASTIC SURGERY  
(PH) PHARMACOLOGY  
(RE) RETINA AND VITREOUS  
(RS) REFRACTIVE SURGERY  
(RX) REFRACTION-CONTACT LENSES  
(ST) STRABISMUS  
(TR) TRAUMA  
(TU) TUMORS AND PATHOLOGY  
(UV) UVEITIS  
(US) OCULAR ULTRASOUND

Deadline: 10/2019

### FORMAT:

#### Abstract should contain:

Title  
Author  
Co-authors (maximum 6)  
Purpose  
Methods  
Results  
Conclusion  
Keywords

Poster guidelines:  
**90cm x 120cm**

### FIRST (PRESENTING) AUTHOR (REQUIRED):

**Name:** Alex Treiger Grupenmacher - PG0 - DO  
**e-mail:** alexgrups@gmail.com  
**CEP Number:** 990022081

### 5. ABSTRACT (REQUIRED):

#### **Title: Efficacy of new anti-angiogenic drugs derived from heparinomimetics for neovascularization of choroid in animal model**

**Author and Co-authors:** Alex Treiger Grupenmacher M.D, Bianca O. Augusto, Vinicius Kniggendorf M.D, Juliana L. Dreyfuss, Pharm.D., Ph.D, Caio V. S. Regatieri M.D, Ph.D

**Purpose:** Choroidal neovascularization is a common endpoint in key retinal pathologies, with great clinical and social burden worldwide. Many drugs are currently being studied as potential targets, and chemically modified heparins (mHEP) have shown promising anti-angiogenic properties. This study aims to test the efficacy of a mHEP as an anti-angiogenic factor in an animal model.

**Methods:** A mHEP developed in the Molecular Biology Division of UNIFESP previously underwent in-vitro testing such as cell proliferation, cell viability with MTT, migration and adhesion assays which showed no toxicity and potential therapeutic action. 16 Zucker male pigmented rats were divided into 4 different groups: control group, 0,05mg/mL mHEP, 0,5mg/mL mHEP and 5,0 mg/mL mHEP. Choroidal neovascularization was induced in the animal with the use of diode green laser causing Bruch's membrane thermal rupture. Animals were then injected with different concentrations of mHEP. On day 15, animals were euthanized and the eyes removed and fixed in formaldehyde. An "eye-cup" model of choroid was created and Anti-vegf immunofluorescence applied to the specimens. Visualization in fluorescence microscopy of the choroidal neovascularization networks was performed and measures are being taken between different groups with ImageJ software

**Results:** As hypothesized, we expect to record inhibition of the neovascularized network growth in the eyes treated with mHEP in comparison to the control (placebo) group. A dose-dependent inhibition should be found as the compound concentration enhances. Images are being analyzed and result put through statistics

**Conclusion:** Previous studies of the same group showed promising results with chemically modified heparin (mHEP), and thus we intend to find similar results and compare them to our previous and other published data

**Keywords:** neovascularization, choroidal, anti-angiogenic, angiogenesis, CNV, heparin

## 2019 Research Days Abstract Form

### 2. SCIENTIFIC SECTION PREFERENCE (REQUIRED):

Review the Scientific Section Descriptions. Select and enter the two-letter Code for the one (1) Section best suited to review your abstract.

**(RE) RETINA AND VITREOUS**

### 3. PRESENTATION PREFERENCE (REQUIRED)

Check one:

**(RE) RETINA AND VITREOUS**

4. The signature of the First (Presenting) Author (REQUIRED) acting as the authorized agent for all authors, hereby certifies that any research reported was conducted in compliance with the Declaration of Helsinki and the "UNIFESP Ethical Committee"

### Scientific Section Descriptions (two-letter code):

(BE) OCULAR BIOENGINEERING  
(CO) CORNEA AND EXTERNAL DISEASE  
(CA) CATARACT  
(EF) ELECTROPHYSIOLOGY  
(EP) EPIDEMIOLOGY  
(EX) EXPERIMENTAL SURGERY  
(GL) GLAUCOMA  
(LA) LABORATORY  
(LS) LACRIMAL SYSTEM  
(LV) LOW VISION  
(NO) NEURO-OPHTHALMOLOGY  
(OR) ORBIT  
(PL) OCULAR PLASTIC SURGERY  
(PH) PHARMACOLOGY  
(RE) RETINA AND VITREOUS  
(RS) REFRACTIVE SURGERY  
(RX) REFRACTION-CONTACT LENSES  
(ST) STRABISMUS  
(TR) TRAUMA  
(TU) TUMORS AND PATHOLOGY  
(UV) UVEITIS  
(US) OCULAR ULTRASOUND

Deadline: 10/2019

### FORMAT:

#### Abstract should contain:

Title  
Author  
Co-authors (maximum 6)  
Purpose  
Methods  
Results  
Conclusion  
Keywords

Poster guidelines:  
**90cm x 120cm**

### FIRST (PRESENTING) AUTHOR (REQUIRED):

**Name:** Ana Carolina Yumi Itikawa - R2  
**e-mail:** anaitikawa@yahoo.com  
**CEP Number:** 1270/2018

### 5. ABSTRACT (REQUIRED):

**Title: Frequency of ophthalmological posterior segment findings in patients with Polycythemia Vera**

**Author and Co-authors:** Ana Carolina Yumi Itikawa, Natasha Ferreira Santos da Cruz, Murilo Ubukata Polizelli, Luis Filipe Nakayama, Vinicius Campos Bergamo, Rodrigo Antonio Brandt

**Purpose:** Polycythemia Vera is a chronic myeloproliferative disease characterized by erythrocythosis and inflammatory cytokines are released with blood viscosity increased and consequent ocular complications, mainly the retina, the more frequently tissue involved. Our study purpose was to evaluate the frequency of ocular posterior segment findings in patients with Polycythemia Vera and correlate with systemic control disease.

**Methods:** We evaluated fifteen patients with polycythemia vera of Hematological Sector of UNIFESP through complete ophthalmological exam and posterior segment assessment. Color fundus retinography, macular OCT and OCT angiography was performed with Topcon Triton. Fundus fluorescein angiography was performed with Heidelberg. More patients are still being recruited

**Results:** Patients mean age was 71,42 years ( $\pm 5,17$ ), 6 (40%) female participants and 9 (60%) male participants. Other results are in progress due to complementary exams of posterior segment are still being performed.

**Conclusion:** Polycythemia Vera is a hematologic disease with vascular complications and thrombosis risk factor increased, including ocular findings. Posterior segment exams help to comprehend the systemic control disease and can be an auxiliary tool to evaluate systemic disorder indicators.

**Keywords:** polycythemia vera; ocular posterior segment findings; frequency;

## 2019 Research Days Abstract Form

### 2. SCIENTIFIC SECTION PREFERENCE (REQUIRED):

Review the Scientific Section Descriptions. Select and enter the two-letter Code for the one (1) Section best suited to review your abstract.

**(RE) RETINA AND VITREOUS**

### 3. PRESENTATION PREFERENCE (REQUIRED)

Check one:

**(RE) RETINA AND VITREOUS**

4. The signature of the First (Presenting) Author (REQUIRED) acting as the authorized agent for all authors, hereby certifies that any research reported was conducted in compliance with the Declaration of Helsinki and the "UNIFESP Ethical Committee"

### Scientific Section Descriptions (two-letter code):

(BE) OCULAR BIOENGINEERING  
(CO) CORNEA AND EXTERNAL DISEASE  
(CA) CATARACT  
(EF) ELECTROPHYSIOLOGY  
(EP) EPIDEMIOLOGY  
(EX) EXPERIMENTAL SURGERY  
(GL) GLAUCOMA  
(LA) LABORATORY  
(LS) LACRIMAL SYSTEM  
(LV) LOW VISION  
(NO) NEURO-OPHTHALMOLOGY  
(OR) ORBIT  
(PL) OCULAR PLASTIC SURGERY  
(PH) PHARMACOLOGY  
(RE) RETINA AND VITREOUS  
(RS) REFRACTIVE SURGERY  
(RX) REFRACTION-CONTACT LENSES  
(ST) STRABISMUS  
(TR) TRAUMA  
(TU) TUMORS AND PATHOLOGY  
(UV) UVEITIS  
(US) OCULAR ULTRASOUND

Deadline: 10/2019

### FORMAT:

#### Abstract should contain:

Title  
Author  
Co-authors (maximum 6)  
Purpose  
Methods  
Results  
Conclusion  
Keywords

Poster guidelines:  
**90cm x 120cm**

### FIRST (PRESENTING) AUTHOR (REQUIRED):

**Name:** Brunella Pavan Taffner - PG0 - DO  
**e-mail:** brunellapavan@hotmail.com  
**CEP Number:** 29057600

### 5. ABSTRACT (REQUIRED):

**Title: The use of optical coherence tomography for detection of retinal toxicity by ethambutol**

**Author and Co-authors:** Taffner, B M P, Fowler, F A, Cruz, L G I, Rodrigues, D S, Magalhães, O, Belfort Jr, R M.

**Purpose:** To evaluate, through optical coherence tomography (OCT), alterations in retinal nerve fiber layer (RNFL) and ganglion cell layer (GCL), secondary to use of ethambutol in the treatment of patients with tuberculosis. In addition to study correlations between computerized campimetry and OCT changes during use of etambutol, and to evaluate the vision quality with the National Eye Institute Visual Function Questionnaire-25 (NEI VFQ-25) in these patients after treatment.

**Methods:** Patients treated with ethambutol were recruited from the reference service of tuberculosis treatment at the Federal University of São Paulo from March 2019. The research was conducted under approval of the Research Ethics Committee of UNIFESP/EPM CAAE: 04297018.4.0000.5505. After clinical history, the following parameters were analyzed, best corrected visual acuity, Ishihara test, OCT Triton (Topcon) and Humphrey visual field analyzer central 24.2 (Carl Zeiss) for every month during treatment with ethambutol. At the end of treatment, all patients will be submitted to the questionnaire NEI VFQ-25. Patients are still being recruited for the study. ?

**Results:** Currently, a total of 20 individuals aged from 18 to 65 years (average: 37.75 ± 15.64) were analyzed in the present study. The distribution of groups in relation to gender was equitable, 50 percent were men and 50 percent were women. Regarding the focus of disease, 15 percent of patients had ganglionic tuberculosis, 10 percent pleural tuberculosis and 75 percent pulmonary disease. In the ethnic category, 25 percent considered themselves white, 20 percent black and 55 percent brown. 90 percent of patients were on classic tuberculosis treatment regimen with rifampicin, isoniazid, pyrazinamide and ethambutol (RIPE), only 10 percent were on multidrug-resistant mycobacteria treatment. Patients are still under treatment, so OCT and visual field data are not completed yet.

**Conclusion:** Research is still in progress, requiring a larger number of patients and a longer follow-up.

**Keywords:** ethambutol; optical coherence tomography; retina; toxicity.

## 2019 Research Days Abstract Form

### 2. SCIENTIFIC SECTION PREFERENCE (REQUIRED):

Review the Scientific Section Descriptions. Select and enter the two-letter Code for the one (1) Section best suited to review your abstract.

**(RE) RETINA AND VITREOUS**

### 3. PRESENTATION PREFERENCE (REQUIRED)

Check one:

**(RE) RETINA AND VITREOUS**

4. The signature of the First (Presenting) Author (REQUIRED) acting as the authorized agent for all authors, hereby certifies that any research reported was conducted in compliance with the Declaration of Helsinki and the "UNIFESP Ethical Committee"

Scientific Section Descriptions (two-letter code):

(BE) OCULAR BIOENGINEERING  
(CO) CORNEA AND EXTERNAL DISEASE  
(CA) CATARACT  
(EF) ELECTROPHYSIOLOGY  
(EP) EPIDEMIOLOGY  
(EX) EXPERIMENTAL SURGERY  
(GL) GLAUCOMA  
(LA) LABORATORY  
(LS) LACRIMAL SYSTEM  
(LV) LOW VISION  
(NO) NEURO-OPHTHALMOLOGY  
(OR) ORBIT  
(PL) OCULAR PLASTIC SURGERY  
(PH) PHARMACOLOGY  
(RE) RETINA AND VITREOUS  
(RS) REFRACTIVE SURGERY  
(RX) REFRACTION-CONTACT LENSES  
(ST) STRABISMUS  
(TR) TRAUMA  
(TU) TUMORS AND PATHOLOGY  
(UV) UVEITIS  
(US) OCULAR ULTRASOUND

Deadline: 10/2019

### FORMAT:

#### Abstract should contain:

Title  
Author  
Co-authors (maximum 6)  
Purpose  
Methods  
Results  
Conclusion  
Keywords

Poster guidelines:  
**90cm x 120cm**

### FIRST (PRESENTING) AUTHOR (REQUIRED):

**Name:** Bruno Mauricio Rodrigues de Oliveira - Fellow  
**e-mail:** brunomro@gmail.com  
**CEP Number:** 1118-2018

### 5. ABSTRACT (REQUIRED):

**Title: Effects of panretinal laser photocoagulation on the tear function and ocular surface using OCULUS Keratograph® 5M**

**Author and Co-authors:** Bruno Mauricio Rodrigues de Oliveira, Jose Aparecido Job Neto, Denise de Freitas, Octaviano Magalhães Junior

**Purpose:** To evaluate tear function and ocular surface alterations after panretinal laser photocoagulation in subjects with proliferative diabetic retinopathy.

**Methods:** This is an observational and prospective study. All patients underwent ophthalmic examination of ocular surface with OCULUS Keratograph® 5M including tear meniscus height, non-invasive keratograph break-up time and ocular redness classification. The exams were performed before the laser photocoagulation starts and repeated ninety days after the panretinal laser photocoagulation was finished.

**Results:** So far, eleven subjects met the inclusion criteria and were recruited. Panretinal photocoagulation and exams are in progress.

**Conclusion:** In progress.

**Keywords:** diabetic retinopathy, dry eye disease, keratograph, panretinal laser photocoagulation, tear film

## 2019 Research Days Abstract Form

### 2. SCIENTIFIC SECTION PREFERENCE (REQUIRED):

Review the Scientific Section Descriptions. Select and enter the two-letter Code for the one (1) Section best suited to review your abstract.

**(RE) RETINA AND VITREOUS**

### 3. PRESENTATION PREFERENCE (REQUIRED)

Check one:

**(RE) RETINA AND VITREOUS**

4. The signature of the First (Presenting) Author (REQUIRED) acting as the authorized agent for all authors, hereby certifies that any research reported was conducted in compliance with the Declaration of Helsinki and the "UNIFESP Ethical Committee"

### Scientific Section Descriptions (two-letter code):

(BE) OCULAR BIOENGINEERING  
(CO) CORNEA AND EXTERNAL DISEASE  
(CA) CATARACT  
(EF) ELECTROPHYSIOLOGY  
(EP) EPIDEMIOLOGY  
(EX) EXPERIMENTAL SURGERY  
(GL) GLAUCOMA  
(LA) LABORATORY  
(LS) LACRIMAL SYSTEM  
(LV) LOW VISION  
(NO) NEURO-OPHTHALMOLOGY  
(OR) ORBIT  
(PL) OCULAR PLASTIC SURGERY  
(PH) PHARMACOLOGY  
(RE) RETINA AND VITREOUS  
(RS) REFRACTIVE SURGERY  
(RX) REFRACTION-CONTACT LENSES  
(ST) STRABISMUS  
(TR) TRAUMA  
(TU) TUMORS AND PATHOLOGY  
(UV) UVEITIS  
(US) OCULAR ULTRASOUND

Deadline: 10/2019

### FORMAT:

#### Abstract should contain:

Title  
Author  
Co-authors (maximum 6)  
Purpose  
Methods  
Results  
Conclusion  
Keywords

Poster guidelines:  
**90cm x 120cm**

### 2. FIRST (PRESENTING) AUTHOR (REQUIRED):

**Name:** Daniela Calucci dos Santos - PG1 - ME  
**e-mail:** danielacalucci@hotmail.com  
**CEP Number:** 0664/2016

### 5. ABSTRACT (REQUIRED):

**Title: Assessment of Presence of Activity of Secondary Neovascular Membrane to Age-Related Macular Degeneration with OCT-A Examinations versus Traditional Retinography, Angiography, and SD-OCT Methods?**

**Author and Co-authors:** Auhor: Daniela Calucci dos Santos Co-authors: Eduardo Büchele Rodrigues, Pedro Paulo Bonomo

**Purpose:** The aim of this study is to identify signs of neovascular membrane activity (MNV) based on color retinography, angiofluoresceinography (AGF), green indocyanine angiography (ICG), and SD-OCT (spectral domain - optical coherence tomography) examinations. , optical coherence tomography) and to analyze the degree of agreement and association with the OCT angiography examination (OCTA)

**Methods:** Retrospective study of 23 eyes of 23 patients diagnosed with advanced neovascular AMD underwent anti-VEGF therapy. Best corrected visual acuity (BCVA), Color, FA, ICG, SD-OCT and OCT-A using RTVue XR Avanti with AngioVue were performed at baseline and follow-up 4 - 6 months after anti-VEGF injection. Detection of abnormal flow in the outer retina and choriocapillaris layer slabs may indicate the presence of CNV complex with OCT-A. One Masked grader reviewed all images separately for study eye at the baseline and follow-up records. Morphologic patterns and qualitative features of CNV with OCT-A were studied based on multimodal images.

**Results:** A total of 20 (86%) Female and 3 (13%) male patients with a mean age of 75 years (range: 50-97years) were observed. Optical coherence tomography angiography captured a CNV structure in 99% of these cases only one was impossible detection. The morphology of all subtypes CNV identified were 3 eyes with glomerular pattern, 3 eyes with seafan pattern, 4 eyes with medusa pattern and 12 eyes with indistinct pattern. Subtype CNV didn't correlate significantly with the type of CNV lesions. OCTA was able to detect the presence of nourishing vessel in the initial and follow-up visits in 9/23 (39.1%). The agreement analysis reveals that there was no good agreement observed and statistical significance of the signals considered possible indicators of CNV activity in OCTA when compared with the presence of leakage in AGF and fluid in SD-OCT.

**Conclusion:** OCT-A is a image modality which provides the visualization of neovascular complex in AMD without the need for dye injection. For this study we documented all patients with the conventional images modalities each of then assisting in the classification of subtypes CNV lesions, activity hallmarks and presence of neovascular complex in the advanced exudative AMD lesions under treatment with anti-VEGF. In previous studies OCTA was capable to detect the neovascular complex relative to RPE and Bruch's membrane but it was almost difficult correlated this findings with the activity features easily identified on gold standard images. In our study we could identified the morphology in such cases but not correlated with the specific subtype of CNV. We found 43,4% of well demarcated lesions and 52,3% a indistinct pattern. We conclude that we couldn't confirm the presence of OCTA-based CNV activity considering the presence of at least one of the vascular architecture criteria analyzed does not reflect a reliable statement because there was no degree of association in the statistical analyzes applied when compared to the gold standard tests, AGF and SD-OCT.

**Keywords:** CNV, OCT angiography and AMD



## 2019 Research Days Abstract Form

### 2. SCIENTIFIC SECTION PREFERENCE (REQUIRED):

Review the Scientific Section Descriptions. Select and enter the two-letter Code for the one (1) Section best suited to review your abstract.

**(RE) RETINA AND VITREOUS**

### 3. PRESENTATION PREFERENCE (REQUIRED)

Check one:

**(RE) RETINA AND VITREOUS**

4. The signature of the First (Presenting) Author (REQUIRED) acting as the authorized agent for all authors, hereby certifies that any research reported was conducted in compliance with the Declaration of Helsinki and the "UNIFESP Ethical Committee"

### Scientific Section Descriptions (two-letter code):

(BE) OCULAR BIOENGINEERING  
(CO) CORNEA AND EXTERNAL DISEASE  
(CA) CATARACT  
(EF) ELECTROPHYSIOLOGY  
(EP) EPIDEMIOLOGY  
(EX) EXPERIMENTAL SURGERY  
(GL) GLAUCOMA  
(LA) LABORATORY  
(LS) LACRIMAL SYSTEM  
(LV) LOW VISION  
(NO) NEURO-OPHTHALMOLOGY  
(OR) ORBIT  
(PL) OCULAR PLASTIC SURGERY  
(PH) PHARMACOLOGY  
(RE) RETINA AND VITREOUS  
(RS) REFRACTIVE SURGERY  
(RX) REFRACTION-CONTACT LENSES  
(ST) STRABISMUS  
(TR) TRAUMA  
(TU) TUMORS AND PATHOLOGY  
(UV) UVEITIS  
(US) OCULAR ULTRASOUND

Deadline: 10/2019

### FORMAT:

#### Abstract should contain:

Title  
Author  
Co-authors (maximum 6)  
Purpose  
Methods  
Results  
Conclusion  
Keywords

Poster guidelines:  
**90cm x 120cm**

### FIRST (PRESENTING) AUTHOR (REQUIRED):

**Name:** Dante Akira Kondo Kuroiwa - R3  
**e-mail:** akira.epm78@gmail.com  
**CEP Number:** 4044020

### 5. ABSTRACT (REQUIRED):

**Title: CHOROIDAL THICKNESS COMPARISON OF NON-EDEMATOUS AND EDEMATOUS MACULAR AR-EAS IN PATIENTS WITH DIABETIC MACULAR EDEMA USING EDI-OCT.**

**Author and Co-authors:** Dante Akira Kondo Kuroiwa MD1, Felipe Pereira MD1, Vinicius Ferreira Kniggendorf MD1, Stéphanie de Almeida Fontanelli1, Vinicius da Silveira Saraiva MD1, André P. Muralha MD2, Laís Maia Cezar MD2, Eduardo Kestelman, MD2, Eduardo A. Novais MD PhD1,2, Caio Vinicius Saito Regatieri MD PhD1.

**Purpose:** To compare the choroidal thickness (CT) measured by spectral-domain optical coherence tomography (SD-OCT) in areas with and without macular edema in patients with diabetic macular edema.

**Methods:** Thirty-seven eyes of 28 patients underwent high-definition vertical line scanning using enhanced depth image (EDI) SD-OCT with frame enhancement software. CT was measured from the posterior edge of the retinal pigment epithelium to the choroid/scleral junction at 250  $\mu\text{m}$  intervals, starting from the center of the fovea until the area without edema. A comparison between the regions with and without edema was performed. Additionally, the CT in the superior and inferior borders were also compared.

**Results:** Mean CT in the edematous retina area was 271.28  $\mu\text{m}$  (70 $\mu\text{m}$ -491 $\mu\text{m}$ ) compared to 243.78 $\mu\text{m}$  (64  $\mu\text{m}$ -455  $\mu\text{m}$ ) in the area without edema ( $P < 0.001$ ). The superior edge of the edema was also thicker than the upper adjacent area without edema. ( $P < 0.03$ ). There was no significant difference comparing the inferior edge of the edema with the inferior area without edema.

**Conclusion:** CT in the area with macular edema was thicker than the area without macular edema, which may be explained by increased levels of inflammatory mediators and activity of pigment epithelium in this region.

**Keywords:** Choroidal Thickness; retinal edema; Optical Coherence Tomography; Enhanced Depth Image; Diabetic Macular Edema.

## 2019 Research Days Abstract Form

### 2. SCIENTIFIC SECTION PREFERENCE (REQUIRED):

Review the Scientific Section Descriptions. Select and enter the two-letter Code for the one (1) Section best suited to review your abstract.

**(RE) RETINA AND VITREOUS**

### 3. PRESENTATION PREFERENCE (REQUIRED)

Check one:

**(RE) RETINA AND VITREOUS**

4. The signature of the First (Presenting) Author (REQUIRED) acting as the authorized agent for all authors, hereby certifies that any research reported was conducted in compliance with the Declaration of Helsinki and the "UNIFESP Ethical Committee"

### Scientific Section Descriptions (two-letter code):

(BE) OCULAR BIOENGINEERING  
(CO) CORNEA AND EXTERNAL DISEASE  
(CA) CATARACT  
(EF) ELECTROPHYSIOLOGY  
(EP) EPIDEMIOLOGY  
(EX) EXPERIMENTAL SURGERY  
(GL) GLAUCOMA  
(LA) LABORATORY  
(LS) LACRIMAL SYSTEM  
(LV) LOW VISION  
(NO) NEURO-OPHTHALMOLOGY  
(OR) ORBIT  
(PL) OCULAR PLASTIC SURGERY  
(PH) PHARMACOLOGY  
(RE) RETINA AND VITREOUS  
(RS) REFRACTIVE SURGERY  
(RX) REFRACTION-CONTACT LENSES  
(ST) STRABISMUS  
(TR) TRAUMA  
(TU) TUMORS AND PATHOLOGY  
(UV) UVEITIS  
(US) OCULAR ULTRASOUND

Deadline: 10/2019

### FORMAT:

#### Abstract should contain:

Title  
Author  
Co-authors (maximum 6)  
Purpose  
Methods  
Results  
Conclusion  
Keywords

Poster guidelines:  
**90cm x 120cm**

### FIRST (PRESENTING) AUTHOR (REQUIRED):

**Name:** Diego Lisboa Araujo - R3  
**e-mail:** diego\_lisboa10@hotmail.com  
**CEP Number:** 038/2019

### 5. ABSTRACT (REQUIRED):

**Title:** Analysis of scleral buckling surgeries for rhegmatogenous retinal detachment performed in a quaternary hospital

**Author and Co-authors:** Diego Lisboa Araújo, Natasha Ferreira Santos da Cruz, Murilo Ubukata Polizelli, Maurício Maia.

**Purpose:** To evaluate preoperative, intraoperative data, results and the final outcome of scleral buckle surgeries in a public quaternary care hospital.

**Methods:** Retrospective, non-comparative study of all scleral buckle surgeries for rhegmatogenous retinal detachment performed from 2014 to 2018 at Escola Paulista de Medicina. Demographic data, primary indication for surgery, eye status, complications and outcomes were assessed.

**Results:** A total of 190 scleral buckles were performed in the period. The average age of the patients was  $42.9 \pm 15.1$  years, 56.3% were male. In most cases, 95.3%, surgeries were performed on phakic eyes, three quarters had detached macula at the time of surgery. The detachment affected one quadrant in 17.4%, two in 56.2%, three in 23.2% and all quadrants in 3.16%. In 96.8% of the procedures cryotherapy was used, in the rest, laser. There was vitreous hemorrhage in 0.5% and persistence of retinal detachment in 1.1%. 43.2% had recurrence of detachment, 2.6% developed cataract and 0.5% glaucoma. In 1.6% of cases it was necessary to remove the buckle due to scleritis, abscess or granuloma. Preoperative visual acuity was better than or equal to 20/50 in 22.6% and worse than or equal to 20/400 in 58.4%. The final postoperative acuity was better or equal to 20/50 in 34.2% and worse or equal to 20/400 in 26.8%.

**Conclusion:** The scleral buckle may be associated with significant complications. Careful planning, proper patient selection, and good intraoperative technique can reduce complication rates.

**Keywords:** Scleral buckling; Retinal Detachment.

## 2019 Research Days Abstract Form

### 2. SCIENTIFIC SECTION PREFERENCE (REQUIRED):

Review the Scientific Section Descriptions. Select and enter the two-letter Code for the one (1) Section best suited to review your abstract.

**(RE) RETINA AND VITREOUS**

### 3. PRESENTATION PREFERENCE (REQUIRED)

Check one:

**(RE) RETINA AND VITREOUS**

4. The signature of the First (Presenting) Author (REQUIRED) acting as the authorized agent for all authors, hereby certifies that any research reported was conducted in compliance with the Declaration of Helsinki and the "UNIFESP Ethical Committee"

### Scientific Section Descriptions (two-letter code):

(BE) OCULAR BIOENGINEERING  
(CO) CORNEA AND EXTERNAL DISEASE  
(CA) CATARACT  
(EF) ELECTROPHYSIOLOGY  
(EP) EPIDEMIOLOGY  
(EX) EXPERIMENTAL SURGERY  
(GL) GLAUCOMA  
(LA) LABORATORY  
(LS) LACRIMAL SYSTEM  
(LV) LOW VISION  
(NO) NEURO-OPHTHALMOLOGY  
(OR) ORBIT  
(PL) OCULAR PLASTIC SURGERY  
(PH) PHARMACOLOGY  
(RE) RETINA AND VITREOUS  
(RS) REFRACTIVE SURGERY  
(RX) REFRACTION-CONTACT LENSES  
(ST) STRABISMUS  
(TR) TRAUMA  
(TU) TUMORS AND PATHOLOGY  
(UV) UVEITIS  
(US) OCULAR ULTRASOUND

Deadline: 10/2019

### FORMAT:

#### Abstract should contain:

Title  
Author  
Co-authors (maximum 6)  
Purpose  
Methods  
Results  
Conclusion  
Keywords

Poster guidelines:  
**90cm x 120cm**

### FIRST (PRESENTING) AUTHOR (REQUIRED):

**Name:** Felipe Ferreira Conti - PG1 - DO  
**e-mail:** contiffelipe@gmail.com  
**CEP Number:** 24220260

### 5. ABSTRACT (REQUIRED):

**Title: Optical Coherence Tomography (OCT) Angiography Use in Retinal Diseases**

**Author and Co-authors:** Conti FF, Rodrigues EB, Silva FQ, Qin V, Babiuch AS, Han M, Singh RP

**Purpose:** The purpose of these studies were to access the value of OCTA in ophthalmology. The first study assessed the repeatability measures of the SSADA OCTA across a variety of retinal diseases. The second study assessed choriocapillaris and retinal Capillary Perfusion Density (CPD) changes in diabetic patients using OCTA, and the third study used OCTA imaging to evaluate choriocapillaris and retinal CPD changes in diabetic retinopathy following anti-vascular endothelial growth factor (VEGF) treatment.

**Methods:** All were retrospective studies, performed at Cole Eye Institute, Cleveland, Ohio after approval from the Cleveland Clinic Investigational Review Board (IRB). Overall, 109 charts were reviewed to assess OCTA data. The Optovue Avanti XR OCTA device was used. This machine uses an 840-nm wavelength beam to acquire A-scans at a rate of 70,000 scans per second with an axial resolution of 5 microns and beam width of 20 microns. SSADA algorithm was used to generate enface image.

**Results:** Repeatability analysis revealed no statistically significant differences ( $P > 0.05$ ) between any of the measurements time points. Results from our studies examining choroidal and retinal vascular indices in different stages of diabetes suggested that, compared with non-diabetic controls, eyes with NPDR and PDR demonstrated decreased choroidal vascular density, and that eyes with PDR demonstrated decreased retinal vascular density and an increased FAZ area. Additionally, CPD changes in DM patients receiving anti-VEGF treatment suggested that while eyes with DR have decreased choroidal and retinal vascular density compared to control eyes, anti-VEGF treatment did not significantly alter the choroidal or retinal vascular density.

**Conclusion:** SSADA OCTA algorithm is a reliable tool in the evaluation of some retinal diseases, and it is capable of detecting capillary perfusion changes in the retina and choriocapillaris of diabetic patients compared to healthy individuals as well as correlating these capillary density changes with the ocular disease severity.

**Keywords:** OCTA DME DR

## 2019 Research Days Abstract Form

### 2. SCIENTIFIC SECTION PREFERENCE (REQUIRED):

Review the Scientific Section Descriptions. Select and enter the two-letter Code for the one (1) Section best suited to review your abstract.

**(RE) RETINA AND VITREOUS**

### 3. PRESENTATION PREFERENCE (REQUIRED)

Check one:

**(RE) RETINA AND VITREOUS**

4. The signature of the First (Presenting) Author (REQUIRED) acting as the authorized agent for all authors, hereby certifies that any research reported was conducted in compliance with the Declaration of Helsinki and the "UNIFESP Ethical Committee"

### Scientific Section Descriptions (two-letter code):

(BE) OCULAR BIOENGINEERING  
(CO) CORNEA AND EXTERNAL DISEASE  
(CA) CATARACT  
(EF) ELECTROPHYSIOLOGY  
(EP) EPIDEMIOLOGY  
(EX) EXPERIMENTAL SURGERY  
(GL) GLAUCOMA  
(LA) LABORATORY  
(LS) LACRIMAL SYSTEM  
(LV) LOW VISION  
(NO) NEURO-OPHTHALMOLOGY  
(OR) ORBIT  
(PL) OCULAR PLASTIC SURGERY  
(PH) PHARMACOLOGY  
(RE) RETINA AND VITREOUS  
(RS) REFRACTIVE SURGERY  
(RX) REFRACTION-CONTACT LENSES  
(ST) STRABISMUS  
(TR) TRAUMA  
(TU) TUMORS AND PATHOLOGY  
(UV) UVEITIS  
(US) OCULAR ULTRASOUND

Deadline: 10/2019

### FORMAT:

#### Abstract should contain:

Title  
Author  
Co-authors (maximum 6)  
Purpose  
Methods  
Results  
Conclusion  
Keywords

Poster guidelines:  
**90cm x 120cm**

### FIRST (PRESENTING) AUTHOR (REQUIRED):

**Name:** Felipe Picanço Muralha - Fellow  
**e-mail:** felipe\_muralha@hotmail.com  
**CEP Number:** 2627718

### 5. ABSTRACT (REQUIRED):

**Title: Comparison of the use of analgesic drugs in panretinal photocoagulation on patients with diabetic retinopathy**

**Author and Co-authors:** Felipe Muralha, Alex Grupenmacher, Bruno de Oliveira, Natasha Cruz, Murilo Polizelli, Nilva Moraes

**Purpose:** To expand our knowledge about the use of oral and topical analgesic drugs in panretinal photocoagulation (PRP) and to evaluate if: Ibuprofen, Metamizole (dipyrone), Fluormetolone and Ketorolac has a significant analgesic effect that justifies it's use in PRP procedures, comparing their effects.

**Methods:** The patients will be randomized in 4 groups: Ibuprofen 400mg oral, Metamizole 500mg oral, Fluormetolone 0,1% topical and Ketorolac 0,5% topical. Every patient will have two exposures, and in both they will take one pill and use one eyedrop. In one of the exposures they will use the analgesic drug and a placebo (eye drop or pill placebo) and in the other exposure both the pill and eyedrop are going to be a placebo. Neither the patient or the doctor knows which drug the patient is taking, or if the exposure is a "treatment" or "placebo" one. Each session is going to be made in one of the patient's eye, using the same laser, which similar spot size, potency, number of spots, and same quadrants. After the procedure the patient will inform in the Visual Analog Scale the pain during the procedure, going from 0-10.

**Results:** The study is currently in progress

**Conclusion:** We hope that the drugs in the study present a relevant analgesic effect, possibly making their use a standard procedure for pain reduction in patients undergoing PRP

**Keywords:** analgesic, panretinal photocoagulation, diabetic retinopathy

## 2019 Research Days Abstract Form

### 2. SCIENTIFIC SECTION PREFERENCE (REQUIRED):

Review the Scientific Section Descriptions. Select and enter the two-letter Code for the one (1) Section best suited to review your abstract.

**(RE) RETINA AND VITREOUS**

### 3. PRESENTATION PREFERENCE (REQUIRED)

Check one:

**(RE) RETINA AND VITREOUS**

4. The signature of the First (Presenting) Author (REQUIRED) acting as the authorized agent for all authors, hereby certifies that any research reported was conducted in compliance with the Declaration of Helsinki and the "UNIFESP Ethical Committee"

Scientific Section Descriptions (two-letter code):

(BE) OCULAR BIOENGINEERING  
(CO) CORNEA AND EXTERNAL DISEASE  
(CA) CATARACT  
(EF) ELECTROPHYSIOLOGY  
(EP) EPIDEMIOLOGY  
(EX) EXPERIMENTAL SURGERY  
(GL) GLAUCOMA  
(LA) LABORATORY  
(LS) LACRIMAL SYSTEM  
(LV) LOW VISION  
(NO) NEURO-OPHTHALMOLOGY  
(OR) ORBIT  
(PL) OCULAR PLASTIC SURGERY  
(PH) PHARMACOLOGY  
(RE) RETINA AND VITREOUS  
(RS) REFRACTIVE SURGERY  
(RX) REFRACTION-CONTACT LENSES  
(ST) STRABISMUS  
(TR) TRAUMA  
(TU) TUMORS AND PATHOLOGY  
(UV) UVEITIS  
(US) OCULAR ULTRASOUND

Deadline: 10/2019

### FORMAT:

#### Abstract should contain:

Title  
Author  
Co-authors (maximum 6)  
Purpose  
Methods  
Results  
Conclusion  
Keywords

Poster guidelines:  
**90cm x 120cm**

### FIRST (PRESENTING) AUTHOR (REQUIRED):

**Name:** Guilherme Eiich Takitani - Fellow  
**e-mail:** guilherme.eiichi@gmail.com  
**CEP Number:** 0

### 5. ABSTRACT (REQUIRED):

**Title: Subretinal Fluid Application to Macular Hole Closure**

**Author and Co-authors:** Guilherme Eiichi da Silva Takitani, Natasha Ferreira Santos da Cruz, Murilo Ubukata Polizelli, Michel Eid Farah, Andre Maia, Eduardo Buchele Rodrigues, Octaviano Magalhães, Carsten Mayer, Maurício Maia

**Purpose:** To evaluate the process of closure of full thickness macular hole (FTMH) using a novel surgical approach and the anatomical and functional results.

**Methods:** Prospective clinical study designed for macular holes refractory to other surgical techniques or primary macular holes with low prognosis. The duration of the study will be one year, and the patients will be submitted to a novel technique described by Meyer et al The technical approach consists by pars plana vitrectomy with application of sub retinal fluid around the FTMH. All patients will be assessed by complete ophthalmological exam, optical coherence tomography, microperimetry and fundus photos.

**Results:** In progress.

**Conclusion:** In progress.

**Keywords:** macular hole - subretinal fluid application - refractory macular hole

## 2019 Research Days Abstract Form

### 2. SCIENTIFIC SECTION PREFERENCE (REQUIRED):

Review the Scientific Section Descriptions. Select and enter the two-letter Code for the one (1) Section best suited to review your abstract.

**(RE) RETINA AND VITREOUS**

### 3. PRESENTATION PREFERENCE (REQUIRED)

Check one:

**(RE) RETINA AND VITREOUS**

4. The signature of the First (Presenting) Author (REQUIRED) acting as the authorized agent for all authors, hereby certifies that any research reported was conducted in compliance with the Declaration of Helsinki and the 'UNIFESP Ethical Committee'

### Scientific Section Descriptions (two-letter code):

(BE) OCULAR BIOENGINEERING  
(CO) CORNEA AND EXTERNAL DISEASE  
(CA) CATARACT  
(EF) ELECTROPHYSIOLOGY  
(EP) EPIDEMIOLOGY  
(EX) EXPERIMENTAL SURGERY  
(GL) GLAUCOMA  
(LA) LABORATORY  
(LS) LACRIMAL SYSTEM  
(LV) LOW VISION  
(NO) NEURO-OPHTHALMOLOGY  
(OR) ORBIT  
(PL) OCULAR PLASTIC SURGERY  
(PH) PHARMACOLOGY  
(RE) RETINA AND VITREOUS  
(RS) REFRACTIVE SURGERY  
(RX) REFRACTION-CONTACT LENSES  
(ST) STRABISMUS  
(TR) TRAUMA  
(TU) TUMORS AND PATHOLOGY  
(UV) UVEITIS  
(US) OCULAR ULTRASOUND

Deadline: 10/2019

### FORMAT:

#### Abstract should contain:

Title  
Author  
Co-authors (maximum 6)  
Purpose  
Methods  
Results  
Conclusion  
Keywords

Poster guidelines:  
**90cm x 120cm**

### FIRST (PRESENTING) AUTHOR (REQUIRED):

**Name:** Julia Harumi Iwakura - R1  
**e-mail:** julia.harumi.i@gmail.com  
**CEP Number:** 4021050

### 5. ABSTRACT (REQUIRED):

**Title: A case of Acute Macular Neurotinopathy: a case report**

**Author and Co-authors:** Iwakura, Julia, Bergamo, Vinicius

**Purpose:** Report a case of Acute Macular Neurotinopathy

**Methods:** A case of Acute Macular Neurotinopathy was investigated and confirmed

**Results:** A case of Acute Macular Neuroretinopathy was described

**Conclusion:** A case of Acute Macular Neuroretinopathy is described. A 12 year-old female from São Paulo presenting a sudden paracentral scotoma in the right eye in use of oral contraceptive pills for the past 5 months with a normal eye exam, a hypofluorescence lesion in the fluorescein angiography and a hyper-reflective plaque in the outer nuclear layer in the OCT. The patient presents improvement of the central scotoma after suspending the use of the oral contraceptive pills.

**Keywords:** Acute Macular Neurotinopathy

## 2019 Research Days Abstract Form

### 2. SCIENTIFIC SECTION PREFERENCE (REQUIRED):

Review the Scientific Section Descriptions. Select and enter the two-letter Code for the one (1) Section best suited to review your abstract.

**(RE) RETINA AND VITREOUS**

### 3. PRESENTATION PREFERENCE (REQUIRED)

Check one:

**(RE) RETINA AND VITREOUS**

4. The signature of the First (Presenting) Author (REQUIRED) acting as the authorized agent for all authors, hereby certifies that any research reported was conducted in compliance with the Declaration of Helsinki and the "UNIFESP Ethical Committee"

### Scientific Section Descriptions (two-letter code):

(BE) OCULAR BIOENGINEERING  
(CO) CORNEA AND EXTERNAL DISEASE  
(CA) CATARACT  
(EF) ELECTROPHYSIOLOGY  
(EP) EPIDEMIOLOGY  
(EX) EXPERIMENTAL SURGERY  
(GL) GLAUCOMA  
(LA) LABORATORY  
(LS) LACRIMAL SYSTEM  
(LV) LOW VISION  
(NO) NEURO-OPHTHALMOLOGY  
(OR) ORBIT  
(PL) OCULAR PLASTIC SURGERY  
(PH) PHARMACOLOGY  
(RE) RETINA AND VITREOUS  
(RS) REFRACTIVE SURGERY  
(RX) REFRACTION-CONTACT LENSES  
(ST) STRABISMUS  
(TR) TRAUMA  
(TU) TUMORS AND PATHOLOGY  
(UV) UVEITIS  
(US) OCULAR ULTRASOUND

Deadline: 10/2019

### FORMAT:

#### Abstract should contain:

Title  
Author  
Co-authors (maximum 6)  
Purpose  
Methods  
Results  
Conclusion  
Keywords

Poster guidelines:  
**90cm x 120cm**

### FIRST (PRESENTING) AUTHOR (REQUIRED):

**Name:** Luiz Filipe Adami Lucatto - PG1 - DO  
**e-mail:** filipeadami@yahoo.com.br  
**CEP Number:** 1.415.541

### 5. ABSTRACT (REQUIRED):

#### **Title: RANDOMIZED CLINICAL TRIAL TO COMPARE THE HEALING PROCESS OF IDIOPATHIC MACULAR HOLE WITH DIFFERENT SURGICAL TECHNIQUES**

**Author and Co-authors:** Luiz Filipe Adami Lucatto, Felipe Muralha, Alex Grupmenmacher, Luis Filipe Nakayama, Natasha Ferreira Santos da Cruz, Murilo Ubukata Polizelli, Octaviano Magalhães da Silva Jr, Mauricio Maia

**Purpose:** To compare anatomic and functional results, and to evaluate postoperatively the healing process in 2 different techniques for the closure of the macular holes (MH)

**Methods:** Patients with macular holes classified in stages 3 and 4 will be randomized into 2 groups. In Group A, patients will undergo peeling with complete removal of the internal limiting membrane (ILM) and in the group B, the inverted ILM peeling technique will be performed. The 20% SF6 gas will be used as a tamponade agent in all surgeries, and OCT images will be performed in the first 5 postoperative days and months 1, 3 and 6. Inclusion criteria: - Stage 3 and 4 MH with visual acuity between 20/30 and 20/800 according to the ETDRS chart. Exclusion criteria: MH secondary to ocular trauma, myopia or retinal detachment Any previous treatment for the MH Evidence on examination of any diabetic retinopathy History or presence of wet or dry AMD Presence of epiretinal membrane or prior uveitis Any ocular surgery within 3 months before baseline Intra or periocular infection The primary outcome is anatomic closure of the MH closure in the month 6. The second outcomes are: mean best corrected visual acuity (BCVA) at month 6, mean change in the BCVA at month 6, integrity of the perifoveal external limiting membrane and ellipsoid zone on OCT, MH closure rate over time in days, functional improvement of microperimetry. Statistical analysis will be performed with Student t-test and the p-value of  $\leq 0.05$  is considered significant.

**Results:** Twenty nine eyes were included in the study (12 randomized to Group A and 17 to Group B). One of the patients randomized to the group B required silicone oil implant and was excluded. Twenty eight eyes had the macular hole closed at first day postoperatively. One patient randomized to Grupo A had persistente macular hole.

**Conclusion:** This study is in progress and 11 eyes from 10 patients has already complete Final visit.. One patient lost the follow-up visits and was removed from the study. So far, we have evaluated that 96,5% of patients had anatomical success with macular hole closure on the first day. This study was designed to evaluate anatomical and functional differences comparing two surgical techniques. When fully developed this data will be useful for comprehension of mechanisms related to closure of the macular hole.

**Keywords:** Macular hole, IML Peeling, Inverted ILM Peeling

## 2019 Research Days Abstract Form

### 2. SCIENTIFIC SECTION PREFERENCE (REQUIRED):

Review the Scientific Section Descriptions. Select and enter the two-letter Code for the one (1) Section best suited to review your abstract.

**(RE) RETINA AND VITREOUS**

### 3. PRESENTATION PREFERENCE (REQUIRED)

Check one:

**(RE) RETINA AND VITREOUS**

4. The signature of the First (Presenting) Author (REQUIRED) acting as the authorized agent for all authors, hereby certifies that any research reported was conducted in compliance with the Declaration of Helsinki and the "UNIFESP Ethical Committee"

### Scientific Section Descriptions (two-letter code):

(BE) OCULAR BIOENGINEERING  
(CO) CORNEA AND EXTERNAL DISEASE  
(CA) CATARACT  
(EF) ELECTROPHYSIOLOGY  
(EP) EPIDEMIOLOGY  
(EX) EXPERIMENTAL SURGERY  
(GL) GLAUCOMA  
(LA) LABORATORY  
(LS) LACRIMAL SYSTEM  
(LV) LOW VISION  
(NO) NEURO-OPHTHALMOLOGY  
(OR) ORBIT  
(PL) OCULAR PLASTIC SURGERY  
(PH) PHARMACOLOGY  
(RE) RETINA AND VITREOUS  
(RS) REFRACTIVE SURGERY  
(RX) REFRACTION-CONTACT LENSES  
(ST) STRABISMUS  
(TR) TRAUMA  
(TU) TUMORS AND PATHOLOGY  
(UV) UVEITIS  
(US) OCULAR ULTRASOUND

Deadline: 10/2019

### FORMAT:

#### Abstract should contain:

Title  
Author  
Co-authors (maximum 6)  
Purpose  
Methods  
Results  
Conclusion  
Keywords

Poster guidelines:  
**90cm x 120cm**

### FIRST (PRESENTING) AUTHOR (REQUIRED):

**Name:** Mariana Antunes Davi - R1  
**e-mail:** ma.antunes.d@hotmail.com  
**CEP Number:** 04024-00

### 5. ABSTRACT (REQUIRED):

**Title: Posterior uveitis with retinal vasculitis secondary to Behçet disease: a case report.**

**Author and Co-authors:** Mariana Davi, Kimble Matos, André Maia, Diogo Souza Domiciano, Somaia Mitne.

**Purpose:** To describe a case of posterior uveitis with retinal vasculitis secondary to Behçet disease.

**Methods:** Review of medical record, laboratory work up and imaging exams.

**Results:** 31-years-old woman with sudden vision loss in both eyes for one day. At first evaluation, the best-corrected visual acuity (BCVA) was 20/100 in the right eye (OD) and 20/60 in the left eye (OS). Slit-lamp examination was normal. Fundoscopy showed tortuous vessels, macular whitish lesions with retinal hemorrhages in both eyes. Fluorescein angiography demonstrated macular occlusive vasculitis with retinal vein sheathing. Cystoid macular edema was showed on the optic coherence tomography. At medical record review, she reported episodes of oral painful ulcers during the last year. In biochemical examinations, there were no increases in inflammatory rate, angiotensin-converting enzyme or complement levels. Autoantibodies and serological tests for infectious diseases were negative. HLA-B51 was positive in this patient. Based on these findings, this case was diagnosed as posterior uveitis and retinal vasculitis associated with Behçet disease. The patient was treated with pulse IV methylprednisolone therapy followed by oral prednisone plus an injection of dexamethasone implant in the OD. After that, patient was given infliximab, according to the 2018 European League Against Rheumatism recommendations for the management of Behçet disease. BCVA one month after treatment was 20/200 in the OD and 20/20 in the OS and remains stable. There was a resolution of vasculitis and macular edema in both eyes, however, visual acuity in the right eye did not improve possibly due to foveal ischemia.

**Conclusion:** The patient evolved with a satisfactory response to the treatment due to prompt diagnosis and management of bilateral occlusive retinal vasculitis. The multidisciplinary approach was imperative to prevent more severe and permanent ocular damage.

**Keywords:** Behçet disease; posterior uveitis; retinal vasculitis.



## 2019 Research Days Abstract Form

### 2. SCIENTIFIC SECTION PREFERENCE (REQUIRED):

Review the Scientific Section Descriptions. Select and enter the two-letter Code for the one (1) Section best suited to review your abstract.

**(RE) RETINA AND VITREOUS**

### 3. PRESENTATION PREFERENCE (REQUIRED)

Check one:

**(RE) RETINA AND VITREOUS**

4. The signature of the First (Presenting) Author (REQUIRED) acting as the authorized agent for all authors, hereby certifies that any research reported was conducted in compliance with the Declaration of Helsinki and the "UNIFESP Ethical Committee"

### Scientific Section Descriptions (two-letter code):

(BE) OCULAR BIOENGINEERING  
(CO) CORNEA AND EXTERNAL DISEASE  
(CA) CATARACT  
(EF) ELECTROPHYSIOLOGY  
(EP) EPIDEMIOLOGY  
(EX) EXPERIMENTAL SURGERY  
(GL) GLAUCOMA  
(LA) LABORATORY  
(LS) LACRIMAL SYSTEM  
(LV) LOW VISION  
(NO) NEURO-OPHTHALMOLOGY  
(OR) ORBIT  
(PL) OCULAR PLASTIC SURGERY  
(PH) PHARMACOLOGY  
(RE) RETINA AND VITREOUS  
(RS) REFRACTIVE SURGERY  
(RX) REFRACTION-CONTACT LENSES  
(ST) STRABISMUS  
(TR) TRAUMA  
(TU) TUMORS AND PATHOLOGY  
(UV) UVEITIS  
(US) OCULAR ULTRASOUND

Deadline: 10/2019

### FORMAT:

#### Abstract should contain:

Title  
Author  
Co-authors (maximum 6)  
Purpose  
Methods  
Results  
Conclusion  
Keywords

Poster guidelines:  
**90cm x 120cm**

### FIRST (PRESENTING) AUTHOR (REQUIRED):

**Name:** Mariana Batista Gonçalves - PG1 - DO  
**e-mail:** mari-batista@bol.com.br  
**CEP Number:** 1418/2017

### 5. ABSTRACT (REQUIRED):

#### **Title: Intravitreal Dexamethasone Implant Migration into the Anterior Chamber**

**Author and Co-authors:** Mariana Batista Gonçalves, Bruno de Queiroz Alves, Raphael Moura, Octaviano Magalhães Jr, André Maia, Rubens Belford Jr, Marcos Pereira de Ávila, Marcelo Zas, Mario Saravia, Marcia Lousas, Lihteh Wu, Fernando Arevalo, Katia Delalibera Pacheco, Taylor Johnson, Michel Eid Farah, Francisco Jose Rodrigo

**Purpose:** To establish the prevalence and risk factors for intravitreal dexamethasone implant migration into the anterior chamber in eyes with macular edema.

**Methods:** This was a multicenter, retrospective, observational chart review of data that included patients with macular edema who had been treated with at least one intravitreal dexamethasone injection. Patients with incomplete chart information during the follow-up period were excluded.

**Results:** The prevalence of implant migration in 468 patients, considering the number of injections, was 1.6%, with significant associations between implant migration and cataract surgery ( $P = 0.043$ ) and intraocular lens status ( $P = 0.005$ ) and a trend toward statistical significance ( $P = 0.057$ ) with vitrectomy.

**Conclusion:** The risk of implant migration into the anterior chamber was 1.6%.

**Keywords:** anterior chamber, dexamethasone, intravitreal, migration

## 2019 Research Days Abstract Form

### 2. SCIENTIFIC SECTION PREFERENCE (REQUIRED):

Review the Scientific Section Descriptions. Select and enter the two-letter Code for the one (1) Section best suited to review your abstract.

**(RE) RETINA AND VITREOUS**

### 3. PRESENTATION PREFERENCE (REQUIRED)

Check one:

**(RE) RETINA AND VITREOUS**

4. The signature of the First (Presenting) Author (REQUIRED) acting as the authorized agent for all authors, hereby certifies that any research reported was conducted in compliance with the Declaration of Helsinki and the 'UNIFESP Ethical Committee'

### Scientific Section Descriptions (two-letter code):

(BE) OCULAR BIOENGINEERING  
(CO) CORNEA AND EXTERNAL DISEASE  
(CA) CATARACT  
(EF) ELECTROPHYSIOLOGY  
(EP) EPIDEMIOLOGY  
(EX) EXPERIMENTAL SURGERY  
(GL) GLAUCOMA  
(LA) LABORATORY  
(LS) LACRIMAL SYSTEM  
(LV) LOW VISION  
(NO) NEURO-OPHTHALMOLOGY  
(OR) ORBIT  
(PL) OCULAR PLASTIC SURGERY  
(PH) PHARMACOLOGY  
(RE) RETINA AND VITREOUS  
(RS) REFRACTIVE SURGERY  
(RX) REFRACTION-CONTACT LENSES  
(ST) STRABISMUS  
(TR) TRAUMA  
(TU) TUMORS AND PATHOLOGY  
(UV) UVEITIS  
(US) OCULAR ULTRASOUND

Deadline: 10/2019

### FORMAT:

#### Abstract should contain:

Title  
Author  
Co-authors (maximum 6)  
Purpose  
Methods  
Results  
Conclusion  
Keywords

Poster guidelines:  
**90cm x 120cm**

### FIRST (PRESENTING) AUTHOR (REQUIRED):

**Name:** Murilo Ubukata Polizelli - Fellow  
**e-mail:** murilopolizelli@gmail.com  
**CEP Number:** 17355319

### 5. ABSTRACT (REQUIRED):

**Title:** Changes in the optic disk and choroid related to haemodialysis using optical coherence tomography angiography.

**Author and Co-authors:** Murilo U Polizelli , Natasha F S da Cruz, Mauricio Maia, Andre Romano, José Medina, Mauricio Y Ibrahim, Rubens Belfort Jr.

**Purpose:** To evaluate the choroidal thickness and the vascular density of the optic disk after hemodialysis using optical coherence tomography angiography and to correlate those findings to intraocular pressure and best corrected visual acuity.

**Methods:** Six patients undergoing haemodialysis from the Hospital do Rim in Sao Paulo were included. Ophthalmologic examinations comprising the determination of the best corrected visual acuity, intraocular pressure, slit lamp exam and optical coherence tomography angiography (Swept Source OCT TRITON and Spectral Domain OCT AVANTI) were performed one hour before and one hour after hemodialysis in all patients. The retinal thickness and subfoveal choroidal thickness were measured manually using the software provided in the optical coherence tomography instrument. The mean vascular density was assessed with the density map provided by the tomography.

**Results:** Until now, measurements of subfoveal choroidal thickness, vascular density of the disk area were similar before and after hemodialysis. Vascular density of the macular area was reduced after dialysis in the density map. No difference was found in the clinical ophthalmological exam (best corrected visual acuity, intraocular pressure and slit lamp exam). Patients are still being recruited.

**Conclusion:** Haemodialysis has an important systemic effect, in this study we could analyze the choroidal vascular changes before and after this procedure. Perhaps in the future, the OCTA exam could be correlated to systemic blood vessels or systemic vascular diseases, being a reliable non-invasive assesment.

**Keywords:** haemodialysis, optical coherence tomography angiography, optic disk, vascular density

## 2019 Research Days Abstract Form

### 2. SCIENTIFIC SECTION PREFERENCE (REQUIRED):

Review the Scientific Section Descriptions. Select and enter the two-letter Code for the one (1) Section best suited to review your abstract.

**(RE) RETINA AND VITREOUS**

### 3. PRESENTATION PREFERENCE (REQUIRED)

Check one:

**(RE) RETINA AND VITREOUS**

4. The signature of the First (Presenting) Author (REQUIRED) acting as the authorized agent for all authors, hereby certifies that any research reported was conducted in compliance with the Declaration of Helsinki and the "UNIFESP Ethical Committee"

### Scientific Section Descriptions (two-letter code):

(BE) OCULAR BIOENGINEERING  
(CO) CORNEA AND EXTERNAL DISEASE  
(CA) CATARACT  
(EF) ELECTROPHYSIOLOGY  
(EP) EPIDEMIOLOGY  
(EX) EXPERIMENTAL SURGERY  
(GL) GLAUCOMA  
(LA) LABORATORY  
(LS) LACRIMAL SYSTEM  
(LV) LOW VISION  
(NO) NEURO-OPHTHALMOLOGY  
(OR) ORBIT  
(PL) OCULAR PLASTIC SURGERY  
(PH) PHARMACOLOGY  
(RE) RETINA AND VITREOUS  
(RS) REFRACTIVE SURGERY  
(RX) REFRACTION-CONTACT LENSES  
(ST) STRABISMUS  
(TR) TRAUMA  
(TU) TUMORS AND PATHOLOGY  
(UV) UVEITIS  
(US) OCULAR ULTRASOUND

Deadline: 10/2019

### FORMAT:

#### Abstract should contain:

Title  
Author  
Co-authors (maximum 6)  
Purpose  
Methods  
Results  
Conclusion  
Keywords

Poster guidelines:  
**90cm x 120cm**

### FIRST (PRESENTING) AUTHOR (REQUIRED):

**Name:** Nelson Chamma Capelanes - PG0 - DO  
**e-mail:** nelsonchamma@me.com  
**CEP Number:** 13330290

### 5. ABSTRACT (REQUIRED):

**Title: Evaluation of macular perfusion through OCT-Angiography in patients with diabetic macular edema submitted to intravitreal therapy with biodegradable dexamethasone implant (Ozurdex®)**

**Author and Co-authors:** Author: Nelson Chamma Capelanes Advisor: Professor Caio Vinicius Saito Regatieri Co-Advisor: Dr. Fernando Malerbi

**Purpose:** To compare retinal perfusion through OCT-Angiography (pre and posttreatment) in patients with diabetic macular edema submitted to intravitreal therapy with biodegradable dexamethasone implant (Ozurdex®).

**Methods:** - Patients with diabetic macular edema identified through clinical examination (fundoscopy) and confirmed by optical coherence tomography will be selected. After confirmation of edema and quantification of macular thickness, all patients will be scanned with the 3 mm x 3 mm scan pattern using Angioscan OCTA software for the RS-3000 Advance OCT system (Nidek). 60 eyes of 60 patients will be imaged on 3 successive clinic visits, one week before the procedure and 60 and 90 days after the intravitreal implant. Two different readers are measuring the area using generated en-face OCT-A images of the superficial capillary plexus (SCP) and deep capillary plexus (DCP) Microperimetry examination will be done in all visits.

**Results:** - 11 eyes of 11 patients submitted to the treatment so far - 08 female patients and 03 male patients - Average age: 56 years - Pre-treatment average foveal thickness: 553 µm

**Conclusion:** - 03 patients complete 90 days of Ozurdex implant so far - Perfusion data will be analyzed in the next weeks and preliminary results presented

**Keywords:** retina; macula; optical coherence tomography; diabetes macular edema; diabetic retinopathy

## 2019 Research Days Abstract Form

### 2. SCIENTIFIC SECTION PREFERENCE (REQUIRED):

Review the Scientific Section Descriptions. Select and enter the two-letter Code for the one (1) Section best suited to review your abstract.

**(RE) RETINA AND VITREOUS**

### 3. PRESENTATION PREFERENCE (REQUIRED)

Check one:

**(RE) RETINA AND VITREOUS**

4. The signature of the First (Presenting) Author (REQUIRED) acting as the authorized agent for all authors, hereby certifies that any research reported was conducted in compliance with the Declaration of Helsinki and the "UNIFESP Ethical Committee"

### Scientific Section Descriptions (two-letter code):

(BE) OCULAR BIOENGINEERING  
(CO) CORNEA AND EXTERNAL DISEASE  
(CA) CATARACT  
(EF) ELECTROPHYSIOLOGY  
(EP) EPIDEMIOLOGY  
(EX) EXPERIMENTAL SURGERY  
(GL) GLAUCOMA  
(LA) LABORATORY  
(LS) LACRIMAL SYSTEM  
(LV) LOW VISION  
(NO) NEURO-OPHTHALMOLOGY  
(OR) ORBIT  
(PL) OCULAR PLASTIC SURGERY  
(PH) PHARMACOLOGY  
(RE) RETINA AND VITREOUS  
(RS) REFRACTIVE SURGERY  
(RX) REFRACTION-CONTACT LENSES  
(ST) STRABISMUS  
(TR) TRAUMA  
(TU) TUMORS AND PATHOLOGY  
(UV) UVEITIS  
(US) OCULAR ULTRASOUND

Deadline: 10/2019

### FORMAT:

#### Abstract should contain:

Title  
Author  
Co-authors (maximum 6)  
Purpose  
Methods  
Results  
Conclusion  
Keywords

Poster guidelines:  
**90cm x 120cm**

### FIRST (PRESENTING) AUTHOR (REQUIRED):

**Name:** Nikoly Tigani Fares - Fellow  
**e-mail:** nik.fares@yahoo.com.br  
**CEP Number:** 0251/2019

### 5. ABSTRACT (REQUIRED):

#### **Title: PRE AND INTRAOPERATIVE GANGLION CELL LAYER FEATURES AS A PROGNOSTIC FACTOR OF IDIOPATHIC EPIRETINAL MEMBRANE SURGERY**

**Author and Co-authors:** Nikoly Tigani Fares, Nelson Sabrosa, Maurício Maia

**Purpose:** The purpose of the study is to evaluate anatomic, functional and immunohistochemical ganglion cell layer features and its correlation with idiopathic epiretinal membrane surgery.

**Methods:** Prospective, non-comparative study involving 11 eyes with idiopathic epiretinal membrane (ERM) with indication of pars plana vitrectomy and ERM peeling. Apart from a detailed ophthalmological exam, optical coherence tomography (SD-OCT) and autofluorescence exam, all patients were submitted to microperimetry (MAIA) and electroretinogram analysis before and after surgery. All of them underwent to four-port 23-g pars plana vitrectomy (PPV), ERM peeling after triamcinolone (40mg/ml) and inner limiting membrane (ILM) peeling with brilliant blue (0,5mg/ml). This removed membranes (ERM and ILM) were submitted to an immunohistochemical analysis in order to evaluate ganglion cell biomarkers such as glial fibrillary acidic protein (GFAP) and vimentin. Moreover, these findings were also correlated with surgery results and outcomes. Statistical analysis was performed using paired t-test, ANOVA and Pearson's test.

**Results:** Mean age was 69.0 years old, 55% were male and 45% female. Mean BCVA preoperatively was 0,2. Average time of low visual acuity complaint was 18,7 months and just 27% of subjects had been going under cataract surgery at the same eye before the complaint. Preoperative macular sensitivity was reduced in all subjects and most of them presented some delay at ganglion cell electroretinogram response. Only one subject has gone into surgery so far and postoperative analysis as well as immunohistochemical results are still on progress. According to this study's schedule, until December 2019, at least 6 patients will have done the surgery, in a way that it is going to be possible to improve our data and conclusion.

**Conclusion:** Not just preoperative factors but also intraoperative ones seem to play an important role on idiopathic ERM surgery prognosis. Therefore, it is important to point and study them in order to improve surgical success outcomes and patients' life quality.

**Keywords:** retinal ganglion cell; epiretinal membrane, internal limiting membrane peeling,

## 2019 Research Days Abstract Form

### 2. SCIENTIFIC SECTION PREFERENCE (REQUIRED):

Review the Scientific Section Descriptions. Select and enter the two-letter Code for the one (1) Section best suited to review your abstract.

**(RE) RETINA AND VITREOUS**

### 3. PRESENTATION PREFERENCE (REQUIRED)

Check one:

**(RE) RETINA AND VITREOUS**

4. The signature of the First (Presenting) Author (REQUIRED) acting as the authorized agent for all authors, hereby certifies that any research reported was conducted in compliance with the Declaration of Helsinki and the "UNIFESP Ethical Committee"

### Scientific Section Descriptions (two-letter code):

(BE) OCULAR BIOENGINEERING  
(CO) CORNEA AND EXTERNAL DISEASE  
(CA) CATARACT  
(EF) ELECTROPHYSIOLOGY  
(EP) EPIDEMIOLOGY  
(EX) EXPERIMENTAL SURGERY  
(GL) GLAUCOMA  
(LA) LABORATORY  
(LS) LACRIMAL SYSTEM  
(LV) LOW VISION  
(NO) NEURO-OPHTHALMOLOGY  
(OR) ORBIT  
(PL) OCULAR PLASTIC SURGERY  
(PH) PHARMACOLOGY  
(RE) RETINA AND VITREOUS  
(RS) REFRACTIVE SURGERY  
(RX) REFRACTION-CONTACT LENSES  
(ST) STRABISMUS  
(TR) TRAUMA  
(TU) TUMORS AND PATHOLOGY  
(UV) UVEITIS  
(US) OCULAR ULTRASOUND

Deadline: 10/2019

### FORMAT:

#### Abstract should contain:

Title  
Author  
Co-authors (maximum 6)  
Purpose  
Methods  
Results  
Conclusion  
Keywords

Poster guidelines:  
**90cm x 120cm**

### FIRST (PRESENTING) AUTHOR (REQUIRED):

**Name:** Paulo Alberto Cervi Rosa - R3  
**e-mail:** paulopacr@hotmail.com  
**CEP Number:** 19504719.

### 5. ABSTRACT (REQUIRED):

**Title: Evaluation of panretinal light coagulation effects in patients with diabetic retinopathy through multimodal fundus imaging**

**Author and Co-authors:** Rosa PAC, Nakayama LF, Bergamo VC, Moraes NSB

**Purpose:** To evaluate, through multimodal fundus imaging, the retinal alterations found in patients who underwent panretinal light coagulation, specially foveal avascular zone and macular choroidal thickness changes, with the aim of determining alterations in macular perfusion due to the treatment.

**Methods:** Patients with indication of panretinal light coagulation due to diabetic retinopathy who accept to participate of the study will be evaluated through swept source optic coherence tomography and optic coherence tomography angiography 3x3mm and 6x6mm. Initially, 10 patients will participate of the study and will be evaluated with the fundus ancillary exams prior to the panretinal light coagulation, which will be divided in 4 sessions for each patient, and will be evaluated one more time one month after the end of the treatment. The parameters of the exams performed will then be compared through descriptive statistics, being each patient his own "control group", to evaluate alterations in macular perfusion.

**Results:** This is an ongoing study in which five patients have finished the whole treatment and evaluation. Visual acuity mean was of 0,21 prior PFC and 0,24 after the treatment. Retinal thickness mean prior PFC of 334.40 micrometers (Standard Deviation (SD) of 133.76) and after of 373.80 micrometers (SD 244.96). Subfoveal Choroidal Thickness mean prior PFC was 327.20 micrometers (SD 176.47) and after PFC was 293.00 (SD 147.96). Foveal avascular Zone mean area prior PFC was 771.30 (SD 428.25) and after was 797.20 (SD 370.15).

**Conclusion:** Diabetes mellitus is one of the most prevalent diseases in the world and diabetic retinopathy is one of the main causes of low vision in adults. The understanding of Diabetic Retinopathy Pathophysiology and its response to current treatments is important to increase the effectiveness of treatment and determine expected results.

**Keywords:** diabetic retinopathy ; light coagulation ; retina

## 2019 Research Days Abstract Form

### 2. SCIENTIFIC SECTION PREFERENCE (REQUIRED):

Review the Scientific Section Descriptions. Select and enter the two-letter Code for the one (1) Section best suited to review your abstract.

**(RE) RETINA AND VITREOUS**

### 3. PRESENTATION PREFERENCE (REQUIRED)

Check one:

**(RE) RETINA AND VITREOUS**

4. The signature of the First (Presenting) Author (REQUIRED) acting as the authorized agent for all authors, hereby certifies that any research reported was conducted in compliance with the Declaration of Helsinki and the "UNIFESP Ethical Committee"

### Scientific Section Descriptions (two-letter code):

(BE) OCULAR BIOENGINEERING  
(CO) CORNEA AND EXTERNAL DISEASE  
(CA) CATARACT  
(EF) ELECTROPHYSIOLOGY  
(EP) EPIDEMIOLOGY  
(EX) EXPERIMENTAL SURGERY  
(GL) GLAUCOMA  
(LA) LABORATORY  
(LS) LACRIMAL SYSTEM  
(LV) LOW VISION  
(NO) NEURO-OPHTHALMOLOGY  
(OR) ORBIT  
(PL) OCULAR PLASTIC SURGERY  
(PH) PHARMACOLOGY  
(RE) RETINA AND VITREOUS  
(RS) REFRACTIVE SURGERY  
(RX) REFRACTION-CONTACT LENSES  
(ST) STRABISMUS  
(TR) TRAUMA  
(TU) TUMORS AND PATHOLOGY  
(UV) UVEITIS  
(US) OCULAR ULTRASOUND

Deadline: 10/2019

### FORMAT:

#### Abstract should contain:

Title  
Author  
Co-authors (maximum 6)  
Purpose  
Methods  
Results  
Conclusion  
Keywords

Poster guidelines:  
**90cm x 120cm**

### FIRST (PRESENTING) AUTHOR (REQUIRED):

**Name:** Zaira Fernanda Martinho Nicolau - R2  
**e-mail:** zairanicolau@hotmail.com  
**CEP Number:** 0000/2019

### 5. ABSTRACT (REQUIRED):

**Title:** Short-term outcomes of Susanna and Baerveldt glaucoma drainage implants surgery performed by surgeons in training

**Author and Co-authors:** Zaira Fernanda Martinho Nicolau, Luiz Alberto Soares de Melo Junior.

**Purpose:** To analyze the short-term clinical outcomes of Susanna and Baerveldt glaucoma implants surgery performed by surgeons in training.

**Methods:** A retrospective chart review of patients that underwent glaucoma drainage implant surgery using Susanna or Baerveldt models from January 2017 to March 2019 was performed. Data prior to the surgery and after one, three and six postoperative months regarding visual acuity, IOP, number of glaucoma medications, complications and reoperation were collected. Success was defined as a postoperative intraocular pressure (IOP) between 6 and 21 mmHg.

**Results:** A total of 35 eyes, 29 patients underwent the Susanna implant surgery and 6 underwent the Baerveldt implant surgery, were included in this study. The mean age was 55 years old. The most common types of glaucoma in these patients were primary open-angle glaucoma (31%), neovascular glaucoma (23%), and glaucoma secondary to surgery (23%). The eyes with Susanna implant had a mean preoperative IOP of 25.8 mmHg, 1-month postoperative IOP of 16 mmHg, 3-month postoperative IOP of 13.7 mmHg, and 6-month postoperative IOP of 13.8 mmHg. Prior to surgery the mean number of glaucoma eye drop medications in use in these patients were 2.4, and at six months was 1.3. In comparison, the eyes with Baerveldt implant had a mean preoperative IOP of 29.5 mmHg, 1-month postoperative IOP of 13.2 mmHg, 3-month postoperative IOP of 9.8 mmHg and 6-month postoperative IOP of 9.5 mmHg. They used a mean of 2.2 glaucoma eye drop medications before surgery and 0.8 after 6 months of surgery. A total of 76% of the patients who underwent Susanna implant had complications, and 35% required surgical approach before six months of follow up. In the Baerveldt group, all patients had at least one complication, with a need of surgical approach in 17%. In both groups the most common complication was hypotonia. The success rate after six months of follow up was of 86.2% with the Susanna implant and 100% with the Baerveldt implant.

**Conclusion:** Both implants achieved high success rate. The mean IOP was reduced in both groups, with a need of less glaucoma medications. Both implants should be considered good options for glaucoma treatment.

**Keywords:** Glaucoma drainage implant, glaucoma, surgery, intraocular pressure.

## 2019 Research Days Abstract Form

### 2. SCIENTIFIC SECTION PREFERENCE (REQUIRED):

Review the Scientific Section Descriptions. Select and enter the two-letter Code for the one (1) Section best suited to review your abstract.

**(UV) UVEITIS**

### 3. PRESENTATION PREFERENCE (REQUIRED)

Check one:

**(UV) UVEITIS**

4. The signature of the First (Presenting) Author (REQUIRED) acting as the authorized agent for all authors, hereby certifies that any research reported was conducted in compliance with the Declaration of Helsinki and the "UNIFESP Ethical Committee"

### Scientific Section Descriptions (two-letter code):

(BE) OCULAR BIOENGINEERING  
(CO) CORNEA AND EXTERNAL DISEASE  
(CA) CATARACT  
(EF) ELECTROPHYSIOLOGY  
(EP) EPIDEMIOLOGY  
(EX) EXPERIMENTAL SURGERY  
(GL) GLAUCOMA  
(LA) LABORATORY  
(LS) LACRIMAL SYSTEM  
(LV) LOW VISION  
(NO) NEURO-OPHTHALMOLOGY  
(OR) ORBIT  
(PL) OCULAR PLASTIC SURGERY  
(PH) PHARMACOLOGY  
(RE) RETINA AND VITREOUS  
(RS) REFRACTIVE SURGERY  
(RX) REFRACTION-CONTACT LENSES  
(ST) STRABISMUS  
(TR) TRAUMA  
(TU) TUMORS AND PATHOLOGY  
(UV) UVEITIS  
(US) OCULAR ULTRASOUND

Deadline: 10/2019

### FORMAT:

#### Abstract should contain:

Title  
Author  
Co-authors (maximum 6)  
Purpose  
Methods  
Results,  
Conclusion  
Keywords

Poster guidelines:  
**90cm x 120cm**

### FIRST (PRESENTING) AUTHOR (REQUIRED):

**Name:** Vivian Cristina Costa Afonso - PG0 - DO  
**e-mail:** vivian\_cris@yahoo.com.br  
**CEP Number:** 0896/2018

### 5. ABSTRACT (REQUIRED):

**Title: Non- infectious intermediate, posterior or pan uveitis using Biologic Agents**

**Author and Co-authors:** Afonso,Vivian CC Muccioli,Cristina Nascimento, Heloisa

**Purpose:** This study observes patients with non-infectious, intermediate, posterior or pan uveitis receiving biological agents. The patients enrolled were observed during 1 year, during the treatment with biological agents. Inflammatory ocular disease were measured. The use of corticosteroid support and others immunosuppressants were noticed if there was any increase or decrease of the usage of these drugs

**Methods:** The patients enrolled were observed during 1 year of treatment since the initial of therapeutic with biological agents. Clinic examination were scheduled to occur at sreecrening, at baseline, 30 days and 90 days, 180 days and 1 year.The chi square test and student 's test will be used for this statistic study

**Results:** The study is still in progress.

**Conclusion:** The conclusion will be presented in some months, when the treatment finishes. The patients are still being accompanied. By the end of the study , the statistical analysis will be performed.

**Keywords:** Biologic agents/Uveitis non infeccious

## 2019 Research Days Abstract Form

### 2. SCIENTIFIC SECTION PREFERENCE (REQUIRED):

Review the Scientific Section Descriptions. Select and enter the two-letter Code for the one (1) Section best suited to review your abstract.

**(CO) CORNEA AND EXTERNAL DISEASE**

### 3. PRESENTATION PREFERENCE (REQUIRED)

Check one:

**(CO) CORNEA AND EXTERNAL DISEASE**

4. The signature of the First (Presenting) Author (REQUIRED) acting as the authorized agent for all authors, hereby certifies that any research reported was conducted in compliance with the Declaration of Helsinki and the "UNIFESP Ethical Committee"

### Scientific Section Descriptions (two-letter code):

(BE) OCULAR BIOENGINEERING  
(CO) CORNEA AND EXTERNAL DISEASE  
(CA) CATARACT  
(EF) ELECTROPHYSIOLOGY  
(EP) EPIDEMIOLOGY  
(EX) EXPERIMENTAL SURGERY  
(GL) GLAUCOMA  
(LA) LABORATORY  
(LS) LACRIMAL SYSTEM  
(LV) LOW VISION  
(NO) NEURO-OPHTHALMOLOGY  
(OR) ORBIT  
(PL) OCULAR PLASTIC SURGERY  
(PH) PHARMACOLOGY  
(RE) RETINA AND VITREOUS  
(RS) REFRACTIVE SURGERY  
(RX) REFRACTION-CONTACT LENSES  
(ST) STRABISMUS  
(TR) TRAUMA  
(TU) TUMORS AND PATHOLOGY  
(UV) UVEITIS  
(US) OCULAR ULTRASOUND

Deadline: 10/2019

### FORMAT:

#### Abstract should contain:

Title  
Author  
Co-authors (maximum 6)  
Purpose  
Methods  
Results  
Conclusion  
Keywords

Poster guidelines:  
**90cm x 120cm**

### FIRST (PRESENTING) AUTHOR (REQUIRED):

**Name:** Beatriz Nugent da Cunha - R2  
**e-mail:** beatriznug@gmail.com  
**CEP Number:** 1118-2018

### 5. ABSTRACT (REQUIRED):

**Title: Ocular Surface Disease Index (OSDI) questionnaire survey in proliferative diabetic retinopathy subjects**

**Author and Co-authors:** Beatriz Nugent da Cunha, Bruno Mauricio Rodrigues de Oliveira, Jose Aparecido Job Neto, Denise de Freitas, Octaviano Magalhães Junior

**Purpose:** To measure the severity of dry eye disease symptoms and its effect on visual-related function in subjects with proliferative diabetic retinopathy, using the Ocular Surface Disease Index (OSDI) score

**Methods:** This is an observational study of patients with proliferative diabetic retinopathy without previous ocular treatment. All patients were evaluated using the OSDI questionnaire prior to the beginning of panretinal photocoagulation.

**Results:** So far, eleven patients met the inclusion criteria and were recruited.

**Conclusion:** In progress.

**Keywords:** diabetic retinopathy, dry eye disease, laser photocoagulation, questionnaire



## 2019 Research Days Abstract Form

### 2. SCIENTIFIC SECTION PREFERENCE (REQUIRED):

Review the Scientific Section Descriptions. Select and enter the two-letter Code for the one (1) Section best suited to review your abstract.

**(CO) CORNEA AND EXTERNAL DISEASE**

### 3. PRESENTATION PREFERENCE (REQUIRED)

Check one:

**(CO) CORNEA AND EXTERNAL DISEASE**

4. The signature of the First (Presenting) Author (REQUIRED) acting as the authorized agent for all authors, hereby certifies that any research reported was conducted in compliance with the Declaration of Helsinki and the "UNIFESP Ethical Committee"

Scientific Section Descriptions (two-letter code):

(BE) OCULAR BIOENGINEERING  
(CO) CORNEA AND EXTERNAL DISEASE  
(CA) CATARACT  
(EF) ELECTROPHYSIOLOGY  
(EP) EPIDEMIOLOGY  
(EX) EXPERIMENTAL SURGERY  
(GL) GLAUCOMA  
(LA) LABORATORY  
(LS) LACRIMAL SYSTEM  
(LV) LOW VISION  
(NO) NEURO-OPHTHALMOLOGY  
(OR) ORBIT  
(PL) OCULAR PLASTIC SURGERY  
(PH) PHARMACOLOGY  
(RE) RETINA AND VITREOUS  
(RS) REFRACTIVE SURGERY  
(RX) REFRACTION-CONTACT LENSES  
(ST) STRABISMUS  
(TR) TRAUMA  
(TU) TUMORS AND PATHOLOGY  
(UV) UVEITIS  
(US) OCULAR ULTRASOUND

Deadline: 10/2019

### FORMAT:

#### Abstract should contain:

Title  
Author  
Co-authors (maximum 6)  
Purpose  
Methods  
Results  
Conclusion  
Keywords

Poster guidelines:  
**90cm x 120cm**

### FIRST (PRESENTING) AUTHOR (REQUIRED):

**Name:** Camila Maria Valente - Fellow  
**e-mail:** cami\_valente@hotmail.com  
**CEP Number:** 1206/2018

### 5. ABSTRACT (REQUIRED):

**Title: Effect of povidone-iodine on Candida parapsilosis biofilm in gelatinous contact lens**

**Author and Co-authors:** Camila Maia Valente<sup>1</sup>, Larissa Rigobeli da Rosa<sup>1</sup>, Ana Luisa Hofling-Lima<sup>1</sup>, Analy Salles de A. Melo<sup>2</sup>, Lauro Augusto de Oliveira<sup>1</sup> 1. Department of Ophthalmology and Visual Sciences, Paulista School of Medicine, Federal University of São Paulo, São Paulo, Brazil. 2. Department of Microbiology, Immunol

**Purpose:** To evaluate the efficacy of povidone iodine in inhibiting Candida parapsilosis biofilm in silicone-hydrogel disposable contact lens.

**Methods:** Candida parapsilosis (ATCC: zz019) was used to induce biofilm formation in silicone-hydrogel disposable contact lens. One percent povidone ? iodine was tested in two different stages: during the biofilm formation and also with biofilm established. Microorganism/biofilm viability was measured using tetrazolium XTT [2,3-bis(2-methoxy-4-nitro-5-sulphophenyl)-2H-tetrazolium-5-carboxanilide] and spectrophotometry.

**Results:** Spectrophotometric readings were lower with 1% povidone-iodine both during biofilm formation and also with biofilm established (0,404 nm and 0,944 nm, respectively) when compared to positive control (1,585 nm).

**Conclusion:** One percent povidone-iodine demonstrated interesting results reducing Candida Parapsilosis biofilm formation and its metabolism in soft silicone-hydrogel disposable contact lens.

**Keywords:** Biofilm, contact lens, povidone-iodine

## 2019 Research Days Abstract Form

### 2. SCIENTIFIC SECTION PREFERENCE (REQUIRED):

Review the Scientific Section Descriptions. Select and enter the two-letter Code for the one (1) Section best suited to review your abstract.

**(CO) CORNEA AND EXTERNAL DISEASE**

### 3. PRESENTATION PREFERENCE (REQUIRED)

Check one:

**(CO) CORNEA AND EXTERNAL DISEASE**

4. The signature of the First (Presenting) Author (REQUIRED) acting as the authorized agent for all authors, hereby certifies that any research reported was conducted in compliance with the Declaration of Helsinki and the "UNIFESP Ethical Committee"

### Scientific Section Descriptions (two-letter code):

(BE) OCULAR BIOENGINEERING  
(CO) CORNEA AND EXTERNAL DISEASE  
(CA) CATARACT  
(EF) ELECTROPHYSIOLOGY  
(EP) EPIDEMIOLOGY  
(EX) EXPERIMENTAL SURGERY  
(GL) GLAUCOMA  
(LA) LABORATORY  
(LS) LACRIMAL SYSTEM  
(LV) LOW VISION  
(NO) NEURO-OPHTHALMOLOGY  
(OR) ORBIT  
(PL) OCULAR PLASTIC SURGERY  
(PH) PHARMACOLOGY  
(RE) RETINA AND VITREOUS  
(RS) REFRACTIVE SURGERY  
(RX) REFRACTION-CONTACT LENSES  
(ST) STRABISMUS  
(TR) TRAUMA  
(TU) TUMORS AND PATHOLOGY  
(UV) UVEITIS  
(US) OCULAR ULTRASOUND

Deadline: 10/2019

### FORMAT:

#### Abstract should contain:

Title  
Author  
Co-authors (maximum 6)  
Purpose  
Methods  
Results  
Conclusion  
Keywords

Poster guidelines:  
**90cm x 120cm**

### FIRST (PRESENTING) AUTHOR (REQUIRED):

**Name:** Franklin Kuraoka Oda - R1  
**e-mail:** oda.epm@gmail.com  
**CEP Number:** 4024003

### 5. ABSTRACT (REQUIRED):

**Title: Case report: unusual evolution of a dermoid cyst after surgical excision.**

**Author and Co-authors:** Franklin Kuraoka Oda, Denise de Freitas, José Job Neto

**Purpose:** To present an atypical corneal lesion in a 12 years old patient following a dermoid cyst laser and surgical excision

**Methods:** This is a case report of a 12 years old patient evaluated at the Cornea and External Disease sector of the Ophthalmology service at the Paulista School of Medicine, São Paulo - Brazil. The patient refers the appearance of a white spot lesion at the left eye corneal surface, which was first unsuccessfully removed with a laser procedure and then surgically excised with good results (in another service in his home town). The anatomic pathology analysis showed "epidermoid cyst or inclusion cyst". However, the lesion returned 4 months later bigger and in a different form, as a whitish amorphous mass in the anterior chamber. The patient had no remarkable past medical nor ophthalmological history. His visual acuity was 20/20 in the right eye and 20/40 in the left eye, the intraocular pressure and fundus examination were both normal. Complementary exams include: ocular ultrasonography and anterior segment optical coherence tomography.

**Results:** This is an ongoing case and the patient is waiting for preoperative evaluation and the lesion is yet to be surgically removed and analyzed by the pathology sector.

**Conclusion:** In progress

**Keywords:** Cornea and External Disease, Dermoid cyst, Inclusion cyst

## 2019 Research Days Abstract Form

### 2. SCIENTIFIC SECTION PREFERENCE (REQUIRED):

Review the Scientific Section Descriptions. Select and enter the two-letter Code for the one (1) Section best suited to review your abstract.

**(CO) CORNEA AND EXTERNAL DISEASE**

### 3. PRESENTATION PREFERENCE (REQUIRED)

Check one:

**(CO) CORNEA AND EXTERNAL DISEASE**

4. The signature of the First (Presenting) Author (REQUIRED) acting as the authorized agent for all authors, hereby certifies that any research reported was conducted in compliance with the Declaration of Helsinki and the "UNIFESP Ethical Committee"

Scientific Section Descriptions (two-letter code):

(BE) OCULAR BIOENGINEERING  
(CO) CORNEA AND EXTERNAL DISEASE  
(CA) CATARACT  
(EF) ELECTROPHYSIOLOGY  
(EP) EPIDEMIOLOGY  
(EX) EXPERIMENTAL SURGERY  
(GL) GLAUCOMA  
(LA) LABORATORY  
(LS) LACRIMAL SYSTEM  
(LV) LOW VISION  
(NO) NEURO-OPHTHALMOLOGY  
(OR) ORBIT  
(PL) OCULAR PLASTIC SURGERY  
(PH) PHARMACOLOGY  
(RE) RETINA AND VITREOUS  
(RS) REFRACTIVE SURGERY  
(RX) REFRACTION-CONTACT LENSES  
(ST) STRABISMUS  
(TR) TRAUMA  
(TU) TUMORS AND PATHOLOGY  
(UV) UVEITIS  
(US) OCULAR ULTRASOUND

Deadline: 10/2019

### FORMAT:

**Abstract should contain:**

Title  
Author  
Co-authors (maximum 6)  
Purpose  
Methods  
Results  
Conclusion  
Keywords

Poster guidelines:  
**90cm x 120cm**

### FIRST (PRESENTING) AUTHOR (REQUIRED):

**Name:** José Aparecido Job Neto - R4  
**e-mail:** jjobneto@hotmail.com  
**CEP Number:** 1118-2018

### 5. ABSTRACT (REQUIRED):

**Title: Optical coherence tomography angiography of conjunctival vessels in proliferative diabetic retinopathy subjects**

**Author and Co-authors:** José Aparecido Job Neto Bruno Mauricio Rodrigues de Oliveira Octaviano Magalhães Junior Denise de Freitas

**Purpose:** To evaluate conjunctival vessels features of proliferative diabetic retinopathy subjects before and after panretinal photocoagulation using OCT angiography (Triton)  
**Methods:** This is an observational, prospective study in which the bulbar conjunctiva vasculature will be evaluated using optical coherence tomography angiography prior to panretinal laser photocoagulation and after three months of the procedure. The images of the corneal limbus at the superior quadrant with an area of 3x3 mm were evaluated to a depth of 500 µm and then processed using binarization and the vessel density was defined as the ratio of the area occupied by the vessels divided by the total area, using ImageJ software.

**Results:** So far, eleven subjects met the inclusion criteria and were recruited. Panretinal photocoagulation and exams are in progress.

**Conclusion:** in progress

**Keywords:** Diabetes, panretinal laser photocoagulation, diabetic retinopathy, conjunctival optical coherence tomography angiography,

## 2019 Research Days Abstract Form

### 2. SCIENTIFIC SECTION PREFERENCE (REQUIRED):

Review the Scientific Section Descriptions. Select and enter the two-letter Code for the one (1) Section best suited to review your abstract.

**(CO) CORNEA AND EXTERNAL DISEASE**

### 3. PRESENTATION PREFERENCE (REQUIRED)

Check one:

**(CO) CORNEA AND EXTERNAL DISEASE**

4. The signature of the First (Presenting) Author (REQUIRED) acting as the authorized agent for all authors, hereby certifies that any research reported was conducted in compliance with the Declaration of Helsinki and the "UNIFESP Ethical Committee"

### Scientific Section Descriptions (two-letter code):

(BE) OCULAR BIOENGINEERING  
(CO) CORNEA AND EXTERNAL DISEASE  
(CA) CATARACT  
(EF) ELECTROPHYSIOLOGY  
(EP) EPIDEMIOLOGY  
(EX) EXPERIMENTAL SURGERY  
(GL) GLAUCOMA  
(LA) LABORATORY  
(LS) LACRIMAL SYSTEM  
(LV) LOW VISION  
(NO) NEURO-OPHTHALMOLOGY  
(OR) ORBIT  
(PL) OCULAR PLASTIC SURGERY  
(PH) PHARMACOLOGY  
(RE) RETINA AND VITREOUS  
(RS) REFRACTIVE SURGERY  
(RX) REFRACTION-CONTACT LENSES  
(ST) STRABISMUS  
(TR) TRAUMA  
(TU) TUMORS AND PATHOLOGY  
(UV) UVEITIS  
(US) OCULAR ULTRASOUND

Deadline: 10/2019

### FORMAT:

#### Abstract should contain:

Title  
Author  
Co-authors (maximum 6)  
Purpose  
Methods  
Results  
Conclusion  
Keywords

Poster guidelines:  
**90cm x 120cm**

### FIRST (PRESENTING) AUTHOR (REQUIRED):

**Name:** José Arthur Pinto Milhomens - R2  
**e-mail:** milhomens.af@outlook.com  
**CEP Number:** 1661263

### 5. ABSTRACT (REQUIRED):

**Title: Infectious keratitis following corneal transplantation**

**Author and Co-authors:** José Arthur Pinto Milhomens Filho, Aline Silveira Moriyama, Ana Luisa Höfling-Lima

**Purpose:** To evaluate microbiological and clinical profile of infectious keratitis cases following corneal transplantation at Ophthalmology and Visual Sciences Department at Escola Paulista de Medicina ? UNIFESP.

**Methods:** A retrospective study was conducted among patients who had samples sent to the Ophthalmic Microbiology Laboratory from the 1st of January 2015 to the 31th of December 2016. All patients with history of corneal transplantation were selected. Data regarding age, gender, etiologic agent, time lapse from the corneal transplant, type of corneal transplant (penetrating keratoplasty, anterior lamellar keratoplasty or posterior lamellar keratoplasty), antimicrobial resistance profile and visual acuity outcome were collected.

**Results:** From an overall of 100 samples sent to Ophthalmic Microbiology Laboratory during the studied period, 88 were selected with a history of previous corneal transplantation. Male to female ratio was 2,22 : 1,0. Mean age was 54,85 (standard deviation  $\pm 22,04$ ). Bacterial isolates accounted for the majority of the cases ( 90,22%), followed by fungal (8,20%) and parasitic (1,58%) isolates. Among bacterial keratitis cases, the most frequent isolates were coagulase negative Staphylococcus, Streptococcus spp, Staphylococcus aureus, Corynebacterium spp and Pseudomonas spp. Antibiogram is yet to be calculated, specially for coagulase negative Staphylococcus and Pseudomonas sp.

**Conclusion:** Bacteria were the main isolates from infectious keratitis following corneal transplantation. Microbiological findings of the present study support current standardized empiric treatment protocols at our institution with monotherapy with fourth generation fluoroquinolones or classical therapy with fortified cephalosporins combined with aminoglycoside.

**Keywords:** Corneal transplant; keratitis

## 2019 Research Days Abstract Form

### 2. SCIENTIFIC SECTION PREFERENCE (REQUIRED):

Review the Scientific Section Descriptions. Select and enter the two-letter Code for the one (1) Section best suited to review your abstract.

**(CO) CORNEA AND EXTERNAL DISEASE**

### 3. PRESENTATION PREFERENCE (REQUIRED)

Check one:

**(CO) CORNEA AND EXTERNAL DISEASE**

4. The signature of the First (Presenting) Author (REQUIRED) acting as the authorized agent for all authors, hereby certifies that any research reported was conducted in compliance with the Declaration of Helsinki and the "UNIFESP Ethical Committee"

Scientific Section Descriptions (two-letter code):

(BE) OCULAR BIOENGINEERING  
(CO) CORNEA AND EXTERNAL DISEASE  
(CA) CATARACT  
(EF) ELECTROPHYSIOLOGY  
(EP) EPIDEMIOLOGY  
(EX) EXPERIMENTAL SURGERY  
(GL) GLAUCOMA  
(LA) LABORATORY  
(LS) LACRIMAL SYSTEM  
(LV) LOW VISION  
(NO) NEURO-OPHTHALMOLOGY  
(OR) ORBIT  
(PL) OCULAR PLASTIC SURGERY  
(PH) PHARMACOLOGY  
(RE) RETINA AND VITREOUS  
(RS) REFRACTIVE SURGERY  
(RX) REFRACTION-CONTACT LENSES  
(ST) STRABISMUS  
(TR) TRAUMA  
(TU) TUMORS AND PATHOLOGY  
(UV) UVEITIS  
(US) OCULAR ULTRASOUND

Deadline: 10/2019

### FORMAT:

#### Abstract should contain:

Title  
Author  
Co-authors (maximum 6)  
Purpose  
Methods  
Results  
Conclusion  
Keywords

Poster guidelines:  
**90cm x 120cm**

### FIRST (PRESENTING) AUTHOR (REQUIRED):

**Name:** Raysa Victoria de Oliveira Cechim - R4  
**e-mail:** ray\_cechim@hotmail.com  
**CEP Number:** 0

### 5. ABSTRACT (REQUIRED):

**Title: SYSTEMIC CYCLOSPORINE FOR SEVERE ALLERGIC KERATOCONJUNCTIVITIS**

**Author and Co-authors:** Raysa Victoria de Oliveira Cechim, Myrna Serapiao dos Santos, Tais Hitomi Wakamatsu e Márcia Malozzi

**Purpose:** Evaluate a clinical response of patients with severe forms of ocular allergy after the introduction of systemic cyclosporine, Evaluate dose and time required for treatment and Identify effects related to medication,

**Methods:** Case series study through medical records analysis. We will analyze all the medical records of patients with severe allergic keratoconjunctivitis difficult to control with conventional treatment, submitted to systemic immunosuppression with Ciclosporin A. The patients are following at the Department of External Ocular and Corneal Diseases and at the Allergy Department of the Paulista School of Medicine. The variables analyzed will be: epidemiological profile, diagnosis and time of evolution of ocular allergy, previous treatments, reason for indicating immunosuppression, dose of medication used, time of treatment, whether there was disease control with medication, side effects of treatment and if need complementary treatment.

**Results:** In progress

**Conclusion:** In progress

**Keywords:** allergy, allergic keratoconjunctivitis, cyclosporine systemic

## 2019 Research Days Abstract Form

### 2. SCIENTIFIC SECTION PREFERENCE (REQUIRED):

Review the Scientific Section Descriptions. Select and enter the two-letter Code for the one (1) Section best suited to review your abstract.

**(CO) CORNEA AND EXTERNAL DISEASE**

### 3. PRESENTATION PREFERENCE (REQUIRED)

Check one:

**(CO) CORNEA AND EXTERNAL DISEASE**

4. The signature of the First (Presenting) Author (REQUIRED) acting as the authorized agent for all authors, hereby certifies that any research reported was conducted in compliance with the Declaration of Helsinki and the "UNIFESP Ethical Committee"

### Scientific Section Descriptions (two-letter code):

(BE) OCULAR BIOENGINEERING  
(CO) CORNEA AND EXTERNAL DISEASE  
(CA) CATARACT  
(EF) ELECTROPHYSIOLOGY  
(EP) EPIDEMIOLOGY  
(EX) EXPERIMENTAL SURGERY  
(GL) GLAUCOMA  
(LA) LABORATORY  
(LS) LACRIMAL SYSTEM  
(LV) LOW VISION  
(NO) NEURO-OPHTHALMOLOGY  
(OR) ORBIT  
(PL) OCULAR PLASTIC SURGERY  
(PH) PHARMACOLOGY  
(RE) RETINA AND VITREOUS  
(RS) REFRACTIVE SURGERY  
(RX) REFRACTION-CONTACT LENSES  
(ST) STRABISMUS  
(TR) TRAUMA  
(TU) TUMORS AND PATHOLOGY  
(UV) UVEITIS  
(US) OCULAR ULTRASOUND

Deadline: 10/2019

### FORMAT:

#### Abstract should contain:

Title  
Author  
Co-authors (maximum 6)  
Purpose  
Methods  
Results,  
Conclusion  
Keywords

Poster guidelines:  
**90cm x 120cm**

### FIRST (PRESENTING) AUTHOR (REQUIRED):

**Name:** Renata Macedo Nabuco Faro - R4  
**e-mail:** renatamnfaro@gmail.com  
**CEP Number:** 0

### 5. ABSTRACT (REQUIRED):

**Title: Vision-related quality of life in patients undergone Intrastromal Corneal Ring Segment implantation, adaptation to contact lens and corneal transplantation**

**Author and Co-authors:** Renata Macedo Nabuco Faro, Advisor: Professor Luciene Barbosa de Sousa Co-advisor: Professor Pablo F Rodrigues

**Purpose:** To assess vision-related quality of life in keratoconus patients who underwent Intrastromal Corneal Ring Segment implantation, corneal transplantation, and contact lens fitting due to keratoconus.

**Methods:** TYPE OF STUDY Prospective, observational, cross-sectional, descriptive and analytical PLACE Ophthalmology Department, Escola Paulista de Medicina, located at Rua Botucatu, 821 - São Paulo ?SP, through the examination of ambulatory patients with keratoconus diagnosis.

**Results:** Some diseases are believed to be the result of emotional distress and poor management of human emotions . Similarly, it was observed that people with chronic diseases show similar personalities . Concomitant with personality, quality of life can also be affected by diseases and their treatments. Eye diseases have a major impact on quality of life, as decreased visual acuity (VA) is a major cause of disability

**Conclusion:** in progress

**Keywords:** vision-related quality of life, keratoconus

## 2019 Research Days Abstract Form

### 2. SCIENTIFIC SECTION PREFERENCE (REQUIRED):

Review the Scientific Section Descriptions. Select and enter the two-letter Code for the one (1) Section best suited to review your abstract.

**(CO) CORNEA AND EXTERNAL DISEASE**

### 3. PRESENTATION PREFERENCE (REQUIRED)

Check one:

**(CO) CORNEA AND EXTERNAL DISEASE**

4. The signature of the First (Presenting) Author (REQUIRED) acting as the authorized agent for all authors, hereby certifies that any research reported was conducted in compliance with the Declaration of Helsinki and the "UNIFESP Ethical Committee"

### Scientific Section Descriptions (two-letter code):

(BE) OCULAR BIOENGINEERING  
(CO) CORNEA AND EXTERNAL DISEASE  
(CA) CATARACT  
(EF) ELECTROPHYSIOLOGY  
(EP) EPIDEMIOLOGY  
(EX) EXPERIMENTAL SURGERY  
(GL) GLAUCOMA  
(LA) LABORATORY  
(LS) LACRIMAL SYSTEM  
(LV) LOW VISION  
(NO) NEURO-OPHTHALMOLOGY  
(OR) ORBIT  
(PL) OCULAR PLASTIC SURGERY  
(PH) PHARMACOLOGY  
(RE) RETINA AND VITREOUS  
(RS) REFRACTIVE SURGERY  
(RX) REFRACTION-CONTACT LENSES  
(ST) STRABISMUS  
(TR) TRAUMA  
(TU) TUMORS AND PATHOLOGY  
(UV) UVEITIS  
(US) OCULAR ULTRASOUND

Deadline: 10/2019

### FORMAT:

#### Abstract should contain:

Title  
Author  
Co-authors (maximum 6)  
Purpose  
Methods  
Results  
Conclusion  
Keywords

Poster guidelines:  
**90cm x 120cm**

### FIRST (PRESENTING) AUTHOR (REQUIRED):

**Name:** Rodolfo Peres Nunes - Fellow  
**e-mail:** rodolfonunesdr@outlook.com  
**CEP Number:** 0

### 5. ABSTRACT (REQUIRED):

**Title: Intracorneal Ring Segment: Comparison between experts and software in surgical planning at an University Hospital.**

**Author and Co-authors:** Rodolfo Peres Nunes, Luciene Barbosa de Sousa

**Purpose:** The Intracorneal ring segment was started to use for correction of Keratoconus and Ectasias after refractive surgery. The FDA regulated the device in 1999 for correction of myopia between -1.0 and -3.0 D. The gains of the Intracorneal ring segment implant are: flattening of the cornea, changing the apex of the cornea to the center, preserving the asphericity and decreasing the irregularity of corneal surface. Technically it presents advantage of being removable, the surgical process does not affect visual axis and it's stable. Intracorneal ring segment manufacturers generally suggest nomograms for implantation of rings. Although these nomograms provided parameters such as: diameter of the ring (optical zone), depth to be implanted and number of segments vary according to surgeon's experience, in addition to emyrisms employed by surgeons, decreasing the reproducibility and predictability of the procedure.

**Methods:** A prospective, randomized, masked study in patients with keratoconus diagnosis and indication of intracorneal ring segment implant, who will undergo the surgical procedure in the Department of External Ocular and corneal diseases of UNIFESP in the year of 2019. The data of dynamic refraction, visual acuity, pupillary diameter, anterior elevation map, asphericity, posterior elevation map and pakimtric map will be provided, to suggest the ring segments to be used in surgical planning of two groups: 1. Group 1 and Group 2: Planning will be done by two ophthalmologists with more than 3 years of experience with ring segment implant. 2. Group 3: Using Keraring® app with Nomogram 2018 ? Keraring (app available on the Android and IOS platform). Those 90 patients will be randomized into 3 groups of 30 people to do surgery, using block randomization. After that its going to be compared the data of corneal depth data of implant, number of ring segments that are going to be implanted, arc degrees of the implanted device, ring thickness and corneal incision region for the implant, Visual acuity with and without Correction and topographic data. Changes in uncorrected distance visual acuity, corrected distance visual acuity, refractive errors, keratometry readings, measured with corneal tomography will be evaluated retrospectively. The uncorrected distance visual acuity and corrected distance visual acuity will be used as primary outcome and the others parameters as secondary outcome

**Results:** To determine the improvement of Visual acuity with correction, comparing the results of surgical schedule between those three groups, Compare the schedules of different groups and refractive and topographic results.

**Conclusion:** In progress

**Keywords:** cornea ectasia; intracorneal ring segments; keratoconus;

## 2019 Research Days Abstract Form

### 2. SCIENTIFIC SECTION PREFERENCE (REQUIRED):

Review the Scientific Section Descriptions. Select and enter the two-letter Code for the one (1) Section best suited to review your abstract.

**(CO) CORNEA AND EXTERNAL DISEASE**

### 3. PRESENTATION PREFERENCE (REQUIRED)

Check one:

**(CO) CORNEA AND EXTERNAL DISEASE**

4. The signature of the First (Presenting) Author (REQUIRED) acting as the authorized agent for all authors, hereby certifies that any research reported was conducted in compliance with the Declaration of Helsinki and the "UNIFESP Ethical Committee"

Scientific Section Descriptions (two-letter code):

(BE) OCULAR BIOENGINEERING  
(CO) CORNEA AND EXTERNAL DISEASE  
(CA) CATARACT  
(EF) ELECTROPHYSIOLOGY  
(EP) EPIDEMIOLOGY  
(EX) EXPERIMENTAL SURGERY  
(GL) GLAUCOMA  
(LA) LABORATORY  
(LS) LACRIMAL SYSTEM  
(LV) LOW VISION  
(NO) NEURO-OPHTHALMOLOGY  
(OR) ORBIT  
(PL) OCULAR PLASTIC SURGERY  
(PH) PHARMACOLOGY  
(RE) RETINA AND VITREOUS  
(RS) REFRACTIVE SURGERY  
(RX) REFRACTION-CONTACT LENSES  
(ST) STRABISMUS  
(TR) TRAUMA  
(TU) TUMORS AND PATHOLOGY  
(UV) UVEITIS  
(US) OCULAR ULTRASOUND

Deadline: 10/2019

### FORMAT:

#### Abstract should contain:

Title  
Author  
Co-authors (maximum 6)  
Purpose  
Methods  
Results  
Conclusion  
Keywords

Poster guidelines:  
**90cm x 120cm**

### FIRST (PRESENTING) AUTHOR (REQUIRED):

**Name:** Vanessa Favero Demeda - R4  
**e-mail:** vanessa.favero@gmail.com  
**CEP Number:** 0

### 5. ABSTRACT (REQUIRED):

**Title: Corneal Transplantation in a referral cornea center in Brazil: epidemiology, surgical techniques and outcomes.**

**Author and Co-authors:** Vanessa Favero Demeda, Lauro Augusto de Oliveira.

**Purpose:** This study aims to analyze corneal transplantation data from surgeries performed at the Department of Ophthalmology ? UNIFESP. And subsequently create a database that allows analysis and characterization of the corneal transplantation scenario in this institution.

**Methods:** Retrospective data collection from medical records of all patients who received corneal transplantation from January 1st to December 31st of 2018. We will subsequently create a database to to prospectively analyze corneal transplantation results and trends in our institution. Data extracted for analysis will include : patient demographics (age, sex), preoperative diagnosis and indication for corneal transplantation, surgical technique, ocular history (history of trauma, glaucoma, retinopathy), preoperative and postoperative best corrected visual acuity, rejection and adverse reactions.

**Results:** this project is under the Ethics Committee appreciation. So far, data collection did not start and we still don?t have results.

**Conclusion:** this project is under the Ethics Committee appreciation. So far, data collection did not start and we still don?t have results.

**Keywords:** corneal transplantation, surgical technique, adverse events, rejection, visual acuity



## 2019 Research Days Abstract Form

### 2. SCIENTIFIC SECTION PREFERENCE (REQUIRED):

Review the Scientific Section Descriptions. Select and enter the two-letter Code for the one (1) Section best suited to review your abstract.

**(CO) CORNEA AND EXTERNAL DISEASE**

### 3. PRESENTATION PREFERENCE (REQUIRED)

Check one:

**(CO) CORNEA AND EXTERNAL DISEASE**

4. The signature of the First (Presenting) Author (REQUIRED) acting as the authorized agent for all authors, hereby certifies that any research reported was conducted in compliance with the Declaration of Helsinki and the "UNIFESP Ethical Committee"

### Scientific Section Descriptions (two-letter code):

(BE) OCULAR BIOENGINEERING  
(CO) CORNEA AND EXTERNAL DISEASE  
(CA) CATARACT  
(EF) ELECTROPHYSIOLOGY  
(EP) EPIDEMIOLOGY  
(EX) EXPERIMENTAL SURGERY  
(GL) GLAUCOMA  
(LA) LABORATORY  
(LS) LACRIMAL SYSTEM  
(LV) LOW VISION  
(NO) NEURO-OPHTHALMOLOGY  
(OR) ORBIT  
(PL) OCULAR PLASTIC SURGERY  
(PH) PHARMACOLOGY  
(RE) RETINA AND VITREOUS  
(RS) REFRACTIVE SURGERY  
(RX) REFRACTION-CONTACT LENSES  
(ST) STRABISMUS  
(TR) TRAUMA  
(TU) TUMORS AND PATHOLOGY  
(UV) UVEITIS  
(US) OCULAR ULTRASOUND

Deadline: 10/2019

### FORMAT:

#### Abstract should contain:

Title  
Author  
Co-authors (maximum 6)  
Purpose  
Methods  
Results  
Conclusion  
Keywords

Poster guidelines:  
**90cm x 120cm**

### FIRST (PRESENTING) AUTHOR (REQUIRED):

**Name:** Wirley Alves Mendonca Junior - Fellow  
**e-mail:** wirley04@hotmail.com  
**CEP Number:** 1.423.852

### 5. ABSTRACT (REQUIRED):

#### **Title: Evaluation of Rose Bengal Mediated Photodynamic Therapy for inhibition of bacterial and fungal keratitis isolates**

**Author and Co-authors:** Wirley Alves de Mendonca Júnior, Talita Trevizani Rocchetti, Vitória de Souza Rocha Jackeline Stefani de Oliveira Cardoso, Gabrielle Macena Dias dos Reis, Ana Luisa Hofling-Lima

**Purpose:** To evaluate the in vitro efficacy of rose bengal mediated photodynamic therapy for inhibition of Staphylococcus aureus, Fusarium solani, Purpureocillium lilacinum and Pseudomonas aeruginosa clinical isolates.

**Methods:** Four clinical isolates Staphylococcus aureus, Fusarium solani, Purpureocillium lilacinum and Pseudomonas aeruginosa, recovered from patients with confirmed keratitis were used in the experiments. Bacterial isolates (Pseudomonas aeruginosa and Staphylococcus aureus) were grown on nutrient agar at 37°C for 1 day, prepared in suspension and adjusted to concentrations of 1,5x10<sup>8</sup> CFU/mL using a spectrophotometer. Fungal isolates (Purpureocillium lilacinum and Fusarium solani) were grown on Sabouraud agar at 30°C for 3 days, prepared in suspension and adjusted to concentrations using a Neubauer chamber. Tested in triplicate, groups included: Group I, control, Group II, microorganism suspension treated with 0,1% rose bengal and exposed to the dark for 30min, Group III, microorganism suspension treated with 0,1% rose bengal and exposed to green light LED (7,15 mW) for 30min. Final work concentration was 1.5 X 10<sup>4</sup> CFU/mL for bacteria, 3,92 x 10<sup>4</sup> CFU/mL for Fusarium solani and 3,85 x 10<sup>4</sup> CFU/mL for Purpureocillium lilacinum CFU/mL. Plates were incubated at specific conditions and photographed after 72 hours.

**Results:** Complete growth inhibition of Staphylococcus aureus, Fusarium solani, Purpureocillium lilacinum and Pseudomonas aeruginosa was demonstrated with 0,1% rose bengal under green LED irradiation for 30minutes. Staphylococcus aureus treated with 0,1% rose bengal and exposed to the dark also showed complete growth inhibition.

**Conclusion:** Rose bengal mediated therapy demonstrated complete growth inhibition in vitro of Fusarium solani, Purpureocillium lilacinum, Staphylococcus aureus and Pseudomonas aeruginosa. Rose bengal alone under dark was also effective for Staphylococcus aureus. These results may have in vivo implications.

**Keywords:** rose bengal, photodynamic therapy, keratitis

## 2019 Research Days Abstract Form

### 2. SCIENTIFIC SECTION PREFERENCE (REQUIRED):

Review the Scientific Section Descriptions. Select and enter the two-letter Code for the one (1) Section best suited to review your abstract.

**(CA) CATARACT**

### 3. PRESENTATION PREFERENCE (REQUIRED)

Check one:

**(CA) CATARACT**

4. The signature of the First (Presenting) Author (REQUIRED) acting as the authorized agent for all authors, hereby certifies that any research reported was conducted in compliance with the Declaration of Helsinki and the "UNIFESP Ethical Committee"

### Scientific Section Descriptions (two-letter code):

(BE) OCULAR BIOENGINEERING  
(CO) CORNEA AND EXTERNAL DISEASE  
(CA) CATARACT  
(EF) ELECTROPHYSIOLOGY  
(EP) EPIDEMIOLOGY  
(EX) EXPERIMENTAL SURGERY  
(GL) GLAUCOMA  
(LA) LABORATORY  
(LS) LACRIMAL SYSTEM  
(LV) LOW VISION  
(NO) NEURO-OPHTHALMOLOGY  
(OR) ORBIT  
(PL) OCULAR PLASTIC SURGERY  
(PH) PHARMACOLOGY  
(RE) RETINA AND VITREOUS  
(RS) REFRACTIVE SURGERY  
(RX) REFRACTION-CONTACT LENSES  
(ST) STRABISMUS  
(TR) TRAUMA  
(TU) TUMORS AND PATHOLOGY  
(UV) UVEITIS  
(US) OCULAR ULTRASOUND

Deadline: 10/2019

### FORMAT:

#### Abstract should contain:

Title  
Author  
Co-authors (maximum 6)  
Purpose  
Methods  
Results  
Conclusion  
Keywords

Poster guidelines:  
**90cm x 120cm**

### FIRST (PRESENTING) AUTHOR (REQUIRED):

**Name:** Allyne Mota Kalaf - R3  
**e-mail:** allykalaf@gmail.com  
**CEP Number:** 2.035.626

### 5. ABSTRACT (REQUIRED):

**Title: Comparative analysis on intraoperative complications in the 40th first phacoemulsification surgeries among second year residents with and without dry-lab experience**

**Author and Co-authors:** Kalaf, Allyne M., Vieira, IV., Coisa, BM., Sakaya, BN., Soares, LVB., Chamon, W.

**Purpose:** Phacoemulsification is the most performed surgical procedure in the world. Considering its learning curve most teaching institutions demand wetlab training before allowing training surgeons to perform procedures in patients. Classically these surgeons are subjected to animal model training with slaughter house porcine eyes. However, despite their similarity to the human eye, they do not provide a perfect platform for learning. In recent times, virtual reality has been used to assist phacoemulsification training in a model called dry-lab. Among the currently available models, EyeSi® (Vrmagic®, Mannheim, Germany) has demonstrated to improve surgical skills and to reduce learning curve. Considering that dry-lab training became obligatory since 2017 for first year residents in Unifesp we decided to perform a retrospective study comparing intraoperative complications among residents with and without dry-lab training in the first 40 surgeries.

**Methods:** This is a cross sectional study. Intraoperative complications data was collected from surgeries performed in Unifesp by second year residents of 2017 (without Eyesi® training) and 2018 (with Eyesi® training). Surgery complications were divided based on anatomy/surgical step as follows: incision, anterior capsule, posterior capsule, capsular bag (disinsertion), Descemet's membrane (detachment).

**Results:** Data from 20 first phacoemulsification surgeries of both second years residents (without and with training) was collected in a total of 240 surgeries. Complication rate for residents without and with dry-lab training were respectively: 05 (4.16%) vs 06 (5.0%) tunalized/short incisions, 07 (5.83%) vs 10 (8.33%) decentered capsulorrhexis, 11 (9.16%) vs 09 (7.5%) posterior capsular rupture, 02 (1.66%) vs 0 bag disinsertion, 04 (3.33%) vs 0 Descemet membrane detachments. Surgeons with dry-lab training also had less total complication when compared with surgeons without it: 25 vs 29 complications (p=0.1610), mainly due to small sample size. Comparing groups with a bigger N, in this study, 40 each resident, totalizing 480 surgeries, a significantly statistical difference is expected to demonstrate the beneficial factor on reducing intraoperative complications.

**Conclusion:** Its yet to be analyzed and concluded.

**Keywords:** eyesi simulator

## 2019 Research Days Abstract Form

### 2. SCIENTIFIC SECTION PREFERENCE (REQUIRED):

Review the Scientific Section Descriptions. Select and enter the two-letter Code for the one (1) Section best suited to review your abstract.

**(CA) CATARACT**

### 3. PRESENTATION PREFERENCE (REQUIRED)

Check one:

**(CA) CATARACT**

4. The signature of the First (Presenting) Author (REQUIRED) acting as the authorized agent for all authors, hereby certifies that any research reported was conducted in compliance with the Declaration of Helsinki and the "UNIFESP Ethical Committee"

### Scientific Section Descriptions (two-letter code):

(BE) OCULAR BIOENGINEERING  
(CO) CORNEA AND EXTERNAL DISEASE  
(CA) CATARACT  
(EF) ELECTROPHYSIOLOGY  
(EP) EPIDEMIOLOGY  
(EX) EXPERIMENTAL SURGERY  
(GL) GLAUCOMA  
(LA) LABORATORY  
(LS) LACRIMAL SYSTEM  
(LV) LOW VISION  
(NO) NEURO-OPHTHALMOLOGY  
(OR) ORBIT  
(PL) OCULAR PLASTIC SURGERY  
(PH) PHARMACOLOGY  
(RE) RETINA AND VITREOUS  
(RS) REFRACTIVE SURGERY  
(RX) REFRACTION-CONTACT LENSES  
(ST) STRABISMUS  
(TR) TRAUMA  
(TU) TUMORS AND PATHOLOGY  
(UV) UVEITIS  
(US) OCULAR ULTRASOUND

Deadline: 10/2019

### FORMAT:

#### Abstract should contain:

Title  
Author  
Co-authors (maximum 6)  
Purpose  
Methods  
Results  
Conclusion  
Keywords

Poster guidelines:  
**90cm x 120cm**

### FIRST (PRESENTING) AUTHOR (REQUIRED):

**Name:** Jorge Selem Haddad Neto - PG1 - DO  
**e-mail:** jshaddad2@hotmail.com  
**CEP Number:** 10.222.018

### 5. ABSTRACT (REQUIRED):

#### **Title: Comparison of ray-tracing, Hartmann-Shack, autorefractometry and manifest refraction in echelette?s achromatic intraocular lens**

**Author and Co-authors:** Jorge Selem Haddad MD, Larissa Gouvea MD, Joseana Lopes Ferreira MD, Renato Ambrosio Jr. MD, PhD, George Oral Waring IV MD, FACS, Karolinne Maia Rocha MD, PhD.

**Purpose:** To compare ray-tracing, Hartmann-Shack, autorefractometry (AR), and manifest refraction (MRSE) in patients implanted with echelette diffractive intraocular lens (IOL) and a monofocal IOL with negative spherical aberration.

**Methods:** Eyes implanted with an echelette diffractive IOL (SymfonyTM, Johnson&Johnson Vision) and control eyes implanted with a negative spherical aberration monofocal IOL (Tecnis® ZCBOO, Johnson&Johnson Vision) were included in the study. Ray-tracing aberrometry (iTrace Tracey Technologies Corp.), Hartmann-Shack (LadarWave, Alcon Laboratories, Inc.), AR (Topcon KR-8800, Topcon Medical Systems, Inc.) and MRSE were performed 1-3 months postoperatively.

**Results:** Thirty-two eyes implanted with a SymfonyTM IOL and 24 controls implanted with a Tecnis® ZCBOO were enrolled in the study. The SymfonyTM IOL group yield more negative results in ray-tracing aberrometry ( $-0.62 \pm 0.41$  D), Hartmann-Shack wavefront analysis ( $-0.84 \pm 0.40$  D) and AR ( $-0.45 \pm 0.64$  D), compared to MRSE ( $-0.12 \pm 0.44$  D,  $p < 0.001$ ). Hartmann-Shack wavefront analysis showed a statistically significant negative result ( $-0.45 \pm 0.46$ SD) in the ZCBOO group compared to ray-tracing aberrometry, AR and MRSE ( $-0.20 \pm 0.55$ SD,  $-0.22 \pm 0.51$ D,  $-0.15 \pm 0.43$ D, respectively,  $p < 0.001$ ).

**Conclusion:** Manifest refraction techniques unique to echelette technology should be utilized to avoid over-minus end points. Autorefractors and aberrometers commonly use near-infrared light, thus we expect myopic results with echelette?s achromatic technology.

**Keywords:** Cataract, Intraocular Lens, Refraction

## 2019 Research Days Abstract Form

### 2. SCIENTIFIC SECTION PREFERENCE (REQUIRED):

Review the Scientific Section Descriptions. Select and enter the two-letter Code for the one (1) Section best suited to review your abstract.

**(CA) CATARACT**

### 3. PRESENTATION PREFERENCE (REQUIRED)

Check one:

**(CA) CATARACT**

4. The signature of the First (Presenting) Author (REQUIRED) acting as the authorized agent for all authors, hereby certifies that any research reported was conducted in compliance with the Declaration of Helsinki and the "UNIFESP Ethical Committee"

### Scientific Section Descriptions (two-letter code):

(BE) OCULAR BIOENGINEERING  
(CO) CORNEA AND EXTERNAL DISEASE  
(CA) CATARACT  
(EF) ELECTROPHYSIOLOGY  
(EP) EPIDEMIOLOGY  
(EX) EXPERIMENTAL SURGERY  
(GL) GLAUCOMA  
(LA) LABORATORY  
(LS) LACRIMAL SYSTEM  
(LV) LOW VISION  
(NO) NEURO-OPHTHALMOLOGY  
(OR) ORBIT  
(PL) OCULAR PLASTIC SURGERY  
(PH) PHARMACOLOGY  
(RE) RETINA AND VITREOUS  
(RS) REFRACTIVE SURGERY  
(RX) REFRACTION-CONTACT LENSES  
(ST) STRABISMUS  
(TR) TRAUMA  
(TU) TUMORS AND PATHOLOGY  
(UV) UVEITIS  
(US) OCULAR ULTRASOUND

Deadline: 10/2019

### FORMAT:

**Abstract should contain:**

Title  
Author  
Co-authors (maximum 6)  
Purpose  
Methods  
Results  
Conclusion  
Keywords

Poster guidelines:  
**90cm x 120cm**

### FIRST (PRESENTING) AUTHOR (REQUIRED):

**Name:** Victoria Sakamoto - R1  
**e-mail:** victoria.ksakamoto@gmail.com  
**CEP Number:** 659237175

### 5. ABSTRACT (REQUIRED):

**Title: To evaluate the application of the red reflex test in newborns treated at the Congenital Cataract Outpatient Clinic of the Federal University of São Paulo**

**Author and Co-authors:** Author: Victória Sakamoto, Co-authors: Dra Ana Paula Silvério Rodrigues, Dra Denise de Freitas

**Purpose:** Congenital cataract is a lens opacity presented at birth or developed until 3 months old that can lead to total or partial blindness if not diagnosed or treated early. It is considered one of the main preventable causes of childhood blindness, being responsible for 14% of blind children worldwide. The prevalence varies from 5 to 15 per 10,000 live births in developing countries. Despite its importance, there are few statistics on the subject in Brazil. The Red Reflex Test (RRT) is an essential component of the physical examination of newborns and children, as it can early detect anomalies that may compromise the vision development, such as congenital cataract. This screening eye evaluation is done in many maternity hospitals worldwide and in some Brazilian states it is mandatory to perform the RRT. This study objective is to evaluate the performance of mandatory visual screening in children treated at the sector of Congenital Cataract of the Department of Ophthalmology and Visual Sciences of Federal University of São Paulo and to verify if different types of congenital cataract can falsify the RRT.

**Methods:** It was done the systematic analysis of the medical records of all children from 0 to 1 year old referred to the Congenital Cataract Outpatient Clinic of Federal University of São Paulo, with the diagnosis or suspicion of congenital cataract and that later underwent lensectomy surgery in our facility. The study was conducted between February 2012 and July 2019. The following information were collected: demographic data, gestational age at birth, home address, hospital of birth, RRT, who noticed the ocular change, systemic diseases, cataract classification and past family history of the pathology. The RRT was analyzed for its execution and written report in the referral. All patients underwent a new RRT and a complete eye examination.

**Results:** In progress

**Conclusion:** In progress

**Keywords:** Congenital cataract, Red Reflex Test, newborn

## 2019 Research Days Abstract Form

### 2. SCIENTIFIC SECTION PREFERENCE (REQUIRED):

Review the Scientific Section Descriptions. Select and enter the two-letter Code for the one (1) Section best suited to review your abstract.

**(RX) REFRACTION-CONTACT LENSES**

### 3. PRESENTATION PREFERENCE (REQUIRED)

Check one:

**(RX) REFRACTION-CONTACT LENSES**

4. The signature of the First (Presenting) Author (REQUIRED) acting as the authorized agent for all authors, hereby certifies that any research reported was conducted in compliance with the Declaration of Helsinki and the "UNIFESP Ethical Committee"

### Scientific Section Descriptions (two-letter code):

(BE) OCULAR BIOENGINEERING  
(CO) CORNEA AND EXTERNAL DISEASE  
(CA) CATARACT  
(EF) ELECTROPHYSIOLOGY  
(EP) EPIDEMIOLOGY  
(EX) EXPERIMENTAL SURGERY  
(GL) GLAUCOMA  
(LA) LABORATORY  
(LS) LACRIMAL SYSTEM  
(LV) LOW VISION  
(NO) NEURO-OPHTHALMOLOGY  
(OR) ORBIT  
(PL) OCULAR PLASTIC SURGERY  
(PH) PHARMACOLOGY  
(RE) RETINA AND VITREOUS  
(RS) REFRACTIVE SURGERY  
(RX) REFRACTION-CONTACT LENSES  
(ST) STRABISMUS  
(TR) TRAUMA  
(TU) TUMORS AND PATHOLOGY  
(UV) UVEITIS  
(US) OCULAR ULTRASOUND

Deadline: 10/2019

### FORMAT:

#### Abstract should contain:

Title  
Author  
Co-authors (maximum 6)  
Purpose  
Methods  
Results  
Conclusion  
Keywords

Poster guidelines:  
**90cm x 120cm**

### FIRST (PRESENTING) AUTHOR (REQUIRED):

**Name:** Cristina Cagliari - PG0 - DO  
**e-mail:** cagliari.c@gmail.com  
**CEP Number:** 1330/2016

### 5. ABSTRACT (REQUIRED):

#### Title: A Critical Analysis Regarding Scleral Contact Lenses Adaptation

**Author and Co-authors:** Cristina Cagliari, MD. Luiz Formentin, MD. Larissa Azevedo, MD. Paulo Roberto Gonçalves Amorim, MD. Juliana Rosa, MD. Marcelo Kenji Shigetomi, MD. Ulysses Tachibana, MD.

**Purpose:** The target of this study is to evaluate the interaction between the ocular superficial anatomy and the scleral contact lens, estimating the time needed to its stability during fitting.

**Methods:** A prospective and observational clinical study was conducted with 8 patients, including a total of 12 eyes. All participants belong to the ambulatory of Refraction and Contact Lenses of the Ophthalmology Department of Paulista School of Medicine and had a prior diagnosis of Ectatic Corneal Disease. In a period of 4 hours, we observed the performance of Boston XO® Dk 100 SCLs based on the following parameters: anterior biomicroscopy, visual accuracy and refraction, topography (with and without lenses) and optic coherence tomography images.

**Results:** The mean variation of the topography above the SCL was 0.03D (-1.05 to 1.3), topographic astigmatism above the lenses resulted in a mean of 0.283D (0 to 1.0). The visual accuracy variation was 0.01 (0 to 0.2) and the mean variation of the overrefraction resulted in 0.007D (0 to 0.75). After about 2 hours, the central vault reduction was 96.29% of the total settling of 4 hours, that was 62.5 µm. In the periphery with the more elevated vault, by this time we had 78.33% of a total of 79.16 µm and in the periphery of minor elevation, 43,75% of a total of 25 µm. We also analyzed the support of the lenses on the sclera by grading from 0 to 3 being 3 strong compressions (obstructing the circulation), 0 without any compression and a negative number indicating peripheral elevation. Therefore after the 4 hours, we had the following means: 0.25 in the nasal region, 0 in the temporal region, -0.333 in the superior region and -0.083 in inferior region. These numbers remained stable during all the period of the study. Many lenses included in this study already had toric adjustment and that explains the low numbers of compression and elevation. Of the tested lenses, 58.33% had peripheral toric adjusted.

**Conclusion:** We conclude with this study that there are some important points we believe are essential to the ideal SCL customization: 1- the first 120 minutes are the most important to clarify the true scleral-lens vault and in order to choose a more reliable final SAG, 2- the graduation proposed in our study could lead to a better peripheral adjustment, 3- the Boston XO® Dk 100 SCLs showed a good structural stability over the hours which showed visual constant acuity and refractometry.

**Keywords:** cornea, contact lens, scleral contact lens, corneal ectatic disease

## 2019 Research Days Abstract Form

### 2. SCIENTIFIC SECTION PREFERENCE (REQUIRED):

Review the Scientific Section Descriptions. Select and enter the two-letter Code for the one (1) Section best suited to review your abstract.

**(TR) TRAUMA**

### 3. PRESENTATION PREFERENCE (REQUIRED)

Check one:

**(TR) TRAUMA**

4. The signature of the First (Presenting) Author (REQUIRED) acting as the authorized agent for all authors, hereby certifies that any research reported was conducted in compliance with the Declaration of Helsinki and the "UNIFESP Ethical Committee"

### Scientific Section Descriptions (two-letter code):

(BE) OCULAR BIOENGINEERING  
(CO) CORNEA AND EXTERNAL DISEASE  
(CA) CATARACT  
(EF) ELECTROPHYSIOLOGY  
(EP) EPIDEMIOLOGY  
(EX) EXPERIMENTAL SURGERY  
(GL) GLAUCOMA  
(LA) LABORATORY  
(LS) LACRIMAL SYSTEM  
(LV) LOW VISION  
(NO) NEURO-OPHTHALMOLOGY  
(OR) ORBIT  
(PL) OCULAR PLASTIC SURGERY  
(PH) PHARMACOLOGY  
(RE) RETINA AND VITREOUS  
(RS) REFRACTIVE SURGERY  
(RX) REFRACTION-CONTACT LENSES  
(ST) STRABISMUS  
(TR) TRAUMA  
(TU) TUMORS AND PATHOLOGY  
(UV) UVEITIS  
(US) OCULAR ULTRASOUND

Deadline: 10/2019

### FORMAT:

#### Abstract should contain:

Title  
Author  
Co-authors (maximum 6)  
Purpose  
Methods  
Results  
Conclusion  
Keywords

Poster guidelines:  
**90cm x 120cm**

### FIRST (PRESENTING) AUTHOR (REQUIRED):

**Name:** Camila Kase - R2  
**e-mail:** camila.kase@gmail.com  
**CEP Number:** 1271/2018

### 5. ABSTRACT (REQUIRED):

**Title: Epidemiology of Evisceration and Enucleation cases in an ophthalmological emergency room sector of a tertiary brazilian hospital: a 7-year analysis**

**Author and Co-authors:** Camila Kase, Luis Filipe Nakayama, Vinicius Campos Bergamo, Nilva Simeren Bueno de Moraes

**Purpose:** To analyze the epidemiological profile of patients that underwent evisceration or enucleation at the ophthalmology emergency room sector of a brazilian tertiary hospital in the last 7 years.

**Methods:** This study was a retrospective analysis of the cases treated in the Ophthalmology Emergency Room of the Hospital Sao Paulo (Federal University of Sao Paulo) - between the years of 2012 to 2018. We included the emergency cases of evisceration or enucleation and excluded the elective cases. We analyzed demographic data, immediate cause of the procedure, associated causes, informed visual acuity, time of onset symptoms until search for medical care, distance from the residence to the tertiary hospital and time of hospitalization.

**Results:** In our service, 73 enucleations (40 men and 33 women) and 120 eviscerations (60 men and 60 women) were performed. The mean age was 63.36 years (0-95). The causes were: perforated corneal ulcer (32.2%), painful blind eye (24.8%), ocular trauma (23.5%), endophthalmitis (16.7%), intraocular neoplasia (2.0%) and phthisis (0.6%). The reported visual acuity was absence of light perception (91.2%), light perception (5.3%), hand motion (1.3%) and non-informant (2.0%). The mean time taken to seek ophthalmologic care was 10 days (1 - 150), the mean distance between home and unit care was 24.3 kilometers (2.2 - 653) and the mean length of hospital stay was 3 days (0-41).

**Conclusion:** Ocular enucleation and evisceration are procedures reserved for cases without visual prognosis. Our study is the first to analyze epidemiological data on ocular enucleation and evisceration in an ophthalmologic emergency service of a Brazilian tertiary hospital. The main causes were corneal involvement, painful blind eyes, ocular trauma and endophthalmitis. This study guides possible preventive measures for the main indications of evisceration and enucleation and the reserved prognosis in advanced cases of such ocular pathologies.

**Keywords:** Evisceration, Enucleation, Emergency, Trauma, Epidemiology

## 2019 Research Days Abstract Form

### 2. SCIENTIFIC SECTION PREFERENCE (REQUIRED):

Review the Scientific Section Descriptions. Select and enter the two-letter Code for the one (1) Section best suited to review your abstract.

**(TR) TRAUMA**

### 3. PRESENTATION PREFERENCE (REQUIRED)

Check one:

**(TR) TRAUMA**

4. The signature of the First (Presenting) Author (REQUIRED) acting as the authorized agent for all authors, hereby certifies that any research reported was conducted in compliance with the Declaration of Helsinki and the 'UNIFESP Ethical Committee'

### Scientific Section Descriptions (two-letter code):

(BE) OCULAR BIOENGINEERING  
(CO) CORNEA AND EXTERNAL DISEASE  
(CA) CATARACT  
(EF) ELECTROPHYSIOLOGY  
(EP) EPIDEMIOLOGY  
(EX) EXPERIMENTAL SURGERY  
(GL) GLAUCOMA  
(LA) LABORATORY  
(LS) LACRIMAL SYSTEM  
(LV) LOW VISION  
(NO) NEURO-OPHTHALMOLOGY  
(OR) ORBIT  
(PL) OCULAR PLASTIC SURGERY  
(PH) PHARMACOLOGY  
(RE) RETINA AND VITREOUS  
(RS) REFRACTIVE SURGERY  
(RX) REFRACTION-CONTACT LENSES  
(ST) STRABISMUS  
(TR) TRAUMA  
(TU) TUMORS AND PATHOLOGY  
(UV) UVEITIS  
(US) OCULAR ULTRASOUND

Deadline: 10/2019

### FORMAT:

#### Abstract should contain:

Title  
Author  
Co-authors (maximum 6)  
Purpose  
Methods  
Results  
Conclusion  
Keywords

Poster guidelines:  
**90cm x 120cm**

### FIRST (PRESENTING) AUTHOR (REQUIRED):

**Name:** Lucas Denadai - R2  
**e-mail:** lucasdenadai89@hotmail.com  
**CEP Number:** 1271/2018

### 5. ABSTRACT (REQUIRED):

**Title: Epidemiological characteristics and visual outcome of patients hospitalized for Open-Globe injury in a Tertiary Hospital in Brazil**

**Author and Co-authors:** Denadai L, Bergamo VC, Nakayama LF

**Purpose:** This study aimed at providing epidemiological characteristics and visual outcome of patients hospitalized for open-globe injury in a tertiary hospital in Brazil, based on retrospectively analyses of hospital records.

**Methods:** The study included all patients with open-globe injury at the Department of Ophthalmology of Federal University of São Paulo, Brazil, over a 6 year period from May 2011 through August 2017. This is a retrospective study involving a chart review of all cases of open-globe trauma. Patients' information from a computerized records system at the hospital were retrieved and analyzed.

**Results:** In total, 467 patients with open-globe injury had been admitted to our service between May of 2011 to August of 2017. Of these patients, 77,52% (362 cases) were males and 22,48% (105 cases) were females. Patients' ages ranged from 8 months to 93 years old.

**Conclusion:** Preventable in the majority of cases, eye trauma causes long-term disability, extreme psychological and emotional stress to victims, as well as an economic burden to society. Eye trauma present different epidemiological/public health patterns in relation to country-specific socioeconomic levels of development.

**Keywords:** Eye trauma; Open-globe; Epidemiology

## 2019 Research Days Abstract Form

### 2. SCIENTIFIC SECTION PREFERENCE (REQUIRED):

Review the Scientific Section Descriptions. Select and enter the two-letter Code for the one (1) Section best suited to review your abstract.

**(TU) TUMORS AND PATHOLOGY**

### 3. PRESENTATION PREFERENCE (REQUIRED)

Check one:

**(TU) TUMORS AND PATHOLOGY**

4. The signature of the First (Presenting) Author (REQUIRED) acting as the authorized agent for all authors, hereby certifies that any research reported was conducted in compliance with the Declaration of Helsinki and the "UNIFESP Ethical Committee"

### Scientific Section Descriptions (two-letter code):

(BE) OCULAR BIOENGINEERING  
(CO) CORNEA AND EXTERNAL DISEASE  
(CA) CATARACT  
(EF) ELECTROPHYSIOLOGY  
(EP) EPIDEMIOLOGY  
(EX) EXPERIMENTAL SURGERY  
(GL) GLAUCOMA  
(LA) LABORATORY  
(LS) LACRIMAL SYSTEM  
(LV) LOW VISION  
(NO) NEURO-OPHTHALMOLOGY  
(OR) ORBIT  
(PL) OCULAR PLASTIC SURGERY  
(PH) PHARMACOLOGY  
(RE) RETINA AND VITREOUS  
(RS) REFRACTIVE SURGERY  
(RX) REFRACTION-CONTACT LENSES  
(ST) STRABISMUS  
(TR) TRAUMA  
(TU) TUMORS AND PATHOLOGY  
(UV) UVEITIS  
(US) OCULAR ULTRASOUND

Deadline: 10/2019

### FORMAT:

#### Abstract should contain:

Title  
Author  
Co-authors (maximum 6)  
Purpose  
Methods  
Results  
Conclusion  
Keywords

Poster guidelines:  
**90cm x 120cm**

### FIRST (PRESENTING) AUTHOR (REQUIRED):

**Name:** Ana Marisa Pires Castelo Branco - Fellow  
**e-mail:** anamarisapcb@hotmail.com  
**CEP Number:** 0

### 5. ABSTRACT (REQUIRED):

**Title: Topical 5-fluorouracil 0,25% as treatment of Ocular Surface Squamous Neoplasia**

**Author and Co-authors:** Branco AMP, Belfort Neto R, Morales MC, Fernandes, A

**Purpose:** To evaluate the results and efficacy of 5-fluorouracil (5-FU) 0,25% for patients with lesions suspicious of ocular surface squamous neoplasia (OSSN).

**Methods:** Five patients with suspicious lesions of OSSN were selected based on clinical examination. Each patient underwent full ophthalmologic examination at baseline. Photograph, impression cytology (IC) and anterior segment optical coherence tomography (OCT) were done before treatment with 5-FU and after every cycle (consisted in 7 days using the drug and a pause of 14 days). If there was no response after 4 cycles, patients were forwarded to an excisional biopsy. Each patient signed an informed consent.

**Results:** Five patients that had a suspicious lesion were treated with 5-FU 0,25% four times a day. Photograph, IC and anterior segment OCT were done for comparison before and after treatment. Patients that were previously treated with mitomycin-C, 5-fluorouracil (any concentration), interferon alfa 2B or surgery were excluded. Four patients had an IC positive for squamous neoplasia with atipia and one patient had metaplasia with atipia. Mean follow-up was 2 months. No clinical tumor regression was achieved in 4 patients (80%) after 4 cycles and they underwent excisional biopsy. One patient (20%) had tumor regression after 3 cycles, observed on clinical examination and documented by photograph and segment anterior OCT. The patient was submitted to IC, which became negative for atipia. All patients remain in ophthalmologic care.

**Conclusion:** 5-FU 0,25% would be a useful form for OSSN treatment because of the side effects of the drug in higher concentrations, as hyperemia, keratitis and foreign body sensation. Short-term results of 5-FU 0,25% use as an alternative dose for OSSN treatment was unfavorable in 80% of cases which underwent excisional biopsy. One patient (20%) had a good response, with tumor regression. This rate suggests that OSSN response to topical 5-FU 0,25% may be insufficient to quell cell proliferation. Further studies should be conducted.

**Keywords:** Ocular Surface Squamous Neoplasia; Impression cytology; tumor; 5-fluorouracil;



## 2019 Research Days Abstract Form

### 2. SCIENTIFIC SECTION PREFERENCE (REQUIRED):

Review the Scientific Section Descriptions. Select and enter the two-letter Code for the one (1) Section best suited to review your abstract.

**(TU) TUMORS AND PATHOLOGY**

### 3. PRESENTATION PREFERENCE (REQUIRED)

Check one:

**(TU) TUMORS AND PATHOLOGY**

4. The signature of the First (Presenting) Author (REQUIRED) acting as the authorized agent for all authors, hereby certifies that any research reported was conducted in compliance with the Declaration of Helsinki and the "UNIFESP Ethical Committee"

### Scientific Section Descriptions (two-letter code):

(BE) OCULAR BIOENGINEERING  
(CO) CORNEA AND EXTERNAL DISEASE  
(CA) CATARACT  
(EF) ELECTROPHYSIOLOGY  
(EP) EPIDEMIOLOGY  
(EX) EXPERIMENTAL SURGERY  
(GL) GLAUCOMA  
(LA) LABORATORY  
(LS) LACRIMAL SYSTEM  
(LV) LOW VISION  
(NO) NEURO-OPHTHALMOLOGY  
(OR) ORBIT  
(PL) OCULAR PLASTIC SURGERY  
(PH) PHARMACOLOGY  
(RE) RETINA AND VITREOUS  
(RS) REFRACTIVE SURGERY  
(RX) REFRACTION-CONTACT LENSES  
(ST) STRABISMUS  
(TR) TRAUMA  
(TU) TUMORS AND PATHOLOGY  
(UV) UVEITIS  
(US) OCULAR ULTRASOUND

Deadline: 10/2019

### FORMAT:

#### Abstract should contain:

Title  
Author  
Co-authors (maximum 6)  
Purpose  
Methods  
Results  
Conclusion  
Keywords

Poster guidelines:  
**90cm x 120cm**

### FIRST (PRESENTING) AUTHOR (REQUIRED):

**Name:** Armando Coelho Brito - R1  
**e-mail:** armandocbrito@gmail.com  
**CEP Number:** 1525001

### 5. ABSTRACT (REQUIRED):

**Title:** **Mantle Cell Lymphoma and acute low visual acuity**

**Author and Co-authors:** Author and Co-authors: Armando Coelho Brito, Beatriz Nugent da Cunha, Leticia Rubman, Paulo Gois Manso.

**Purpose:** Purpose: To report an uncommon case of tumoral infiltration of the CNS (Mantle Cell Lymphoma) causing acute low visual acuity.

**Methods:** Methods: We report a case of Mantle Cell Lymphoma as a cause of acute low visual acuity.

**Results:** Results: Case report of a 74 year-old male patient evaluated in the ophthalmology emergency room sector of the São Paulo Hospital with ocular pain for 1 month and low visual acuity in both eyes in the last week. The patient referred pain on eye movements and mild headache 1 month ago. He was diagnosed with lymphoma 8 months ago ( Mantle Cell Lymphoma). He was treated with systemic and Intrathecal Chemotherapy for 4 months - last session 4 months ago. His vision in the right eye it was counting fingers at 1m and the left eye it was no light perception. For diagnoses was made a exams: Left Inguinal Lymphadenectomy confirmed the immunohistochemical profile: BCL-2 positive and Ki-67 positive. Blood analysis: Leucocytes/mm<sup>3</sup>: 8.300 - with 43,4% neutrophils and 46,5% of lymphocytes, Liquor analysis: Lymphocytes 69% Monocytes 27%. The conduct is to make a hospitalization and restarted chemotherapy (systemic and intrathecal) with response evaluation with Cerebral Spinal Fluid control. After 4 applications of intrathecal chemotherapy: Improvement of CSF parameters and Improvement of visual acuity: OD: Hands Motion OS: Light Perception. After the treatment patient unfortunately the patient got septic (pulmonary focus) and died a few days after (nadir of chemotherapy).

**Conclusion:** Conclusion: Mantle Cell Lymphoma is rarely seen causing acute low visual acuity. In general, this cancer is very aggressive and has a bad prognosis and a small chance of cure, usually with an average survival of 3-5 years.

**Keywords:** Keywords: non Hodgkin Lymphoma; Mantle Cell Lymphoma; acute low visual acuity; tumoral infiltration of the CNS

## 2019 Research Days Abstract Form

### 2. SCIENTIFIC SECTION PREFERENCE (REQUIRED):

Review the Scientific Section Descriptions. Select and enter the two-letter Code for the one (1) Section best suited to review your abstract.

**(TU) TUMORS AND PATHOLOGY**

### 3. PRESENTATION PREFERENCE (REQUIRED)

Check one:

**(TU) TUMORS AND PATHOLOGY**

4. The signature of the First (Presenting) Author (REQUIRED) acting as the authorized agent for all authors, hereby certifies that any research reported was conducted in compliance with the Declaration of Helsinki and the "UNIFESP Ethical Committee"

### Scientific Section Descriptions (two-letter code):

(BE) OCULAR BIOENGINEERING  
(CO) CORNEA AND EXTERNAL DISEASE  
(CA) CATARACT  
(EF) ELECTROPHYSIOLOGY  
(EP) EPIDEMIOLOGY  
(EX) EXPERIMENTAL SURGERY  
(GL) GLAUCOMA  
(LA) LABORATORY  
(LS) LACRIMAL SYSTEM  
(LV) LOW VISION  
(NO) NEURO-OPHTHALMOLOGY  
(OR) ORBIT  
(PL) OCULAR PLASTIC SURGERY  
(PH) PHARMACOLOGY  
(RE) RETINA AND VITREOUS  
(RS) REFRACTIVE SURGERY  
(RX) REFRACTION-CONTACT LENSES  
(ST) STRABISMUS  
(TR) TRAUMA  
(TU) TUMORS AND PATHOLOGY  
(UV) UVEITIS  
(US) OCULAR ULTRASOUND

Deadline: 10/2019

### FORMAT:

#### Abstract should contain:

Title  
Author  
Co-authors (maximum 6)  
Purpose  
Methods  
Results,  
Conclusion  
Keywords

Poster guidelines:  
**90cm x 120cm**

### FIRST (PRESENTING) AUTHOR (REQUIRED):

**Name:** Camila Palmeira Griz - Fellow  
**e-mail:** camilapalmeira@hotmail.com  
**CEP Number:** 4006051

### 5. ABSTRACT (REQUIRED):

**Title: Meibomian gland Alterations due to Topical treatment of Ocular Surface Squamous Neoplasia**

**Author and Co-authors:** camila palmeira melina morales Rubens Belfort neto Arthur Gustavo Fernandes

**Purpose:** To evaluate the frequency of Meibomian gland dysfunction in patients with past history of ocular surface squamous neoplasia (OSSN) treated with topical therapy at the oncology department of Hospital São Paulo

**Methods:** This will be a transversal study, where 20 patients with a past history of OSSN treated with topical chemotherapy ( mitomicyn or 5 fluoracil) or immunotherapy (interferon) will be submitted to a study of the Meibomian glands. The eye treated will be compare with the other eye at the same patient to evaluate if there is any damage of those structures.

**Results:** So far, only 4 patients were evaluated, those patients had no differences between both eyes that could suggest any gland damage due the drug used for the neoplasia treatment.

**Conclusion:** More patients are required for a more complete conclusion.

**Keywords:** OSSN; topical chemotherapy ; oncology

## 2019 Research Days Abstract Form

### 2. SCIENTIFIC SECTION PREFERENCE (REQUIRED):

Review the Scientific Section Descriptions. Select and enter the two-letter Code for the one (1) Section best suited to review your abstract.

**(EP) EPIDEMIOLOGY**

### 3. PRESENTATION PREFERENCE (REQUIRED)

Check one:

**(EP) EPIDEMIOLOGY**

4. The signature of the First (Presenting) Author (REQUIRED) acting as the authorized agent for all authors, hereby certifies that any research reported was conducted in compliance with the Declaration of Helsinki and the "UNIFESP Ethical Committee"

### Scientific Section Descriptions (two-letter code):

(BE) OCULAR BIOENGINEERING  
(CO) CORNEA AND EXTERNAL DISEASE  
(CA) CATARACT  
(EF) ELECTROPHYSIOLOGY  
(EP) EPIDEMIOLOGY  
(EX) EXPERIMENTAL SURGERY  
(GL) GLAUCOMA  
(LA) LABORATORY  
(LS) LACRIMAL SYSTEM  
(LV) LOW VISION  
(NO) NEURO-OPHTHALMOLOGY  
(OR) ORBIT  
(PL) OCULAR PLASTIC SURGERY  
(PH) PHARMACOLOGY  
(RE) RETINA AND VITREOUS  
(RS) REFRACTIVE SURGERY  
(RX) REFRACTION-CONTACT LENSES  
(ST) STRABISMUS  
(TR) TRAUMA  
(TU) TUMORS AND PATHOLOGY  
(UV) UVEITIS  
(US) OCULAR ULTRASOUND

Deadline: 10/2019

### FORMAT:

#### Abstract should contain:

Title  
Author  
Co-authors (maximum 6)  
Purpose  
Methods  
Results  
Conclusion  
Keywords

Poster guidelines:  
**90cm x 120cm**

### FIRST (PRESENTING) AUTHOR (REQUIRED):

**Name:** Lucas Zago Ribeiro - R2  
**e-mail:** lucaszagoribeiro@gmail.com  
**CEP Number:** 1271/2018

### 5. ABSTRACT (REQUIRED):

#### **Title: Epidemiology of Ophthalmic Emergency Visits in a Brazilian Tertiary Hospital from 2009 to 2019**

**Author and Co-authors:** Lucas Zago Ribeiro, Luis Filipe Nakayama, Nilva Simeren Bueno de Moraes

**Purpose:** Evaluate the demand and profile of all visits to the ophthalmic emergency department of a tertiary hospital in the city of São Paulo, Brazil during the last 10 years.

**Methods:** The data was collected from the hospital database of patients charts who presented to the "Hospital São Paulo" ophthalmic emergency department, a tertiary-care teaching hospital that belongs to Federal University of São Paulo, between January 2009 and May 2019. The following data was retrieved: patient age, gender, informed home zip code and ICD-10 (International Classification of Diseases) informed by the physician.

**Results:** From 2009 to May 2019, there were 592.055 visits to the ophthalmic emergency room corresponding to 311.217 (53%) of unique patients during the whole period of analysis. Male corresponded to 54.3% of patients. The mean age of patients was  $39.75 \pm 20.40$  years, between newborn and 112 years, and 12.34% over 65 years. The mean of visits per day was 157.43 patients per day, with the highest rate been the year of 2019, considering the five months of analysis, with a mean of 186.19 patients per day. Visits on Mondays corresponded to 18% of total, and Sundays to only 8%. The most frequents ICD-10 informed by the physician were acute conjunctivitis, blepharitis, keratitis, corneal foreign body, ocular trauma and subconjunctival hemorrhage.

**Conclusion:** The trends of the last 10 years show an progressive increase in ophthalmic emergency visits, that is probably associated with the reduction of access to 24 hour public ophthalmic emergency services in São Paulo and also due to the inappropriate use of emergency services with non-urgent conditions as a result of low understanding by the population and also because of the difficult for the patients to access ophthalmological services going to the primary health. Another aspect shown by the analysis of patient charts, was the amount of mistake or absence of information about patient correct diagnosis or complain.

**Keywords:** emergency, epidemiology, ophthalmology

## 2019 Research Days Abstract Form

### 2. SCIENTIFIC SECTION PREFERENCE (REQUIRED):

Review the Scientific Section Descriptions. Select and enter the two-letter Code for the one (1) Section best suited to review your abstract.

**(LS) LACRIMAL SYSTEM**

### 3. PRESENTATION PREFERENCE (REQUIRED)

Check one:

**(LS) LACRIMAL SYSTEM**

4. The signature of the First (Presenting) Author (REQUIRED) acting as the authorized agent for all authors, hereby certifies that any research reported was conducted in compliance with the Declaration of Helsinki and the "UNIFESP Ethical Committee"

### Scientific Section Descriptions (two-letter code):

(BE) OCULAR BIOENGINEERING  
(CO) CORNEA AND EXTERNAL DISEASE  
(CA) CATARACT  
(EF) ELECTROPHYSIOLOGY  
(EP) EPIDEMIOLOGY  
(EX) EXPERIMENTAL SURGERY  
(GL) GLAUCOMA  
(LA) LABORATORY  
(LS) LACRIMAL SYSTEM  
(LV) LOW VISION  
(NO) NEURO-OPHTHALMOLOGY  
(OR) ORBIT  
(PL) OCULAR PLASTIC SURGERY  
(PH) PHARMACOLOGY  
(RE) RETINA AND VITREOUS  
(RS) REFRACTIVE SURGERY  
(RX) REFRACTION-CONTACT LENSES  
(ST) STRABISMUS  
(TR) TRAUMA  
(TU) TUMORS AND PATHOLOGY  
(UV) UVEITIS  
(US) OCULAR ULTRASOUND

Deadline: 10/2019

### FORMAT:

#### Abstract should contain:

Title  
Author  
Co-authors (maximum 6)  
Purpose  
Methods  
Results  
Conclusion  
Keywords

Poster guidelines:  
**90cm x 120cm**

### FIRST (PRESENTING) AUTHOR (REQUIRED):

**Name:** Marilia Cirillo Rollo - R3  
**e-mail:** mari\_cirillo@hotmail.com  
**CEP Number:** 0

### 5. ABSTRACT (REQUIRED):

**Title: Evaluation of the lacrimal puncta morphology in patients using topical antiglaucoma medications.**

**Author and Co-authors:** Marília Cirillo Rollo, Luiz Alberto Soares de Melo Jr, Marco Antonio de Campos Machado, Norma Allemann

**Purpose:** To evaluate the morphology of the lacrimal puncta in patients using topical antiglaucoma medications.

**Methods:** In a cross-sectional controlled study, the lower lacrimal puncta of patients using antiglaucoma drops for longer than 6 months and no previous ocular surgery (case group) were analyzed and compared to patients that did not have any ocular disease (control group). The diameter and depth of the lower lacrimal puncta were evaluated using the anterior segment mode of the DRI-OCT Triton, Topcon.

**Results:** Thirty eyes of 19 patients using antiglaucoma drops were evaluated and compared to 30 eyes of 15 patients with no ocular disease or use of topical medication. The mean diameter in the case group was  $263 \pm 148\mu\text{m}$  and mean depth was  $368 \pm 191\mu\text{m}$ . In the control group the mean diameter was  $219 \pm 104\mu\text{m}$  and mean depth was  $640 \pm 190\mu\text{m}$ .

**Conclusion:** It was possible to observe that the values of the lacrimal puncta depth were lower in those patients that were under treatment with topical antiglaucoma medications.

**Keywords:** antiglaucoma medications, lacrimal puncta

## 2019 Research Days Abstract Form

### 2. SCIENTIFIC SECTION PREFERENCE (REQUIRED):

Review the Scientific Section Descriptions. Select and enter the two-letter Code for the one (1) Section best suited to review your abstract.

**(PL) OCULOPLASTICS SURGERY**

### 3. PRESENTATION PREFERENCE (REQUIRED)

Check one:

**(PL) OCULOPLASTICS SURGERY**

4. The signature of the First (Presenting) Author (REQUIRED) acting as the authorized agent for all authors, hereby certifies that any research reported was conducted in compliance with the Declaration of Helsinki and the "UNIFESP Ethical Committee"

### Scientific Section Descriptions (two-letter code):

(BE) OCULAR BIOENGINEERING  
(CO) CORNEA AND EXTERNAL DISEASE  
(CA) CATARACT  
(EF) ELECTROPHYSIOLOGY  
(EP) EPIDEMIOLOGY  
(EX) EXPERIMENTAL SURGERY  
(GL) GLAUCOMA  
(LA) LABORATORY  
(LS) LACRIMAL SYSTEM  
(LV) LOW VISION  
(NO) NEURO-OPHTHALMOLOGY  
(OR) ORBIT  
(PL) OCULAR PLASTIC SURGERY  
(PH) PHARMACOLOGY  
(RE) RETINA AND VITREOUS  
(RS) REFRACTIVE SURGERY  
(RX) REFRACTION-CONTACT LENSES  
(ST) STRABISMUS  
(TR) TRAUMA  
(TU) TUMORS AND PATHOLOGY  
(UV) UVEITIS  
(US) OCULAR ULTRASOUND

Deadline: 10/2019

### FORMAT:

#### Abstract should contain:

Title  
Author  
Co-authors (maximum 6)  
Purpose  
Methods  
Results  
Conclusion  
Keywords

Poster guidelines:  
**90cm x 120cm**

### FIRST (PRESENTING) AUTHOR (REQUIRED):

**Name:** Irineu Kenji Ogoshi Junior - R3  
**e-mail:** ken\_ogoshi@hotmail.com  
**CEP Number:** 0534/2018

### 5. ABSTRACT (REQUIRED):

**Title: Evaluation of spontaneous blinking dynamics in healthy subjects with smartphone camera.**

**Author and Co-authors:** Ogoshi Jr, IK, Osaki MH, Osaki TH

**Purpose:** To report an analysis of spontaneous blinking dynamics using Smartphone camera records (240fps) in a 2-dimensional videographic evaluation.

**Methods:** Blinking dynamics was recorded using a smartphone camera recording at 240frames per second in 720p. Volunteers were positioned at the chin rest of the slit lamp equipment for head stabilization. The smartphone was mounted on a specially designed support at the same plane of the highest point on the upper margin of the opening of each external auditory canal and the low point on the lower margin of the orbit (Frankfort plane), 0,5m away from the subjects. A nature-based movie with classic music was used to maintain attention while the video was recorded for a total of 3 minutes. The first minute was discarded while the last two minutes were used for the analysis. Exclusion criteria included: refractive surgery, ocular surface surgeries or diseases, eyelid procedures or alterations, strabismus, contact lenses use for the last 72 hours, pregnancy. Outcome measures were spontaneous interblink interval, blink rate in blinks per minute and blink velocity.

**Results:** Thirty subjects were analyzed, 6 men and 24 women. Average age was 45,2 years old (range 23-65). Mean blink closure velocity was 73.09mm/seconds (SD: 25.73, range 50-136). Mean interblink interval found was 6.04 seconds (SD: 3.64, range 2.02-16.89). Mean blink rate was 13.34 blinks per minute (SD: 7.27 range 3.0-27.5).

**Conclusion:** These values were compatible with previous studies that analyzed spontaneous blinking and suggest that smartphones could be used as useful tools to assess blinking dynamics evaluation in ocular disorders, such as ocular surface diseases (i.e dry eye), lagophthalmos, neuromuscular diseases (i.e Myasthenia Gravis).

**Keywords:** Spontaneous Blinking, Oculoplastics, Blinking Dynamics, Eyelashes, Eyelids

## 2019 Research Days Abstract Form

### 2. SCIENTIFIC SECTION PREFERENCE (REQUIRED):

Review the Scientific Section Descriptions. Select and enter the two-letter Code for the one (1) Section best suited to review your abstract.

**(OR) ORBIT**

### 3. PRESENTATION PREFERENCE (REQUIRED)

Check one:

**(OR) ORBIT**

4. The signature of the First (Presenting) Author (REQUIRED) acting as the authorized agent for all authors, hereby certifies that any research reported was conducted in compliance with the Declaration of Helsinki and the "UNIFESP Ethical Committee"

### Scientific Section Descriptions (two-letter code):

(BE) OCULAR BIOENGINEERING  
(CO) CORNEA AND EXTERNAL DISEASE  
(CA) CATARACT  
(EF) ELECTROPHYSIOLOGY  
(EP) EPIDEMIOLOGY  
(EX) EXPERIMENTAL SURGERY  
(GL) GLAUCOMA  
(LA) LABORATORY  
(LS) LACRIMAL SYSTEM  
(LV) LOW VISION  
(NO) NEURO-OPHTHALMOLOGY  
(OR) ORBIT  
(PL) OCULAR PLASTIC SURGERY  
(PH) PHARMACOLOGY  
(RE) RETINA AND VITREOUS  
(RS) REFRACTIVE SURGERY  
(RX) REFRACTION-CONTACT LENSES  
(ST) STRABISMUS  
(TR) TRAUMA  
(TU) TUMORS AND PATHOLOGY  
(UV) UVEITIS  
(US) OCULAR ULTRASOUND

Deadline: 10/2019

### FORMAT:

#### Abstract should contain:

Title  
Author  
Co-authors (maximum 6)  
Purpose  
Methods  
Results  
Conclusion  
Keywords

Poster guidelines:  
**90cm x 120cm**

### FIRST (PRESENTING) AUTHOR (REQUIRED):

**Name:** Felipe Ostermann Magalhães - R1  
**e-mail:** felipeom7@gmail.com  
**CEP Number:** 4025013

### 5. ABSTRACT (REQUIRED):

**Title: Orbital metastasis as the initial presentation of pancreatic carcinoma: A case report.**

**Author and Co-authors:** Felipe Ostermann Magalhães, Zaira Fernanda Martinho Nicolau, Marina Lourenço de Conti: Paulo Góis Manso.

**Purpose:** To describe a case of metastasis to the orbit from pancreatic adenocarcinoma.  
**Methods:** Observational case report.

**Results:** A 65-year-old woman presented with a 1-month history of low visual acuity and proptosis in the left eye. The patient also complained of recurrent headaches. During her admission, she had visual acuity of 20/32 OS, left proptosis and limitation of adduction and abduction in the left eye. Computer Tomography revealed a left orbital lesion. Three months later, the patient presented with jaundice and unintentional weight loss. Physical examination revealed a palpable abdominal mass and scleral icterus. The abdominal CT showed multiple liver lesions and a pancreatic mass. Biopsy of the left orbital mass was performed through a lateral orbitotomy. Histopathological examination confirmed a metastatic adenocarcinoma. The patient died 5 months after the initial presentation

**Conclusion:** Orbital metastasis from a primary pancreatic adenocarcinoma is rare. However, if the orbit is the site of the initial manifestation of the tumor, the ophthalmologist may be the first specialist to see the patient.

**Keywords:** Neoplasm metastasis; Orbital neoplasms/secondary; Carcinoma, pancreatic.

## 2019 Research Days Abstract Form

### 2. SCIENTIFIC SECTION PREFERENCE (REQUIRED):

Review the Scientific Section Descriptions. Select and enter the two-letter Code for the one (1) Section best suited to review your abstract.

**(OR) ORBIT**

### 3. PRESENTATION PREFERENCE (REQUIRED)

Check one:

**(OR) ORBIT**

4. The signature of the First (Presenting) Author (REQUIRED) acting as the authorized agent for all authors, hereby certifies that any research reported was conducted in compliance with the Declaration of Helsinki and the "UNIFESP Ethical Committee"

### Scientific Section Descriptions (two-letter code):

(BE) OCULAR BIOENGINEERING  
(CO) CORNEA AND EXTERNAL DISEASE  
(CA) CATARACT  
(EF) ELECTROPHYSIOLOGY  
(EP) EPIDEMIOLOGY  
(EX) EXPERIMENTAL SURGERY  
(GL) GLAUCOMA  
(LA) LABORATORY  
(LS) LACRIMAL SYSTEM  
(LV) LOW VISION  
(NO) NEURO-OPHTHALMOLOGY  
(OR) ORBIT  
(PL) OCULAR PLASTIC SURGERY  
(PH) PHARMACOLOGY  
(RE) RETINA AND VITREOUS  
(RS) REFRACTIVE SURGERY  
(RX) REFRACTION-CONTACT LENSES  
(ST) STRABISMUS  
(TR) TRAUMA  
(TU) TUMORS AND PATHOLOGY  
(UV) UVEITIS  
(US) OCULAR ULTRASOUND

Deadline: 10/2019

### FORMAT:

#### Abstract should contain:

Title  
Author  
Co-authors (maximum 6)  
Purpose  
Methods  
Results,  
Conclusion  
Keywords

Poster guidelines:  
**90cm x 120cm**

### FIRST (PRESENTING) AUTHOR (REQUIRED):

**Name:** Júlia Jiquilin Carvalho - R1  
**e-mail:** juliajcarvalho@hotmail.com  
**CEP Number:** 1523 2019

### 5. ABSTRACT (REQUIRED):

#### **Title: Superior ophtalmic vein thrombosis - a case report**

**Author and Co-authors:** Julia Jiquilin Carvalho, Luiz Fernando Teixeira, Paulo Gois Manso

**Purpose:** The report objective is to bring the discussion about the superior ophthalmic vein thrombosis considering the importance of early diagnosis and appropriate treatment due to its life-threatening potential and aiming to avoid severe complications, such as thrombosis of cavernous sinus.

**Methods:** It was made a review of the patient's files during the hospitalization period and follow up. All the images were also presented and discussed in this case.

**Results:** The symptoms and image findings improved after a few days of treatment, the patient remained with no visual impairment.

**Conclusion:** Appropriate treatment and diagnosis may lead to a great response in superior ophthalmic vein thrombosis.

**Keywords:** Superior ophtalmic vein thrombosis - orbit

## 2019 Research Days Abstract Form

### 2. SCIENTIFIC SECTION PREFERENCE (REQUIRED):

Review the Scientific Section Descriptions. Select and enter the two-letter Code for the one (1) Section best suited to review your abstract.

**(NO) NEURO-OPHTHALMOLOGY**

### 3. PRESENTATION PREFERENCE (REQUIRED)

Check one:

**(NO) NEURO-OPHTHALMOLOGY**

4. The signature of the First (Presenting) Author (REQUIRED) acting as the authorized agent for all authors, hereby certifies that any research reported was conducted in compliance with the Declaration of Helsinki and the "UNIFESP Ethical Committee"

### Scientific Section Descriptions (two-letter code):

(BE) OCULAR BIOENGINEERING  
(CO) CORNEA AND EXTERNAL DISEASE  
(CA) CATARACT  
(EF) ELECTROPHYSIOLOGY  
(EP) EPIDEMIOLOGY  
(EX) EXPERIMENTAL SURGERY  
(GL) GLAUCOMA  
(LA) LABORATORY  
(LS) LACRIMAL SYSTEM  
(LV) LOW VISION  
(NO) NEURO-OPHTHALMOLOGY  
(OR) ORBIT  
(PL) OCULAR PLASTIC SURGERY  
(PH) PHARMACOLOGY  
(RE) RETINA AND VITREOUS  
(RS) REFRACTIVE SURGERY  
(RX) REFRACTION-CONTACT LENSES  
(ST) STRABISMUS  
(TR) TRAUMA  
(TU) TUMORS AND PATHOLOGY  
(UV) UVEITIS  
(US) OCULAR ULTRASOUND

Deadline: 10/2019

### FORMAT:

#### Abstract should contain:

Title  
Author  
Co-authors (maximum 6)  
Purpose  
Methods  
Results  
Conclusion  
Keywords

Poster guidelines:  
**90cm x 120cm**

### FIRST (PRESENTING) AUTHOR (REQUIRED):

**Name:** Guilherme Havir Bufarah - R1  
**e-mail:** gui.bufarah15@gmail.com  
**CEP Number:** 5746/2019

### 5. ABSTRACT (REQUIRED):

**Title: Fourth cranial nerve palsy and internuclear ophthalmoplegia as an early presentation of multiple sclerosis ? A case report**

**Author and Co-authors:** BUFARAH, GUILHERME H, SILVA, LETÍCIA SANT'ANA CARDOSO

**Purpose:** To report a case of fourth cranial nerve palsy and internuclear ophthalmoplegia as an early presentation of multiple sclerosis.

**Methods:** A case of fourth cranial nerve palsy and internuclear ophthalmoplegia was investigated and confirmed as an early presentation of multiple sclerosis.

**Results:** A 20-year old male patient was admitted to the Emergency Room (ER) of Neurology at Hospital São Paulo in July 2019, complaining of sudden ocular deviation, horizontal and vertical binocular diplopia, associated with dizziness and left eye pain. He then was referred to the neuro-ophthalmology department, where other diagnostic hypothesis were excluded and the hypothesis of right fourth cranial nerve palsy associated with left internuclear ophthalmoplegia due to left midbrain demyelination prevailed.

**Conclusion:** Patient is currently two months from the onset of symptoms, he has partial improvement of his complaints and awaits consultation at the clinic for demyelinating diseases.

**Keywords:** Internuclear ophthalmoplegia; Fourth cranial nerve palsy; Multiple sclerosis



e-mails

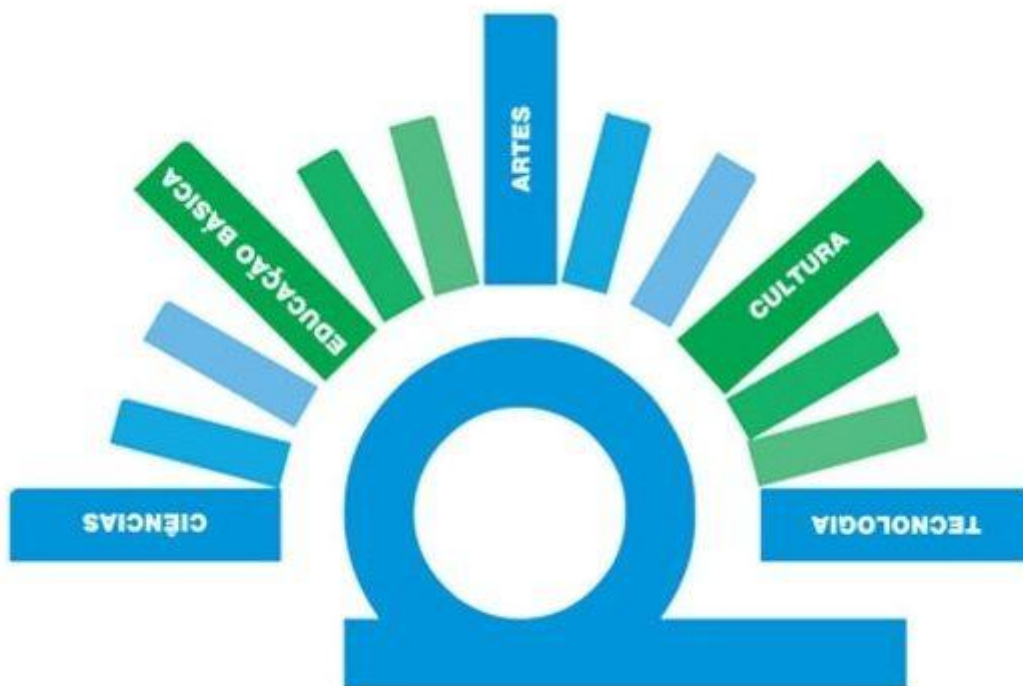
Adriana Berezovsky	<a href="mailto:aberezovsky@unifesp.br">aberezovsky@unifesp.br</a>	Júlia Gomes F. Polido Cabral	<a href="mailto:juliapolido@yahoo.com.br">juliapolido@yahoo.com.br</a>
Albert Wilson S. Machado Silva	<a href="mailto:albertwsms@yahoo.com.br">albertwsms@yahoo.com.br</a>	Julia Harumi Iwakura	<a href="mailto:julia.harumi.i@gmail.com">julia.harumi.i@gmail.com</a>
Alex Treiger Grupenmacher	<a href="mailto:alexgrups@gmail.com">alexgrups@gmail.com</a>	Júlia Jiquilin Carvalho	<a href="mailto:juliajcarvalho@hotmail.com">juliajcarvalho@hotmail.com</a>
Alexandre Xavier Da Costa	<a href="mailto:dr.alexandre.x@gmail.com">dr.alexandre.x@gmail.com</a>	Juliana Maria Ferraz Sallum	<a href="mailto:juliana@pobox.com">juliana@pobox.com</a>
Aline Couto Carneiro	<a href="mailto:alinecouto.epm@gmail.com">alinecouto.epm@gmail.com</a>	Lauro Augusto de Oliveira	<a href="mailto:laopadilha@gmail.com">laopadilha@gmail.com</a>
Aline Lutz De Araujo	<a href="mailto:alinelutz.a@gmail.com">alinelutz.a@gmail.com</a>	Lucas Denadai	<a href="mailto:lucasdenadai89@hotmail.com">lucasdenadai89@hotmail.com</a>
Allexya Affonso Antunes Marcos	<a href="mailto:allexya.affonso@gmail.com">allexya.affonso@gmail.com</a>	Lucas Zago Ribeiro	<a href="mailto:lucaszagoribeiro@gmail.com">lucaszagoribeiro@gmail.com</a>
Allyne Mota Kalaf	<a href="mailto:allykalaf@gmail.com">allykalaf@gmail.com</a>	Luciana Lopes Rocha	<a href="mailto:luciana_lr@yahoo.com.br">luciana_lr@yahoo.com.br</a>
Aluisio Rosa Gameiro Filho	<a href="mailto:agameirofilho@yahoo.com.br">agameirofilho@yahoo.com.br</a>	Luciene Barbosa de Souza	<a href="mailto:lucieneb@uol.com.br">lucieneb@uol.com.br</a>
Ana Carolina Yumi Itikawa	<a href="mailto:anaitikawa@yahoo.com">anaitikawa@yahoo.com</a>	Luis Filipe Nakayama	<a href="mailto:nakayama.luis@gmail.com">nakayama.luis@gmail.com</a>
Ana Luisa Hofling de Lima	<a href="mailto:coftalmo@uol.com.br">coftalmo@uol.com.br</a>	Luiz Filipe Adami Lucatto	<a href="mailto:filipeadami@yahoo.com.br">filipeadami@yahoo.com.br</a>
Ana Marisa Pires Castello Branco	<a href="mailto:anamarisapcb@hotmail.com">anamarisapcb@hotmail.com</a>	Marcella Q. Salomão Hoyer	<a href="mailto:marcella@barravisioncenter.com">marcella@barravisioncenter.com</a>
Aristófanés M. Canamary Júnior	<a href="mailto:aristofanesjunior@gmail.com">aristofanesjunior@gmail.com</a>	Marcos Pereira Vianello	<a href="mailto:marcospvianello@yahoo.com.br">marcospvianello@yahoo.com.br</a>
Armando Coelho Brito	<a href="mailto:armandocbrito@gmail.com">armandocbrito@gmail.com</a>	Maria Carolina Marquezan	<a href="mailto:mcmarquezan@gmail.com">mcmarquezan@gmail.com</a>
Augusto Alves Pinho Vieira	<a href="mailto:augustovieira.med@gmail.com">augustovieira.med@gmail.com</a>	Mariana Antunes Davi	<a href="mailto:ma.antunes.d@hotmail.com">ma.antunes.d@hotmail.com</a>
Augusto Paranhos Jr.	<a href="mailto:augusto.paranhos@uol.com.br">augusto.paranhos@uol.com.br</a>	Mariana Batista Gonçalves	<a href="mailto:mari-batista@bol.com.br">mari-batista@bol.com.br</a>
Beatriz Nugent da Cunha	<a href="mailto:beatriznug@gmail.com">beatriznug@gmail.com</a>	Mariana B. Barcellos Dias	<a href="mailto:marianabbd@gmail.com">marianabbd@gmail.com</a>
Brunella Pavan Taffner	<a href="mailto:brunellapavan@hotmail.com">brunellapavan@hotmail.com</a>	Mariana Chiba Ikeda	<a href="mailto:marianachibaikeda@gaill.com">marianachibaikeda@gaill.com</a>
Bruno De Paula Freitas	<a href="mailto:brunodepaulafreitas@hotmail.co">brunodepaulafreitas@hotmail.co</a>	Mariana Kawamuro	<a href="mailto:mkawamuro@gmail.com">mkawamuro@gmail.com</a>
Bruno Leonardo B. Esporcatte	<a href="mailto:bruno_espocatte@yahoo.com.br">bruno_espocatte@yahoo.com.br</a>	Mariana Matioli Da Palma	<a href="mailto:marimatioli@yahoo.com.br">marimatioli@yahoo.com.br</a>
Bruno Mauricio R. de Oliveira	<a href="mailto:brunomro@gmail.com">brunomro@gmail.com</a>	Marilcia Cirillo Rollo	<a href="mailto:mari_cirillo@hotmail.com">mari_cirillo@hotmail.com</a>
Bruno Queiroz Alves	<a href="mailto:bruno.q.a@gmail.com">bruno.q.a@gmail.com</a>	Marina Roizenblatt	<a href="mailto:maroizenb@gmail.com">maroizenb@gmail.com</a>
Caio Vinicius Sato Regatieri	<a href="mailto:caiore@gmail.com">caiore@gmail.com</a>	Marisa Lúcia Romani Paraboni	<a href="mailto:marisar@uri.com.br">marisar@uri.com.br</a>
Camila Kase	<a href="mailto:camila.kase@gmail.com">camila.kase@gmail.com</a>	Maurício Maia	<a href="mailto:retina@femanet.com.br">retina@femanet.com.br</a>
Camila Maria Valente	<a href="mailto:cami_valente@hotmail.com">cami_valente@hotmail.com</a>	Mauro S de Queiroz Campos	<a href="mailto:mscampos@uol.com.br">mscampos@uol.com.br</a>
Camila Palmeira Griz	<a href="mailto:camilapalmeira@hotmail.com">camilapalmeira@hotmail.com</a>	Michel Eid Farah	<a href="mailto:mefarah@uol.com.br">mefarah@uol.com.br</a>
Carlos Eduardo de Souza	<a href="mailto:edusouzaa@gmail.com">edusouzaa@gmail.com</a>	Michelle Farah Santinello	<a href="mailto:milfarah@gmail.com">milfarah@gmail.com</a>
Cristina Cagliari	<a href="mailto:cagliari.c@gmail.com">cagliari.c@gmail.com</a>	Midori Hentona Osaki	<a href="mailto:midori_osaki@yahoo.com.br">midori_osaki@yahoo.com.br</a>
Cristina Muccioli	<a href="mailto:cmucciol@uol.com.br">cmucciol@uol.com.br</a>	Miguel Noel Nascentes Burnier	<a href="mailto:miguel.burnier@mcgill.ca">miguel.burnier@mcgill.ca</a>
Cristina Yabumoto	<a href="mailto:crisyabumoto@yahoo.com.br">crisyabumoto@yahoo.com.br</a>	Murilo Bertazzo Peres	<a href="mailto:murilobp@gmail.com">murilobp@gmail.com</a>
Daniela Calucci dos Santos	<a href="mailto:danielacalucci@hotmail.com">danielacalucci@hotmail.com</a>	Murilo Ubukata Polizelli	<a href="mailto:murilopolizelli@gmail.com">murilopolizelli@gmail.com</a>
Dante Akira Kondo Kuroiwa	<a href="mailto:akira.epm78@gmail.com">akira.epm78@gmail.com</a>	Natasha F Santos da Cruz	<a href="mailto:natasha_cruz27@hotmail.com">natasha_cruz27@hotmail.com</a>
Denise de Freitas	<a href="mailto:dfreitas@uol.com.br">dfreitas@uol.com.br</a>	Nelson Chamma Capelanes	<a href="mailto:nelsonchamma@me.com">nelsonchamma@me.com</a>
Diego Lisboa Araujo	<a href="mailto:diego_lisboa10@hotmail.com">diego_lisboa10@hotmail.com</a>	Nikoly Tigani Fares	<a href="mailto:nik.fares@yahoo.com.br">nik.fares@yahoo.com.br</a>
Diego Torres Dias	<a href="mailto:diego.torres@outlook.com.br">diego.torres@outlook.com.br</a>	Norma Allemann	<a href="mailto:norma.allemann@pobox.com">norma.allemann@pobox.com</a>
Eduardo Buchelle Rodrigues	<a href="mailto:edubrodrigues@yahoo.com.br">edubrodrigues@yahoo.com.br</a>	Oswaldo F M Brasil do Amaral	<a href="mailto:dicoretina@gmail.com">dicoretina@gmail.com</a>
Elmar Torres Neto	<a href="mailto:elmaroft@hotmail.com">elmaroft@hotmail.com</a>	Pablo Felipe Rodrigues	<a href="mailto:drpablo.rodrigues@gmail.com">drpablo.rodrigues@gmail.com</a>
Fábio Bernardi Daga	<a href="mailto:fabiobernardidaga@gmail.com">fabiobernardidaga@gmail.com</a>	Paulo Alberto Cervi Rosa	<a href="mailto:paulopacr@hotmail.com">paulopacr@hotmail.com</a>
Fábio Kenji Matsumoto	<a href="mailto:fabiokenji75@gmail.com">fabiokenji75@gmail.com</a>	Paulo Schor	<a href="mailto:pschor@pobox.com">pschor@pobox.com</a>
Fábio Mendonça Xavier Andrade	<a href="mailto:fabio16.xavier@gmail.com">fabio16.xavier@gmail.com</a>	Ramon Antunes De Oliveira	<a href="mailto:ramonntt@gmail.com">ramonntt@gmail.com</a>
Felipe Ferreira Conti	<a href="mailto:contiffelipe@gmail.com">contiffelipe@gmail.com</a>	Raysa V de Oliveira Cechim	<a href="mailto:ray_cechim@hotmail.com">ray_cechim@hotmail.com</a>
Felipe Ostermann Magalhães	<a href="mailto:felipeom7@gmail.com">felipeom7@gmail.com</a>	Renata Macedo Nabuco Faro	<a href="mailto:renatamnfar@gmail.com">renatamnfar@gmail.com</a>
Felipe Picanço Muralha	<a href="mailto:felipe_muralha@hotmail.com">felipe_muralha@hotmail.com</a>	Renata Tieme Kato Kunitake	<a href="mailto:tiekat@gmail.com">tiekat@gmail.com</a>
Fernanda Machado Bezerra	<a href="mailto:fernandamb1901@gmail.com">fernandamb1901@gmail.com</a>	Renato Ambrosio	<a href="mailto:renatoambrosiojr@terra.com.br">renatoambrosiojr@terra.com.br</a>
Francisco Bandeira e Silva	<a href="mailto:franciscobandeira@me.com">franciscobandeira@me.com</a>	Renato Menezes Palácio	<a href="mailto:renatopalacios@hotmail.com">renatopalacios@hotmail.com</a>
Franklin Kuraoka Oda	<a href="mailto:oda.epm@gmail.com">oda.epm@gmail.com</a>	Ricardo Salles Cauduro	<a href="mailto:cauduro.ricardo@gmail.com">cauduro.ricardo@gmail.com</a>

Gabriel Ferrante Abou Murad	<a href="mailto:murad.gabriel@gmail.com">murad.gabriel@gmail.com</a>	Rodolfo Peres Nunes	<a href="mailto:rodolfonunesdr@outlook.com">rodolfonunesdr@outlook.com</a>
Gabriel Izan Santos Botelho	<a href="mailto:gabrielbotelho@hotmail.com">gabrielbotelho@hotmail.com</a>	Rubens Belfort Jr.	<a href="mailto:clinbelf@uol.com.br">clinbelf@uol.com.br</a>
Gabriela A. B Pereira Pelegrini	<a href="mailto:gabriela.oftalmo@hotmail.com">gabriela.oftalmo@hotmail.com</a>	Solange Rios Salomão	<a href="mailto:ssalomao@unifesp.br">ssalomao@unifesp.br</a>
Guilherme Eiichi Takitani	<a href="mailto:guilherme.eiichi@gmail.com">guilherme.eiichi@gmail.com</a>	Talita Trevizani Rocchetti	<a href="mailto:talita.rocchetti@gmail.com">talita.rocchetti@gmail.com</a>
Guilherme Havir Bufarah	<a href="mailto:gui.bufarah15@gmail.com">gui.bufarah15@gmail.com</a>	Tarciana De Souza Soares	<a href="mailto:ssarciana@yahoo.com.br">ssarciana@yahoo.com.br</a>
Gustavo Albrecht Samico	<a href="mailto:samico.gustavo@gmail.com">samico.gustavo@gmail.com</a>	Thiago Gonçalves S. Martins	<a href="mailto:thiagogsmartins@yahoo.com.br">thiagogsmartins@yahoo.com.br</a>
Gustavo Barreto de Melo	<a href="mailto:gustavobmelo@yahoo.com.br">gustavobmelo@yahoo.com.br</a>	Tiago dos Santos Prata	<a href="mailto:tprata0807@gmail.com">tprata0807@gmail.com</a>
Irineu Kenji Ogoshi Junior	<a href="mailto:ken_ogoshi@hotmail.com">ken_ogoshi@hotmail.com</a>	Vanessa Favero Demeda	<a href="mailto:vanessa.favero@gmail.com">vanessa.favero@gmail.com</a>
Ivan Maynard Tavares	<a href="mailto:im.tavares@uol.com.br">im.tavares@uol.com.br</a>	Victor Dias Bergamasco	<a href="mailto:vbergama@hotmail.com">vbergama@hotmail.com</a>
Izabela Negrão Frota De Almeida	<a href="mailto:almeidaizabela@gmail.com">almeidaizabela@gmail.com</a>	Victoria Sakamoto	<a href="mailto:victoria.ksakamoto@gmail.com">victoria.ksakamoto@gmail.com</a>
Jenifer Shen Ay Wu	<a href="mailto:jenifersawu@gmail.com">jenifersawu@gmail.com</a>	Vinicius Campos Bergamo	<a href="mailto:viniciusbergamo.epm@gmail.com">viniciusbergamo.epm@gmail.com</a>
Jorge H Cavalcante Tavares	<a href="mailto:jorgehenriquect@hotmail.com">jorgehenriquect@hotmail.com</a>	Vinicius Ferreira Kniggendorf	<a href="mailto:vinicius_kdorf@yahoo.com.br">vinicius_kdorf@yahoo.com.br</a>
Jorge Selem Haddad Neto	<a href="mailto:jshaddad2@hotmail.com">jshaddad2@hotmail.com</a>	Vivian Cristina Costa Afonso	<a href="mailto:vivian_cris@yahoo.com.br">vivian_cris@yahoo.com.br</a>
José Alvaro Pereira Gomes	<a href="mailto:japgomes@uol.com.br">japgomes@uol.com.br</a>	Wallace Chamon	<a href="mailto:visus@pobox.com">visus@pobox.com</a>
José Aparecido Job Neto	<a href="mailto:jjobneto@hotmail.com">jjobneto@hotmail.com</a>	Walton Nosé	<a href="mailto:waltonose@hotmail.com">waltonose@hotmail.com</a>
José Arthur Pinto Milhomens	<a href="mailto:milhomens.af@outlook.com">milhomens.af@outlook.com</a>	Wirley Alves Mendonça Junior	<a href="mailto:wirley04@hotmail.com">wirley04@hotmail.com</a>
Joyce Luciana Covre	<a href="mailto:joycecovre@gmail.com">joycecovre@gmail.com</a>	Zaira F Martinho Nicolau	<a href="mailto:zairanicolau@hotmail.com">zairanicolau@hotmail.com</a>

**FINANCIAL SUPPORT:**

PAEP Capes Processo Nº 88881.359197/2019-01

PROEX CAPES Processo Nº 23038.007125/2018-76



**Programa de Apoio a Eventos no País – PAEP  
CAPES**